



UNIVERSIDADE ESTADUAL DE CAMPINAS
SISTEMA DE BIBLIOTECAS DA UNICAMP
REPOSITÓRIO DA PRODUÇÃO CIENTÍFICA E INTELLECTUAL DA UNICAMP

Versão do arquivo anexado / Version of attached file:

Versão do Editor / Published Version

Mais informações no site da editora / Further information on publisher's website:

<https://www.ncbi.nlm.nih.gov/pmc/articles/PMC5342972/>

DOI: 10.5125/jkaoms.2017.43.1.42

Direitos autorais / Publisher's copyright statement:

©2017 by Korean Association of Oral and Maxillofacial Surgeons. All rights reserved.

DIRETORIA DE TRATAMENTO DA INFORMAÇÃO

Cidade Universitária Zeferino Vaz Barão Geraldo

CEP 13083-970 – Campinas SP

Fone: (19) 3521-6493

<http://www.repositorio.unicamp.br>



Chemosis as complication in transconjunctival approach for orbital trauma

Sergio Olate^{1,2}, Celso Palmieri Jr.³, Márcio de Moraes⁴

¹Department of Oral and Maxillofacial Surgery, Universidad de La Frontera,

²Center for Research in Biomedical Sciences, Universidad Autónoma de Chile, Temuco, Chile,

³Department of Oral and Maxillofacial Surgery, Louisiana State University, Shreveport, LA, USA,

⁴Department of Oral Diagnosis, State University of Campinas, Piracicaba, Brazil

Abstract (J Korean Assoc Oral Maxillofac Surg 2017;43:42-45)

The aim of this report was to discuss a complication resulting from a transconjunctival approach to treating an orbital fracture. A 30-year-old male patient presented with a fracture to the zygomatic orbital complex. He was treated with transconjunctival conventional surgical treatment. Two days after surgical treatment, the patient presented with secondary chemosis which was initially slight and then subsequently worsened. The clinical situation was managed with topical and systemic corticosteroids and resolved within one postoperative month. Two-year follow-up showed ptosis of the upper eyelid and limited infraversion in the affected eye. This unusual complication associated with an orbital trauma was resolved with minor functional alterations, although the consequences observed after 2 years were not completely satisfactory.

Key words: Orbital fracture, Complications, Orbital approach

[paper submitted 2016. 2. 13 / revised 2016. 3. 12 / accepted 2016. 3. 26]

I. Introduction

A transconjunctival approach has been used frequently to treat fractures of the infraorbital rim and orbital floor¹, as well as other types of cosmetic and pathological situations. Advantages to this approach are easy approach to the bone, rapid closure once the procedure is complete and favorable aesthetic results including minimal skin scarring².

Some complications have been associated with this approach showing it is a complex procedure. Baumann and Ewers³ reported 2% complications and Malhotra et al.⁴ reported 10% complications at 2-year follow-up. This case report presents an important complication of the transconjunctival approach to treating an orbital fracture.

Sergio Olate

Department of Oral and Maxillofacial Surgery, Universidad de La Frontera,
Claro Solar 115, 4to Piso, Oficina 20, Temuco 4780000, Chile

TEL: +56-45-2400968 FAX: +56-45-2325000

E-mail: sergio.olate@ufrontera.cl

ORCID: <http://orcid.org/0000-0001-8153-0676>

© This is an open-access article distributed under the terms of the Creative Commons Attribution Non-Commercial License (<http://creativecommons.org/licenses/by-nc/4.0/>), which permits unrestricted non-commercial use, distribution, and reproduction in any medium, provided the original work is properly cited.

Copyright © 2017 The Korean Association of Oral and Maxillofacial Surgeons. All rights reserved.

II. Case Report

A 30-year-old male patient was admitted to the Hospital at Temuco, Chile, due to a high-energy trauma caused by a fall from a height of 4 m. During admission the patient's condition was assessed and a fracture of the left orbital complex was diagnosed, in addition to fractures of the orbital rim and floor, orbital sidewall, zygomaticomaxillary pillar and ipsilateral zygomatic arch. (Fig. 1) The patient was in intensive care for one week, at which point it was possible to provide surgical treatment. No medical history was present, including diabetes, Metabolic or facial syndromes or nutritional conditions and no smoking was reported.

The immediate preoperative stage showed severe left periorbital edema, ophthalmoplegia and diplopia in different fields. The surgical procedure was executed by a maxillofacial surgeon with 6 years experience in facial trauma; an upper approach was made for the left supraorbital rim, a left intraoral approach and a transconjunctival approach with lateral canthotomy. The procedure was performed conventionally and routinely, without complications. According to the proposed technique, internal rigid fixation was used with 1.5 plates, and no problem in screw insertion was present; at some stage during surgery, a forced retraction of the conjunc-

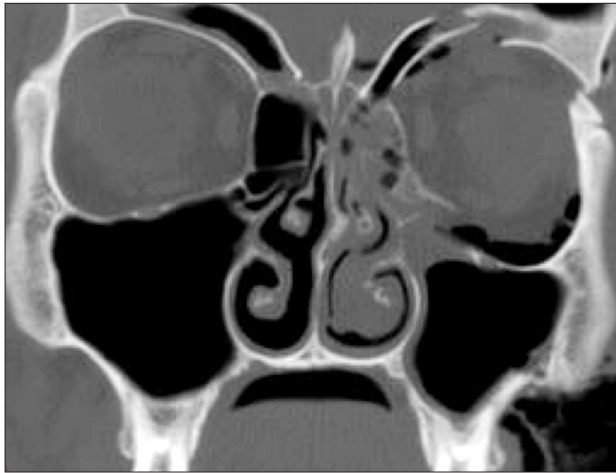

Fig. 1. Preoperative computed tomography showing an orbital fracture with compromised orbital rim and floor.

Sergio Olate et al: Chemosis as complication in transconjunctival approach for orbital trauma. J Korean Assoc Oral Maxillofac Surg 2017

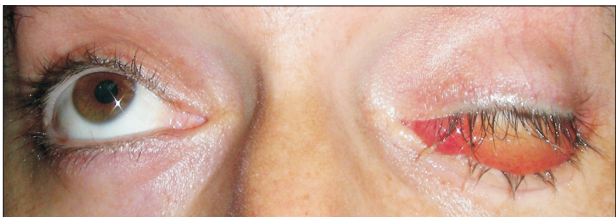

Fig. 2. Chemosis of the left orbit observed in supraversion accompanied by ptosis of the upper left eyelid.

Sergio Olate et al: Chemosis as complication in transconjunctival approach for orbital trauma. J Korean Assoc Oral Maxillofac Surg 2017

tival flap was undertaken. The final suture to the conjunctiva was made using two stitches with a reverse knot and a 5-0 absorbable suture.

In the initial postoperative days, increased sclera exposure was observed, with no symptoms of pain or signs of enophthalmos or dystopia. On the fourth postoperative day an acute low-level conjunctivitis associated with chemosis and a 3 mm palpebral conjunctiva exposure was seen. (Fig. 2) The patient was discharged 1 week after surgery and during the hospital stay was kept on a course of endovenous corticoids (12 mg intravenous [IV] per day for 3 days, 24 mg IV per day during the last 4 days; Fresenius Kabi AG, Bad Homburg, Germany).

At the first out-patient check-up 10 days after the surgery, the patient presented with severe chemosis of the left eye with 5 mm of exposure (Fig. 3), slight ophthalmoplegia and ptosis of the upper eyelid, with no signs of pain or visual alterations. Ciprofloxacin ophthalmic solution with corticosteroids (drops, 2.5 mL per day; S.M.B. Farma, Santiago, Chile)

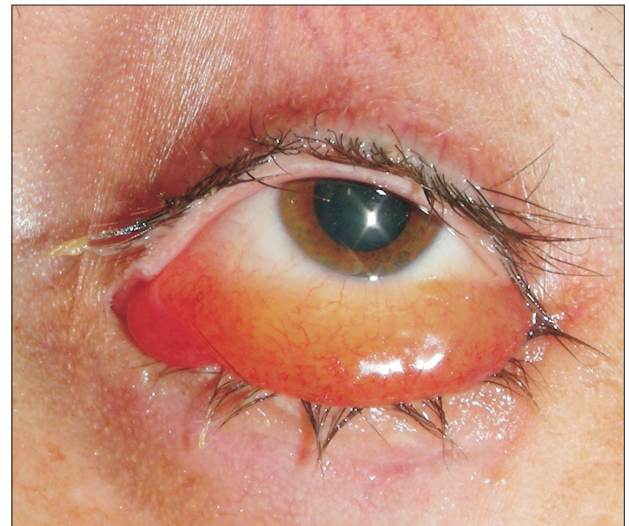

Fig. 3. During forced movement of the upper eyelid, an extensive chemosis subsequent to the transconjunctival approach is observed in the left orbit.

Sergio Olate et al: Chemosis as complication in transconjunctival approach for orbital trauma. J Korean Assoc Oral Maxillofac Surg 2017

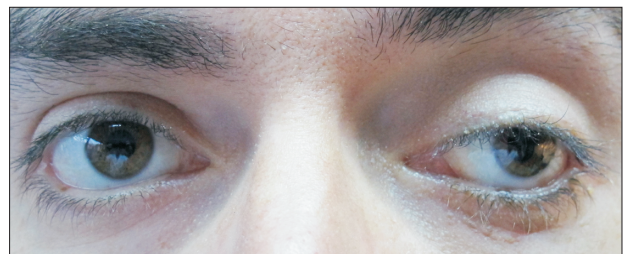

Fig. 4. Condition after 1 month where total recovery from the chemosis can be seen.

Sergio Olate et al: Chemosis as complication in transconjunctival approach for orbital trauma. J Korean Assoc Oral Maxillofac Surg 2017

was introduced as well as an eye patch to avoid major complications associated with lack of lubrication. Physiotherapy was also prescribed to improve mobility of the upper eyelid. The ophthalmologist's assessment reported positive visual acuity in all fields with functional impotence in the infraversion.

The condition evolved in a limited fashion over the following 8 days (18 days after surgery), at which point the chemosis began to subside. One month after the surgery (Fig. 4) the patient showed symptom resolution, with resolved chemosis and associated conjunctivitis, but persistence of post-traumatic strabismus, which was subsequently solved with surgical treatment to manage the extrinsic muscles of the eye involved in the anomalous position of the eyeball. After two years of follow-up, the patient had an adequate recovery from the facial trauma with a slight ptosis of the upper left eyelid,

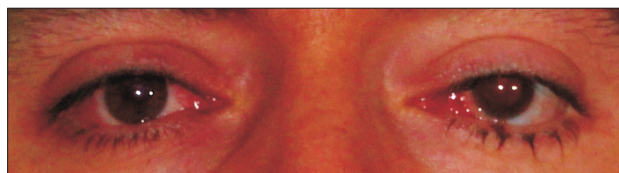


Fig. 5. Clinical condition after 2 years of follow-up, showing symmetry and absence of enophthalmos, dystopia or diplopia.
Sergio Olate et al: Chemosis as complication in transconjunctival approach for orbital trauma. J Korean Assoc Oral Maxillofac Surg 2017

limited infraversion and no signs of alterations in visual acuity.(Fig. 5, 6)

The written informed consent for the publication of the photographs was obtained from the patient.

III. Discussion

Treatment of orbital fractures and fractures of the zygomatic orbital complex has been linked to different conditions, where variables such as the patient's age and gender as well as the presence of other facial fractures are combined⁵. In a series by Manganello-Souza and Rodrigues de Freitas⁶ reporting on 40 patients treated with the transconjunctival approach, only five presented with related complications such as ectropion, corneal ulceration and ptosis of the lateral canthus. Another series with 56 patients reported only 4 patients with complications associated with entropion and trichiasis⁷. Baumann and Ewers' study³ of 99 patients reported 2% complications, describing a case with entropion and another case with tarsal laceration, which were both later resolved without major limitations. Malhotra et al.⁴ presented a series of 60 patients with 2 years of follow-up and 6 cases of complications, including chemosis. With a low incidence of complications and the advantages of the transconjunctival approach, the author's use of these techniques in 90% of the facial trauma and reconstruction cases resulted in no chemosis (almost 30 cases per year).

Chemosis does not appear among the usual complications of this approach. Causes for this complication may be related to extensive initial orbital edema which presented at the time of surgery, excessive traction in the conjunctival flap, inadequate dissection layer or lymphatic flow complications in the postoperative time. In this sense, chemosis defined as nonspecific swelling of the conjunctiva could be associated with bacterial or viral reactions, angioedema or trauma⁸. In cosmetic blepharoplasty techniques using the transconjunctival approach, these are frequent complications⁹, thus

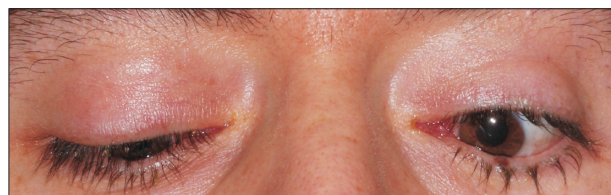


Fig. 6. Clinical condition after 2 years showing infraversion, demonstrating limitation in movement of the upper eyelid and limited downward movement of the eyeball. No alterations were observed in visual acuity, and no corneal ulcer or other types of alterations were seen.

Sergio Olate et al: Chemosis as complication in transconjunctival approach for orbital trauma. J Korean Assoc Oral Maxillofac Surg 2017

requiring establishment of protocols for their treatment. It is likely that the transconjunctival approach which is oriented to remove fat tissue produces better conditions for the development of chemosis and that the physiopathological mechanism will be similar to that observed in this case, since this is a rare complication in orbital traumatology. Other conditions such as carotid-cavernous fistula have also been responsible for proptosis, ophthalmoplegia and chemosis, indicating it is a response to the volume of fluids present in the orbit¹⁰.

Lymphatic flow is key for postoperative chemosis¹¹. For instance, retrograde flow could result in the lymphatic channel filling with blood¹² or may contribute to a rise in periocular or orbital pressure, resulting in venous engorgement and a back-flow of blood into the conjunctival lymphatic system¹³. On other hand, dilated arterioles increase the pressure gradient between arteriolar and venule capillaries and lead to the extravasation of intravascular fluid with resultant vasodilatory edema. In this case, the patient presented with a great deal of edema at admission, a non-controlled traction of the conjunctival flap and failure in drainage which could all be related to his chemosis.

A treatment protocol for this condition has been proposed based on topical and systemic corticosteroids. Oral steroids are an effective adjuvant treatment in younger patients¹⁴ and topical adrenaline could be an option¹⁵; surgical treatment that includes sutures has been used in other trauma cases¹⁶. The treatment strategies used in this case were in agreement with McCord et al.¹⁷ and Putterman¹⁸, and showed good results. Prevention of this complication can be achieved by respecting anatomical landmarks and gentle retraction of the orbital flap.

This case was resolved with minor functional alterations, although the consequences observed after 2 years (ptosis of the upper eyelid and limited infraversion) were not completely satisfactory, and may call into question the results obtained

by the treatment provided during initial presentation and the surgical treatment of the orbital fracture.

Conflict of Interest

No potential conflict of interest relevant to this article was reported.

ORCID

Sergio Olate, <http://orcid.org/0000-0001-8153-0676>

Celso Palmieri Jr., <http://orcid.org/0000-0002-4683-564X>

Márcio de Moraes, <http://orcid.org/0000-0002-5229-5723>

References

- Olate S, Lima SM Jr, Sawazaki R, Moreira RW, de Moraes M. Surgical approaches and fixation patterns in zygomatic complex fractures. *J Craniofac Surg* 2010;21:1213-7.
- Sailer HF. Osteosynthesis of orbital margin fractures via the transconjunctival approach using staples: a preliminary report. *J Maxillofac Surg* 1977;5:184-6.
- Baumann A, Ewers R. Use of the preseptal transconjunctival approach in orbit reconstruction surgery. *J Oral Maxillofac Surg* 2001;59:287-91.
- Malhotra R, Saleh GM, de Sousa JL, Sneddon K, Selva D. The transcaruncular approach to orbital fracture repair: ophthalmic sequelae. *J Craniofac Surg* 2007;18:420-6.
- Olate S, Lima SM Jr, Sawazaki R, Moreira RW, de Moraes M. Variables related to surgical and nonsurgical treatment of zygomatic complex fracture. *J Craniofac Surg* 2011;22:1200-2.
- Manganello-Souza LC, Rodrigues de Freitas R. Transconjunctival approach to zygomatic and orbital floor fractures. *Int J Oral Maxillofac Surg* 1997;26:31-4.
- Novelli G, Ferrari L, Sozzi D, Mazzoleni F, Bozzetti A. Transconjunctival approach in orbital traumatology: a review of 56 cases. *J Craniofac Surg* 2011;39:266-70.
- Minckler MR, Newell C, Drummond B. Chemosis from trauma. *West J Emerg Med* 2014;15:357-8.
- Prischmann J, Sufyan A, Ting JY, Ruffin C, Perkins SW. Dry eye symptoms and chemosis following blepharoplasty: a 10-year retrospective review of 892 cases in a single-surgeon series. *JAMA Facial Plast Surg* 2013;15:39-46.
- Mateos E, Arruabarrena C, Veiga C, Ruiz-Zarate B, Valdes JJ, Rojo P. Massive exophthalmos after traumatic carotid-cavernous fistula embolization. *Orbit* 2007;26:121-4.
- Makani H, Bangalore S, Romero J, Wever-Pinzon O, Messerli FH. Effect of renin-angiotensin system blockade on calcium channel blocker-associated peripheral edema. *Am J Med* 2011;124:128-35.
- Awdry P. Lymphangiectasia haemorrhagica conjunctivae. *Br J Ophthalmol* 1969;53:274-8.
- Kyprianou I, Nessim M, Kumar V, Chew C. A case of lymphangiectasia haemorrhagica conjunctivae following phacoemulsification. *Acta Ophthalmol Scand* 2004;82:627-8.
- Kim SY, Chung YK, Lee YC, Kim SY. Oral steroid therapy as an adjuvant treatment for severe epidemic keratoconjunctivitis in patients younger than 3 years. *Cornea* 2015;34:182-7.
- Shao EH, Liolios V, Lindfield D, McLean C. Topical adrenaline (1:1000) for the management of severe tarsal conjunctival chemosis. *Ophthalm Plast Reconstr Surg* 2015;31:e115-6.
- Krishnan R, Izadi S, Morton CE, Marsh IB. Use of Frost sutures in an orbital trauma patient with extensive conjunctival oedema and pseudoproptosis. *Int J Oral Maxillofac Surg* 2007;36:649-51.
- McCord CD, Kreymerman P, Nahai F, Walrath JD. Management of postblepharoplasty chemosis. *Aesthet Surg J* 2013;33:654-61.
- Putterman AM. Regarding comprehensive management of chemosis following cosmetic lower blepharoplasty. *Plast Reconstr Surg* 2009;124:313-4.