

UNIVERSIDADE ESTADUAL DE CAMPINAS  
SISTEMA DE BIBLIOTECAS DA UNICAMP  
REPOSITÓRIO DA PRODUÇÃO CIENTÍFICA E INTELLECTUAL DA UNICAMP

**Versão do arquivo anexado / Version of attached file:**

Versão do Editor / Published Version

**Mais informações no site da editora / Further information on publisher's website:**

<http://www.sciencedirect.com/science/article/pii/S0022522315007151>

**DOI: 10.1016/j.jtcvs.2015.05.024**

**Direitos autorais / Publisher's copyright statement:**

© by Elsevier. All rights reserved.

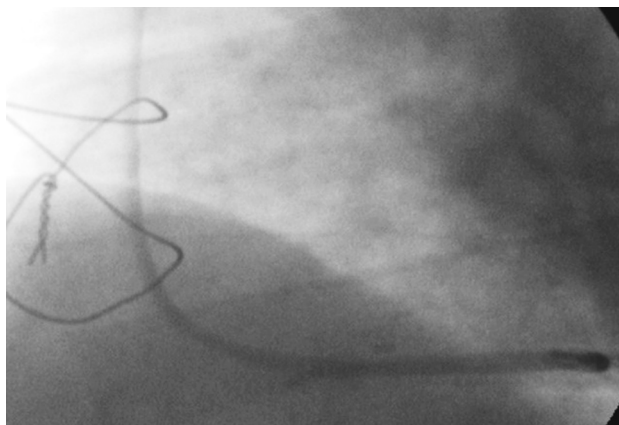
DIRETORIA DE TRATAMENTO DA INFORMAÇÃO

Cidade Universitária Zeferino Vaz Barão Geraldo

CEP 13083-970 – Campinas SP

Fone: (19) 3521-6493

<http://www.repositorio.unicamp.br>



**FIGURE 2.** Patent saphenous vein graft–right coronary artery after rivaroxaban treatment.

only a minority of these patients have development of clinically evident HIT.<sup>2</sup> Unfortunately, we had no access to washed-platelet functional assays, such as the carbon 14–labeled serotonin release assay; nevertheless, our patient had a high pretest probability for HIT (a score of 7 according to the 4Ts scoring system<sup>3</sup>), along with a positive antibody test result, and so we decided to initiate alternative nonheparin anticoagulation because delays in treatment are associated with an initial 5% to 10% daily risk of thrombosis, amputation, or death. Currently approved parenteral direct thrombin inhibitors were not available at that time in our institution, however, and we therefore resorted to using rivaroxaban in the management of our patient.

Rivaroxaban is an oral, direct factor X inhibitor that has shown efficacy in the treatment of venous and arterial thromboembolism. The key advantages of its use for the

treatment of HIT include ease of administration (fixed dose), absence of a need for laboratory monitoring, longer half-life and lower cost relative to parenteral agents. Moreover, it obviates the need for a warfarin–direct thrombin inhibitor overlap period and thus is expected to reduce the length of hospitalization.<sup>4</sup> After initiation of rivaroxaban treatment, careful attention is necessary, not only to bleeding but also to potential worsening of thrombocytopenia, because there have been rare reports of thrombocytopenia with novel oral anticoagulant use.<sup>5</sup>

### Conclusions

This case is one of the first experiences with using rivaroxaban as an off-label alternative to the standard treatments for HIT. Although the findings cannot establish the efficacy and safety of this drug for this indication—a prospective study is currently being conducted for that purpose<sup>4</sup>—they seem promising in the setting of an easier strategy to treat HIT.

### References

1. Warkentin TE. HIT: treatment easier, prevention harder. *Blood*. 2012;119:1099-100.
2. Pouplard C, May MA, Iochmann S, Amiral J, Vissac AM, Marchand M, et al. Antibodies to platelet factor 4–heparin after cardiopulmonary bypass in patients anticoagulated with unfractionated heparin or a low-molecular-weight heparin: clinical implications for heparin induced thrombocytopenia. *Circulation*. 1999;99:2530-6.
3. Cuker A, Gimotty PA, Crowther MA, Warkentin TE. Predictive value of the 4Ts scoring system for heparin-induced thrombocytopenia: a systematic review and meta-analysis. *Blood*. 2012;120:4160-7.
4. Linkins LA, Warkentin TE, Pai M, Shivakumar S, Manji RA, Wells PS, et al. Design of the rivaroxaban for heparin-induced thrombocytopenia study. *J Thromb Thrombolysis*. 2014;38:485-92.
5. Mima Y, Sangatsuda Y, Yasaka M, Wakugawa Y, Nagata S, Okada Y. Acute thrombocytopenia after initiating anticoagulation with rivaroxaban. *Intern Med*. 2014;53:2523-7.

## EDITORIAL COMMENTARY

### Another off-label novel oral anticoagulant to HIT cardiac surgery patients

Cesario F. Bianchi, MD, PhD,<sup>a</sup> and Orlando Petrucci, MD, PhD<sup>b</sup>

From the <sup>a</sup>Brazilian Biosciences National Laboratory, National Center for Research in Energy and Materials, Campinas, Brazil; and the <sup>b</sup>Department of Surgery, Faculty of Medical Science, State University of Campinas, Campinas, Brazil.

Disclosures: Authors have nothing to disclose with regard to commercial support.

Received for publication May 5, 2015; accepted for publication May 6, 2015; available ahead of print June 3, 2015.

Address for reprints: Cesario F. Bianchi, MD, PhD, National Center for Research in Energy and Materials, Brazilian Biosciences National Laboratory, Rua Giuseppe Maximo Scolfaro, 10000, Caixa Postal 6192, CEP 13083-970, Campinas, São Paulo, Brazil (E-mail: [cesariobianchi@gmail.com](mailto:cesariobianchi@gmail.com)).

J Thorac Cardiovasc Surg 2015;150:e20-2

0022-5223/\$36.00

Copyright © 2015 by The American Association for Thoracic Surgery

<http://dx.doi.org/10.1016/j.jtcvs.2015.05.024>

See related article on pages e19-20.

Heparin-induced thrombocytopenia (HIT), one of the immune-mediated thrombocytopenia and thrombosis disorders, is characterized by a decline in platelet count between 4 to 14 days (“typical onset”) after initial exposure to mainly unfractionated heparin leading to the detection of anti–platelet factor 4–heparin immune complex IgG (PF4–Hep–IgG). In patients previously exposed to heparin



(from 30 to 90 days), antibodies are produced and PF4-Hep-IgGs are formed in a few hours, with HIT developing in 1 to 2 days (“rapid onset”).<sup>1</sup> This

immune response is atypical, because IgG instead of IgM is produced after initial exposure, antibody titers disappear after 90 to 120 days, and most patients later re-exposed to heparin do not have antibody titers developed again.

PF4-Hep-IgG activates platelet FcγRIIA receptors, releasing thrombin and further activating platelets, monocytes, and endothelial cells, with the formation of fibrin leading to highly prothrombotic states. Sites of vascular injury and atherosclerosis become particularly prone to thrombus formation.<sup>1,2</sup>

HIT remains a difficult clinical problem because the unique laboratory tests necessary for a conclusive diagnosis are seldom available. Clinicians often have to make decision on a “suspected” case of HIT by using the 4Ts or the HIT Expert Probability clinical scoring systems and the laboratory detection and quantitation of specific IgG polyclonal antibodies against heparin–platelet factor 4 complex.

In this issue of the *Journal*, Abouchakra and colleagues<sup>3</sup> have reported an off-label treatment with rivaroxaban (a Factor Xa inhibitor), one of the novel oral anticoagulants, for a suspected case of HIT after cardiac surgery. Readers should be aware of and consider carefully some important points.

Although thrombocytopenia is an essential part of the diagnosis, it rarely causes bleeding. It is the associated prothrombotic state that needs serious attention.

Two major clinical points, however, must be fulfilled to characterize HIT: (1) the thrombotic events have to occur with concomitant thrombocytopenia, and (2) the timing of thrombocytopenia and thrombosis must be related to the heparin therapy. The first point occurs more frequently in sites of vascular injury, with the venous territories being the lower limb and deep venous thrombosis and pulmonary embolism being the predominant complications.<sup>1</sup> The initial presentation of this patient was chest pain with a diagnosis of a thrombus in the saphenous vein graft to the right coronary artery (vascular injury) by coronary angiography and another thrombus in the carotid bulb (possibly atherosclerosis?) by ultrasonographic examination. The second point is that the timely exposure to heparins should correlate with the clinical findings for each HIT case. Abouchakra and colleagues’ report does not provide a

detailed description regarding previous heparin exposure before the heart surgery, which is important for a conclusive diagnostic of HIT. Their patient had several other factors that could have caused a drop in platelet count, such as the use of aspirin, clopidogrel, and enoxaparin; device exposure (such as the oxygenator membrane); infections; and antibiotics. These factors, which are not mentioned in this case report, may have induced the thrombocytopenia.

Readers should also be aware that the immunoassay for anti–platelet factor 4 antibody levels (mentioned in this case report), despite being highly sensitive (about 99%), is not specific for HIT (>40%) because anti–platelet factor 4 antibodies can be present without HIT.<sup>1,4,5</sup> A washed-platelet activation assay (not available to Abouchakra and colleagues) is not by itself sufficient to confirm the diagnosis. Both IgG antibodies and a functional activation assay are necessary for a conclusive diagnosis.

After the diagnosis of HIT was considered, Abouchakra and colleagues note that lepirudin was not available (it was discontinued by the manufacturer in 2012) and give this as the reason to use rivaroxaban. Abouchakra and colleagues mention argatroban and danaparoid sodium as treatment options but do not mention fondaparinux sodium (an off-label factor Xa inhibitor), which is often available, easy to administer, low cost, and shown to have a good safety profile.<sup>6</sup> Fondaparinux sodium, however, may not work in every patient and may even cause HIT.<sup>7,8</sup>

Despite the issues raised here, rivaroxaban remains an off-label treatment option because of its single daily dose and the apparent lack of a need for monitoring the levels of factor Xa inhibition.<sup>9</sup> In addition, rivaroxaban has already been used successfully in patients with HIT.<sup>10</sup> Because rivaroxaban partially depends on renal clearance, its use in patients with renal impairment should be limited. It also has potential interactions with strong inhibitors of cytochrome P-450 and cytochrome P-450 3A4 and with permeability glycoprotein, and there is no antidote.<sup>9,11</sup>

An ongoing clinical trial (NCT01598168) is expected to present substantial results regarding the use of rivaroxaban in patients with HIT by 2016,<sup>9</sup> guiding us to a more scientifically driven decision on the use of this drug.

The most important action in patients with highly suspected HIT is avoiding contact with any heparin type after the diagnosis has been made. Long-term treatment is also critical after initial therapy. A minimum of 4 weeks of anticoagulation therapy with a nonheparin anticoagulant is the therapeutic target, even after the platelet count has increased.<sup>1</sup>

Future HIT clinical managements may include inhibition downstream of the platelet FcγRIIA receptor signaling and

identification of genetic markers that will predict a patient's likelihood of HIT-related thrombosis.<sup>12,13</sup>

## References

1. Lee GM, Arepally GM. Heparin-induced thrombocytopenia. *Hematol Am Soc Hematol Educ Program*. 2013;2013:668-74.
2. Linkins LA, Dans AL, Moores LK, Bona R, Davidson BL, Schulman S, et al; American College of Chest Physicians. Treatment and prevention of heparin-induced thrombocytopenia: antithrombotic therapy and prevention of thrombosis, 9th ed: American College of Chest Physicians evidence-based clinical practice guidelines. *Chest*. 2012;141(2 Suppl):e495S-530S.
3. Abouchakra L, Khabbaz Z, Abouassi S, Badaoui G. Rivaroxaban for treatment of heparin-induced thrombocytopenia after cardiac surgery: A case report. *J Thorac Cardiovasc Surg*. 2015;150:e19-20.
4. Wang TY, Honeycutt EF, Tapson VF, Moll S, Granger CB, Ohman EM. Incidence of thrombocytopenia among patients receiving heparin venous thromboembolism prophylaxis. *Am J Med*. 2012;125:1214-21.
5. Nazi I, Arnold DM, Moore JC, Smith JW, Ivetic N, Horsewood P, et al. Pitfalls in the diagnosis of heparin-induced thrombocytopenia: a 6-year experience from a reference laboratory. *Am J Hematol*. March 24, 2015 [Epub ahead of print].
6. Baroletti S, Labreche M, Niles M, Fanikos J, Goldhaber SZ. Prescription of fondaparinux in hospitalised patients. *Thromb Haemost*. 2009;101:1091-4.
7. Ratnaparkhi SK, Bobba B, Zafar H. Heparin-induced thrombocytopenia in a patient treated with fondaparinux. *Clin Adv Hematol Oncol*. 2010;8:61-5.
8. Bhatt VR, Aryal MR, Shrestha R, Armitage JO. Fondaparinux-associated heparin-induced thrombocytopenia. *Eur J Haematol*. 2013;91:437-41.
9. Linkins LA, Warkentin TE, Pai M, Shivakumar S, Manji RA, Wells PS, et al. Design of the Rivaroxaban for Heparin-Induced Thrombocytopenia study. *J Thromb Thrombolysis*. 2014;38:485-92.
10. Linkins LA, Warkentin TE. Rivaroxaban for treatment of hit: a riveting first experience. *Thromb Res*. 2015;135:1-2.
11. Sartori M, Favaretto E, Cini M, Legnani C, Cosmi B. Rivaroxaban in the treatment of heparin-induced thrombocytopenia. *J Thromb Thrombolysis*. March 25, 2015 [Epub ahead of print].
12. Rollin J, Pouplard C, Cheng Sung H, Leroux D, Saada A, Gouilleux-Gruart V, et al. Increased risk of thrombosis in FcγRIIA 131RR patients with HIT due to defective control of platelet activation by plasma IgG2. *Blood*. 2015;125:2397-404.
13. McKenzie SE, Sachais BS. Advances in the pathophysiology and treatment of heparin-induced thrombocytopenia. *Curr Opin Hematol*. 2014;21:380-7.