

UNIVERSIDADE ESTADUAL DE CAMPINAS  
SISTEMA DE BIBLIOTECAS DA UNICAMP  
REPOSITÓRIO DA PRODUÇÃO CIENTÍFICA E INTELLECTUAL DA UNICAMP

**Versão do arquivo anexado / Version of attached file:**

Versão do Editor / Published Version

**Mais informações no site da editora / Further information on publisher's website:**

[https://www.scielo.br/scielo.php?script=sci\\_arttext&pid=S0004-27302014000700667](https://www.scielo.br/scielo.php?script=sci_arttext&pid=S0004-27302014000700667)

**DOI: 10.1590/0004-2730000003427**

**Direitos autorais / Publisher's copyright statement:**

©2014 by Sociedade Brasileira de Endocrinologia e Metabologia. All rights reserved.

DIRETORIA DE TRATAMENTO DA INFORMAÇÃO

Cidade Universitária Zeferino Vaz Barão Geraldo

CEP 13083-970 – Campinas SP

Fone: (19) 3521-6493

<http://www.repositorio.unicamp.br>

# Diagnosis, treatment, and follow-up of medullary thyroid carcinoma: recommendations by the Thyroid Department of the Brazilian Society of Endocrinology and Metabolism

*Diagnóstico, tratamento e seguimento do carcinoma medular de tireoide: recomendações do Departamento de Tireoide da Sociedade Brasileira de Endocrinologia e Metabologia*

Ana Luiza Maia<sup>1</sup>, Debora R. Siqueira<sup>1</sup>, Marco A. V. Kulcsar<sup>2</sup>, Alfio J. Tincani<sup>3</sup>, Glaucia M. F. S. Mazeto<sup>4</sup>, Lea M. Z. Maciel<sup>5</sup>

## ABSTRACT

**Introduction:** Medullary thyroid carcinoma (MTC) originates in the thyroid parafollicular cells and represents 3-4% of the malignant neoplasms that affect this gland. Approximately 25% of these cases are hereditary due to activating mutations in the *RET* proto-oncogene. The course of MTC is indolent, and survival rates depend on the tumor stage at diagnosis. The present article describes clinical evidence-based guidelines for the diagnosis, treatment, and follow-up of MTC. **Objective:** The aim of the consensus described herein, which was elaborated by Brazilian experts and sponsored by the Thyroid Department of the Brazilian Society of Endocrinology and Metabolism, was to discuss the diagnosis, treatment, and follow-up of individuals with MTC in accordance with the latest evidence reported in the literature. **Materials and methods:** After clinical questions were elaborated, the available literature was initially surveyed for evidence in the MedLine-PubMed database, followed by the Embase and Scientific Electronic Library Online/Latin American and Caribbean Health Science Literature (SciELO/Lilacs) databases. The strength of evidence was assessed according to the Oxford classification of evidence levels, which is based on study design, and the best evidence available for each question was selected. **Results:** Eleven questions corresponded to MTC diagnosis, 8 corresponded to its surgical treatment, and 13 corresponded to follow-up, for a total of 32 recommendations. The present article discusses the clinical and molecular diagnosis, initial surgical treatment, and postoperative management of MTC, as well as the therapeutic options for metastatic disease. **Conclusions:** MTC should be suspected in individuals who present with thyroid nodules and family histories of MTC, associations with pheochromocytoma and hyperparathyroidism, and/or typical phenotypic characteristics such as ganglioneuromatosis and Marfanoid habitus. Fine-needle nodule aspiration, serum calcitonin measurements, and anatomical-pathological examinations are useful for diagnostic confirmation. Surgery represents the only curative therapeutic strategy. The therapeutic options for metastatic disease remain limited and are restricted to disease control. Judicious postoperative assessments that focus on the identification of residual or recurrent disease are of paramount importance when defining the follow-up and later therapeutic management strategies. *Arq Bras Endocrinol Metab.* 2014;58(7):667-700

## Keywords

Medullary thyroid carcinoma; MEN 2A; MEN 2B; *RET* proto-oncogene; diagnosis; treatment; follow-up

## RESUMO

**Introdução:** O carcinoma medular de tireoide (CMT) origina-se das células parafoliculares da tireoide e corresponde a 3-4% das neoplasias malignas da glândula. Aproximadamente 25% dos casos de CMT são hereditários e decorrentes de mutações ativadoras no proto-oncogene *RET*

<sup>1</sup> Thyroid Unit, Division of Endocrinology, Hospital de Clínicas de Porto Alegre, Universidade Federal do Rio Grande do Sul (UFRGS), Porto Alegre, RS, Brazil  
<sup>2</sup> Clinical Surgery Head and Neck, Instituto do Câncer do Estado de São Paulo (Icesp), Universidade de São Paulo (USP), São Paulo, SP, Brazil  
<sup>3</sup> Department of Head and Neck Surgery, Department of Surgery, Universidade Estadual de Campinas (Unicamp), Campinas, SP, Brazil  
<sup>4</sup> Discipline of Endocrinology and Metabolism, Faculdade de Medicina de Botucatu, Universidade Estadual Paulista Júlio de Mesquita Filho (Unesp), Botucatu, SP, Brazil  
<sup>5</sup> Division of Endocrinology, Department of Internal Medicine, Faculdade de Medicina de Ribeirão Preto, Universidade de São Paulo (FMRP-USP), Ribeirão Preto, SP, Brazil

## Correspondence to:

Ana Luiza Maia  
 Unidade de Tireoide,  
 Serviço de Endocrinologia,  
 Hospital de Clínicas de Porto Alegre  
 Rua Ramiro Barcelos, 2350  
 90035-003 – Porto Alegre, RS, Brazil  
 almaia@ufrgs.br

Received on April/22/2014  
 Accepted on July/12/2014

DOI: 10.1590/0004-2730000003427

(*REarranged during Transfection*). O CMT é uma neoplasia de curso indolente, com taxas de sobrevida dependentes do estágio tumoral ao diagnóstico. Este artigo descreve diretrizes baseadas em evidências clínicas para o diagnóstico, tratamento e seguimento do CMT. **Objetivo:** O presente consenso, elaborado por especialistas brasileiros e patrocinado pelo Departamento de Tireoide da Sociedade Brasileira de Endocrinologia e Metabologia, visa abordar o diagnóstico, tratamento e seguimento dos pacientes com CMT, de acordo com as evidências mais recentes da literatura. **Materiais e métodos:** Após estruturação das questões clínicas, foi realizada busca das evidências disponíveis na literatura, inicialmente na base de dados do MedLine-PubMed e posteriormente nas bases Embase e SciELO – Lilacs. A força das evidências, avaliada pelo sistema de classificação de Oxford, foi estabelecida a partir do desenho de estudo utilizado, considerando-se a melhor evidência disponível para cada questão. **Resultados:** Foram definidas 11 questões sobre o diagnóstico, 8 sobre o tratamento cirúrgico e 13 questões abordando o seguimento do CMT, totalizando 32 recomendações. Como um todo, o artigo aborda o diagnóstico clínico e molecular, o tratamento cirúrgico inicial, o manejo pós-operatório e as opções terapêuticas para a doença metastática. **Conclusões:** O diagnóstico de CMT deve ser suscitado na presença de nódulo tireoidiano e história familiar de CMT e/ou associação com feocromocitoma, hiperparatireoidismo e/ou fenótipo sindrômico característico, como ganglioneuromatose e *habitus* marfanoides. A punção aspirativa por agulha fina do nódulo, a dosagem de calcitonina sérica e o exame anatomopatológico podem contribuir na confirmação do diagnóstico. A cirurgia é o único tratamento que oferece a possibilidade de cura. As opções de tratamento da doença metastática ainda são limitadas e restritas ao controle da doença. Uma avaliação pós-cirúrgica criteriosa para a identificação de doença residual ou recorrente é fundamental para definir o seguimento e a conduta terapêutica subsequente. *Arq Bras Endocrinol Metab.* 2014;58(7):667-700

#### Descritores

Carcinoma medular de tireoide; NEM 2A; NEM 2B; proto-oncogene *RET*; diagnóstico; tratamento; seguimento

## INTRODUCTION

Medullary thyroid carcinoma (MTC) originates in the thyroid parafollicular or C cells and represents 3-4% of the malignant neoplasms that affect this gland (1) (A). Overall, 10,590 new cases of thyroid cancer were estimated among Brazilian women in 2012 (National Cancer Institute/Instituto Nacional do Câncer [Inca]; [www.inca.gov.br/estimativa/2012](http://www.inca.gov.br/estimativa/2012)). Assuming that the percentage of MTC is similar to that reported in other countries, about 430 new cases of MTC would be diagnosed each year.

MTC can be sporadic or hereditary (20-25%). The familial form is part of a genetic syndrome known as multiple endocrine neoplasia type 2 (MEN 2). The most common form of this syndrome is MEN 2A, which is characterized by MTC (95%), pheochromocytoma (50%), and hyperparathyroidism (20%), while MEN 2B includes MTC (90%), pheochromocytoma (45%), ganglioneuromatosis (100%), Marfanoid habitus (65%), and eye abnormalities (*e.g.*, thickened corneal nerves, conjunctivitis sicca, and an inability to cry tears). Familial MTC (FMTC) is defined by the presence of MTC alone, and its diagnosis is based on the absence of pheochromocytoma or hyperparathyroidism in 2 or more family generations or the pre-

sence of mutations classically associated with FMTC (2,3) (D). Activating mutations in the *REarranged during Transfection* (*RET*) proto-oncogene are the cause of the hereditary disease form, and therefore molecular diagnosis is of paramount importance in MTC management (4) (A). Approximately 50% of sporadic MTC cases exhibit somatic mutations in the *RET* gene (4,5) (A/B).

Calcitonin is a specific biomarker with a high sensitivity for MTC diagnosis. Neoplastic C cells also produce the carcinoembryonic antigen (CEA), which can be used as a prognostic marker during the follow-up of individuals with MTC (6,7) (B). Sporadic MTC is an indolent and usually solitary tumor, whereas the hereditary form is usually multicentric. Diagnosis of the sporadic form is usually established late in life (approximately the fifth or sixth decade). Neck lymph node metastases are detected in approximately 50% of cases at the time of diagnosis, while distant metastases occur in 20% of cases (8-11) (B). Early surgical intervention is the only curative therapeutic approach (11) (B). The 10-year survival rate of patients with diseases that only affect the thyroid is 95%, while that in individuals with distant metastases varies from 15-40% (12) (B).

The recommendations described below resulted from the efforts of the Thyroid Department of the Brazilian Society of Endocrinology and Metabolism to formulate evidence-based clinical guidelines for the care of individuals with MTC. Our main goal is to assist clinicians with the selection of the best strategies for patient management according to the characteristics of the Brazilian health system.

## MATERIALS AND METHODS

The present consensus complies with the strategic policy of the Thyroid Department of the Brazilian Society of Endocrinology and Metabolism for the development of national consensuses for the main diseases of the thyroid gland that are specifically formulated for the Brazilian population, while considering the actual situation of the national health system. The Program Guidelines, which were elaborated by the Brazilian Medical Association (Associação Médica Brasileira [AMB]) and the Federal Council of Medicine (Conselho Federal de Medicina [CFM]), served as a model for the present recommendations. The authors were selected according to their academic and scientific activities and clinical experiences with the management of these diseases. The clinical questions most relevant to the clinical practice were then formulated. A search for relevant articles was performed in the databases MedLine-PubMed, Embase, and Scientific Electronic Library Online/Latin American and Caribbean Health Science Literature (SciELO-Lilacs). The grade of recommendation or strength of evidence (Table 1) of the studies was established according to the Oxford classification (13) (D), which is based on the study design used, while considering the best available evidence and the Brazilian experience. This method was also used in the AMB/CFM Program Guidelines, to which the Brazilian medical community and academic milieu grew accustomed.

The search of the MedLine-PubMed, Embase, and SciELO databases allowed the identification of studies that focused on several features related to the diagnosis, treatment, and follow-up of MTC. The recommendations presented herein summarize the relevant aspects of each clinical question and are categorized as a function of the evidential strength on which they are based, as described in table 1.

**Table 1.** Definition of the grades of recommendation and strength of evidence according to the Oxford classification (adapted from reference 13) (D)

Recommendation	Strength of evidence
A	Experimental or observational studies with greater consistency
B	Experimental or observational studies with lesser consistency
C	Case reports (uncontrolled studies)
D	Opinions without critical evaluations and those based on consensuses, physiological studies, or animal models

## PART I: MTC: DIAGNOSIS

### 1. When should we suspect MTC?

The most common clinical presentation of MTC is the appearance of a single thyroid nodule. Thyroid nodules might also eventually appear within the context of a multinodular goiter or might represent an incidental finding in imaging exams of the neck (14) (D). Neck lymph node enlargement is present in 50% of these cases (8,9) (B). Although the detection of fast-growing or hardened lymph nodes or their fixation to adjacent structures is suggestive of malignancy, this does not specifically indicate MTC. The presence of associated endocrine neoplasms (pheochromocytoma, hyperparathyroidism), cutaneous lichen amyloidosis on the interscapular region, ganglioneuromas, typical facies, or a history of thyroid cancer and/or of *RET* mutations in first-degree relatives might be suggestive of hereditary MTC (2-4,15) (D/D/B/C). In a small fraction of patients, MTC exhibits systemic manifestations such as diarrhea, flushing, Cushing's syndrome due to the ectopic secretion of adrenocorticotrophic hormone (ACTH), or fractures secondary to bone metastases (2,3,15) (D/D/C).

There are no specific clinical findings that permit a firm diagnosis of MTC. For this reason, if CMT is suspected, the physician should order diagnostic tests, including fine-needle aspiration biopsy (FNAB) and serum calcitonin measurements.

### Recommendation 1

A thyroid nodule is the most common clinical manifestation of MTC. MTC must be specifically suspected in individuals with family history of thyroid cancer, *RET* mutations, and/or associations with pheochromocytoma, hyperparathyroidism, cutaneous lichen amyloidosis and/or typical findings upon physical examination such

as Marfanoid habitus and mucosal neuromas (Recommendation B).

## 2. What is the role of fine-needle aspiration biopsy (FNAB) in the diagnosis of MTC?

FNAB is among the most important tools for the diagnostic assessment of thyroid nodules. The characteristic cytological findings in MTC include the presence of predominantly isolated cells or cells arranged in isolated cohesive groups, with a round-to-oval, polyhedral, or fusiform shape, and the predominance of 3-dimensional arrangements; abundant or scarce cytoplasm that usually contains acidophil granulation; 2 or more typically round nuclei of variable size (usually present in alterations associated with endocrine disorders) and eccentric position; and the presence of amyloid, which usually appears as clumps of amorphous matter detected by Congo red staining. Further cytological findings include the presence of fusiform cells and cytoplasmic (comet-like) projections (16) (B).

The sensitivity of FNAB for diagnosing MTC in a thyroid nodule varies from 46.1-63% (17-19) (B). Although non-diagnostic, the FNAB findings in MTC are indicative of surgery in 99% of cases (17-19) (B). Approximately 82% of MTC cases are correctly identified by FNAB, while 9% are false-negative results (18,19) (B).

The most frequent reasons for FNAB failure are inadequate sampling and multinodular goiters (because the malignant nodule might not be selected for assessment) (20) (B). Additionally, differential diagnosis between MTC and other malignant thyroid neoplasms (particularly follicular lesions, Bethesda category III or IV) might be difficult because the cytological findings can be similar (20,21) (B).

The measurement of calcitonin in the washout fluid has been recommended to improve the diagnostic sensitivity of FNAB for MTC (22,23) (B/C). In a recent retrospective study, the cytology detected MTC in 21/37 lesions with 56.8% sensitivity whereas the measurement of calcitonin in the washout fluid showed sensitivity and specificity rates of 100% using a cutoff of 36 pg/mL (24) (B).

The failure to diagnose MTC in a cytological examination might negatively impact the therapeutic management of patients (20) (B). Immunochemical staining for calcitonin might be useful in doubtful cases (25) (C). Other methods that might facilitate the diagnosis of MTC include scanning electron micros-

copy and assessments of calcitonin mRNA expression; however, these are not part of the diagnostic routine (25-28) (C).

## Recommendation 2

FNAB should be included in assessments of thyroid nodules suspected of MTC (Recommendation B). Diagnosis might be facilitated by the use of additional techniques such as calcitonin measurement in the FNAB washout fluid (Recommendation B) and immunocytochemistry (Recommendation C).

## 3. What is the role of the serum calcitonin measurement in thyroid nodule assessments?

The indication for serum calcitonin measurements in thyroid nodule assessments remains controversial. According to the basal calcitonin levels, the positive predictive values of this test are 8.3%, 25%, and 100% for calcitonin levels of 20-50 pg/mL, 50-100 pg/mL, and > 100 pg/mL, respectively (29) (A). According to some authors, the basal calcitonin levels should be measured first, followed by a pentagastrin stimulation test if the basal calcitonin levels exceed 10 pg/mL. The risk of MTC is greater than 50% if the pentagastrin-stimulated calcitonin values > 100 pg/mL (30) (D). In comparison with the ultrasensitive calcitonin, the pentagastrin test still shows better diagnostic capability (31) (A). However, the pentagastrin stimulation test is not available in Brazil. The calcium stimulation test can be used as an alternative (32) (B). Nevertheless, recent studies have shown that with the improved sensitivity of the new assays, both basal and stimulated calcitonin have similar accuracy, which reduces the relevance of the stimulation tests in multiple conditions (33) (B).

Calcitonin is a sensitive and specific biomarker for the diagnosis of C cell hyperplasia and/or MTC. Increased calcitonin levels might also be present in other diseases such as chronic kidney failure, hyperparathyroidism, neuroendocrine neoplasms, lung and prostate tumors and autoimmune thyroiditis (34,35) (D/B), which are considered classic causes of false-positive results. Presence of heterophile antibodies (human antibodies with broad reactivity with antibodies of other species) can also interfere in dosage, causing falsely elevated values (or, less frequently, false-positive results) (36) (B). Of note, recent study conducted in Brazil found no changes in the serum



calcitonin levels of individuals with Hashimoto's thyroiditis (37) (B). False-negative results might be due to the hook effect and, less often, to non-calcitonin-secreting MTC (38,39) (C).

Compared with FNAB, the sensitivity of the calcitonin measurement for preoperative diagnosis of MTC is higher (approximately 100% sensitivity and 95% specificity) (18,40,41) (B). Individuals with MTC that was diagnosed from a calcitonin measurement during the investigation of thyroid nodules exhibit better postoperative outcomes than do those diagnosed by FNAB, with 10-year survival rates of 86.8% and 43.7%, respectively (42) (B).

In North America, studies of cost-effectiveness obtained results favorable to the inclusion of calcitonin measurements in initial thyroid nodule assessments (43,44) (D/B). Those data lend further support to the usefulness of calcitonin measurements in nodule investigations. Those results notwithstanding, the low prevalence of MTC (0.42-2.85%), the test costs, and problems with the standardization of the cutoff points cast doubts on the actual benefit provided by calcitonin measurements (42,45-47) (B). Additionally, the reproducibility of those results in our milieu is doubtful. For those reasons, the Brazilian consensus for thyroid nodules does not recommend the measurement of serum calcitonin in the initial nodule assessment (14) (B). However, measurement of calcitonin in the FNAB washout fluid may be useful in nodules with undetermined results (Bethesda category III/IV), considering the difficulties of FNAB to differentiate MTC from other thyroid malignancies (particularly follicular lesions) (24) (B).

The prevalence of MTC in individuals with multinodular goiters varies from 0-3.1% (48) (A). It is worth bearing in mind that FNAB might yield false-negative results in cases of multinodular goiters because not all nodules can be feasibly assessed (49) (D). Additionally, small MTC foci might not be identified with thyroid ultrasound (US). For all those reasons, the serum calcitonin measurement might be useful for detecting MTC in cases of multinodular goiter (50,51) (A).

### **Recommendation 3**

MTC screening via a serum calcitonin measurement in individuals with thyroid nodules remains controversial. Because of problems with reference value standardization and its doubtful cost-effectiveness, the measurement of serum calcitonin is not indicated in

the routine investigation of thyroid nodules (Recommendation B).

### **4. What are the meanings of the serum levels of tumor markers for the initial diagnosis of MTC?**

MTC secretes a variety of products, including calcitonin, CEA, amyloid, somatostatin, ACTH, vasoactive intestinal peptide (VIP), and serotonin, among others (52,53) (B). Calcitonin is the most important biomarker and is used in the diagnosis, surgical planning, postoperative management, and prognosis of individuals with MTC (54) (D).

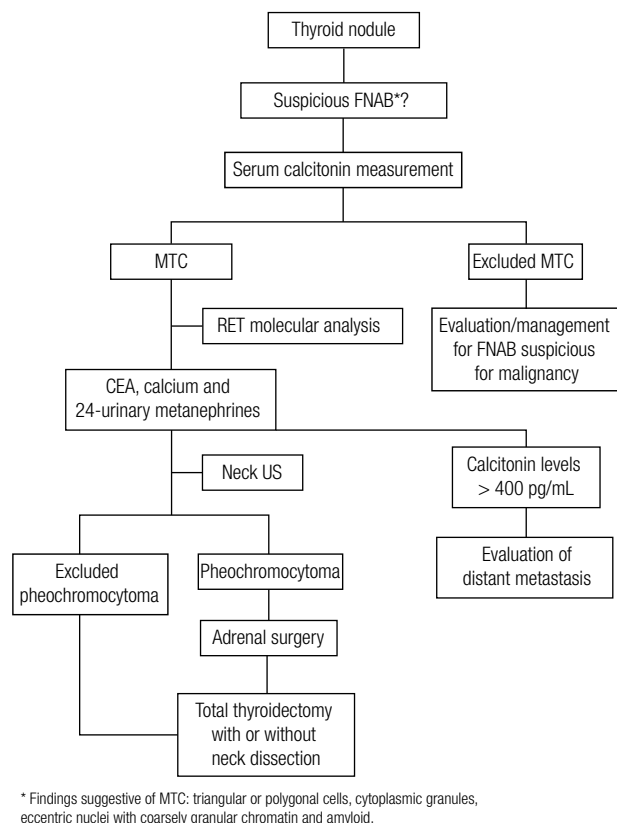
In individuals with MTC, the preoperative calcitonin levels correlate with the tumor size and the presence of metastases (6,7) (B). Calcitonin levels < 100 pg/mL are associated with an average tumor diameter of 3 mm, while levels > 1,000 pg/mL are associated with an average tumor diameter of 2.5 cm. Neck lymph node metastases might be present with basal calcitonin levels of 10-40 pg/mL, while metastatic disease should be suspected at levels of 150-400 pg/mL. The presence of lymph node metastases or calcitonin levels > 400 pg/mL indicate the need to identify distant metastases (6,7) (B).

Additionally, the serum CEA levels might be used for the risk stratification of individuals with MTC. CEA levels > 30 ng/mL are suggestive of lymph node metastases in the ipsilateral central and lateral neck compartments, while levels > 100 ng/mL correlate with contralateral lymph node metastases and distant metastases. Values > 30 ng/mL were found to correlate with low cure rates (55) (B).

The preoperative serum calcitonin levels seem to correlate more strongly with extensions of MTC, as compared to the neck US findings. Basal calcitonin levels of 20, 50, 200, and 500 pg/mL exhibited correlations with metastases in the lymph nodes of the ipsilateral, lateral, and central compartments, contralateral central compartment, contralateral lateral compartment, and superior mediastinum, respectively (56) (B).

### **Recommendation 4**

Preoperative calcitonin levels correlate with the tumor size and stage and indicate the presence of local and/or distant metastases (Recommendation B). The individuals with suspected MTC and calcitonin levels > 150 ng/mL must be investigated for the presence of locoregional and distant metastases by imaging tests (please see Recommendation 6, Flowchart 1) (Recommendation B).



**Flowchart 1.** Initial diagnostic approach of medullary thyroid carcinoma.

## 5. What is the value of neck US for the diagnosis of MTC?

Thyroid US is a relevant part of a thyroid nodule assessment. US allows an accurate assessment of the nodule size and characteristics, as well as the identification of other nodules. Some nodule characteristics evidenced by US correlate with a higher risk of malignancy, including hypoechogenicity, microcalcifications, irregular margins, predominantly central vascularization, and the presence of enlarged neck lymph nodes (57-59) (B).

Most individuals with MTC (> 90%) exhibit hypoechoic nodules, intranodular calcifications, and an absence of the halo sign on US; further possible findings include the presence of intranodular (79%) and perinodular (50%) blood flow (60) (B). Some cases exhibit intranodular bright echogenic foci that correspond to amyloid-surrounded calcium deposits (61) (B).

Neck US is the most sensitive imaging method for neck metastasis detection (10) (B). Approximately 75% of patients with MTC that is clinically detectable by palpation exhibit lymph node metastases (8) (B). As the presence of lymph node and/or distant metastases indicates the need for changes in the therapeutic manage-

ment, US might be considered indispensable for treatment planning. The sensitivity of preoperative neck US is considered as moderate, since 32% and 14% of individuals exhibit false-negative results in the central and ipsilateral areas, respectively (62) (B). However, a recent study described higher rates of sensitivity of US in predicting metastasis in the lateral and central neck (93.8% and 30.0%, respectively) (63) (B). One important limitation of US is that it is operator-dependent, and therefore the results vary as a function of the operator's experience. This most likely explains why a larger number of neck lymph node metastases are detected with surgical dissection, compared to US. Nevertheless, the sensitivity, specificity, and diagnostic accuracy of US for the preoperative detection of neck metastases are superior to those of computed tomography (CT; 77, 70, and 74% vs. 62, 79, and 68%, respectively) (64) (B). Preoperative neck US is a valuable tool in assessing patients with thyroid nodules; it provides useful information predicting cervical lymph node metastasis, especially in the lateral neck, and thus defining surgical extension (63) (B).

## Recommendation 5

Neck US is indicated in all individuals with suspected MTC (Recommendation B). In addition to identifying characteristics suggestive of malignancy in the thyroid nodules and allowing the performance of US-guided FNAB, US is the most sensitive test for detecting neck metastases and thus contributes to therapeutic planning (Recommendation B).

## 6. Which complementary tests should be performed before thyroidectomy in patients with suspected MTC?

The aim of the preoperative assessment of individuals with suspected or confirmed MTC is to establish the extension of thyroid disease and to identify the eventual presence of associated comorbidities such as hyperparathyroidism and/or pheochromocytoma in hereditary cases.

The presence of local and/or distant metastases interferes with surgery planning in individuals with MTC. Neck metastases appear early during the course of MTC (9,65) (B). Distant metastases are detected in 7-17% of all cases at the time of diagnosis and frequently appear in multiple sites (lungs, liver, bones, and less often in the brain and skin) (10,11,66,67) (B/B/B/A).

Neck US must be performed in all affected individuals (56-58) (B). Findings suggestive of neck metastases or calcitonin levels > 400 pg/mL indicate the need

for additional tests (6,7) (B). It is worth noting that the radiological detection of distant metastases is quite improbable when the calcitonin levels are  $< 250$  pg/mL (68) (B). The most efficacious approach to diagnosing distant metastases includes a combination of CT of the neck and chest and magnetic resonance imaging (MRI) of the liver (10) (B). The risk of distant metastases is similar in individuals with sporadic or hereditary MTC (7) (B).

Pheochromocytoma is a tumor that originates in the chromaffin cells of the adrenal medulla and occurs in approximately 30-50% of individuals with MEN 2A or 2B. Adrenomedullary disease is more frequently bilateral (up to 78% of cases) in MEN 2, thus contrasting with sporadic pheochromocytoma, which usually appears as a single unilateral lesion. Additionally, pheochromocytoma tends to appear earlier in individuals with MEN 2 and seldom metastasizes. The clinical manifestations of pheochromocytoma are caused by catecholamine hypersecretion and include the most frequent manifestations of arterial hypertension, tachycardia, headaches, and excessive sweating (69,70) B/C). Nevertheless, some individuals might merely exhibit a discrete increase in catecholamine levels that is unattended by any signs or symptoms (71) (D).

Individuals with hereditary MTC should be screened for pheochromocytoma, given their high risk of that disease (72) (B). As up to 10% of apparently sporadic MTC have a *RET* germline mutation, the presence of pheochromocytoma should be excluded in any patient with suspected MTC before the thyroidectomy, due to the high risk of anesthesia and the surgical procedure (73,74)(D/B). A pheochromocytoma diagnosis is based on the identification of excessive catecholamine production by measuring the plasma and/or urine catecholamine and/or metanephrine levels. The measurement of plasma fractionated metanephrines seems to be the most useful test in cases of hereditary pheochromocytoma, with sensitivity and specificity rates of 99% and 98%, respectively. The sensitivity and specificity rates of urine metanephrines, plasma catecholamines, and urine catecholamines are 97-100% and 93-94%, 76-84% and 81-88%, and 84-86% and 88-99%, respectively (75,76) (B). Therefore, normal fractionated plasma metanephrines levels practically rule out pheochromocytoma in high-risk patients such as those with genetic syndromes (77-79) (B/B/D). When plasma fractionated meta-

neprine measurements are unavailable, urine levels might be assessed.

Computed tomography or MRI of the abdomen might be performed to identify the localization of a pheochromocytoma. CT of the abdomen was able to identify the localization of hereditary adrenal tumors in 76% of the evaluated cases (80) (B). Some CT-detectable nodule features might be helpful for the differential diagnosis among various types of adrenal lesions, including adenoma, pheochromocytoma, and carcinoma. The lesion density is 1 of the parameters that helps to distinguish adrenal adenomas from non-adenomas because adenoma densities are low due to their high intracellular lipid contents. CT densities are measured in Hounsfield units (HU); with a cutoff point of 10 HU, non-contrast-enhanced CT exhibits a 75% sensitivity rate and 100% specificity rate for the differentiation between adrenal adenomas and non-adenomas. Adenoma densities are usually lower than those of other tumors (pheochromocytoma, carcinoma), and contrast washout occurs faster in adenomas, compared to other adrenal lesions. A  $> 50\%$  washout at 10 minutes after administration exhibits 100% sensitivity and specificity for the identification of adrenal adenomas, compared to pheochromocytomas, carcinomas, and metastatic lesions (81-83) (B).

Hyperparathyroidism occurs in approximately 10-20% of individuals with MEN 2A and is either asymptomatic or presents with manifestations secondary to hypercalcemia (84) (D). In suspected cases of hereditary MTC associated with MEN 2A, a serum albumin-adjusted calcium measurement should be included in the preoperative investigation (73,85) (D).

### Recommendation 6 (Flowchart 1)

Neck US must be performed in all affected individuals for detection of locoregional metastases. In individuals with suspected locoregional metastases or calcitonin levels  $> 400$  pg/mL, the presence of distant metastases must be investigated before surgery (Recommendation B). The presence of pheochromocytoma must be investigated by the measurement of plasma fractionated metanephrines or urine metanephrine levels, if not available the blood measurement (Recommendation B). Once the diagnosis is confirmed, the adrenal tumor must be removed before thyroidectomy (Recommendation B). The presence of hyperparathyroidism might be investigated through a serum calcium level measurement after adjusting for the albumin concentration (Recommendation D).



## 7. Which individuals with confirmed or suspected MTC should be subjected to *RET* proto-oncogene molecular testing?

The *RET* proto-oncogene comprises 21 exons and encodes a tyrosine-kinase receptor that is expressed in neural crest-derived cells, including the thyroid C cells, adrenal medulla, and parathyroid glands. The RET protein comprises 3 domains: an extracellular cysteine-rich domain with cadherin-like repeats, a transmembrane domain, and an intracellular domain with 2 tyrosine-kinase domains (TK1 and TK2). Hereditary MTC affects approximately 1 in every 30,000 individuals and is caused by germline mutations in the *RET* proto-oncogene, an autosomal dominant genetic syndrome with approximately 100% penetrance and a variable phenotype. The mutations mainly affect the *RET* exons 10, 11, and 16, and less commonly the exons 5, 8, 13, 14, and 15 (84,86) (D).

Several studies have found correlations between specific *RET* mutations and the various clinical syndromes associated with MEN 2. Mutations at codon 634 (exon 11) are associated with the presence of pheochromocytoma and/or hyperparathyroidism, while mutations at codon 918 (exon 16) are specific for MEN 2B. Similarly, mutations at codons 768 and 804 are associated with FMTC (Table 2) (87,88) (B/D).

Molecular diagnosis is superior to clinical and/or biochemical diagnosis for the identification of asymptomatic individuals who are at risk of neoplasia (89-91) (B/C/B). Molecular testing allows the identification of the *RET* mutations that cause MEN 2A and MEN 2B in 95–100% of the evaluated cases (92,93) (B/D).

Genetic screening should be performed in all individuals with MTC, rather than in the cases suspected of the hereditary form only, as 4-10% of apparently sporadic MTCs exhibit germline *RET* mutations; these occur particularly among young patients and/or those with multifocal disease (42,94-96) (B).

Therefore, investigations of *RET* proto-oncogene mutations are of paramount importance in the diagnostic assessment of and therapeutic planning for individuals with MTC.

### Recommendation 7

A molecular assessment is indicated for all individuals with C cell hyperplasia, (familial or apparently sporadic) MTC, and/or MEN 2 (Recommendation B). The molecular diagnosis might guide the choice of therapeutic procedures and consequently change the natural course of disease, indicate genetic counseling, and help to establish the disease prognosis (Recommendation B).

**Table 2.** Correlations between the clinical presentations and germline *RET* mutations in hereditary medullary thyroid carcinoma

Phenotype	Clinical presentation	%	<i>RET</i> germline mutation Exon (Codons)
Sporadic	MTC	75-80	None
Hereditary		20-25	
MEN 2A	MTC, pheochromocytoma, hyperparathyroidism	80-90	<b>8</b> (G533) <b>10</b> (C609, C611, C618, C620) <b>11</b> (C630, C633, C634*, 635/insertion, S649) <b>13</b> (E768, L790, Y791) <b>14</b> (V804) <b>15</b> (S891) <b>16</b> (R912)
MEN 2B	MTC, pheochromocytoma, marfanoid habitus	1-5	<b>14</b> (V804+E805, V804+Y806, V804 e S904) <b>15</b> (A883) <b>16</b> (M918T*)
FMTC	MTC	10-15	<b>5</b> (R321) <b>8</b> (531/9 duplication, G533) <b>10</b> (C609, C611, C618, C620) <b>11</b> (C630, C633, C634, 635/insertion, S649) <b>13</b> (E768, L790, Y791) <b>14</b> (V804) <b>15</b> (Y891) <b>16</b> (R912)

MEN: multiple endocrine neoplasia; MTC: medullary thyroid carcinoma. \* Most frequent mutations.

## 8. When should the relatives of individuals with MTC be assessed? What is the relevance of a *RET* molecular assessment in such individuals?

Hereditary MTC is an autosomal dominant disease, and therefore the likelihood of transmission from 1 generation to the next is 50% (89) (B). Following the identification of a *RET* mutation in an individual (proband), all of his or her first-degree relatives should be subjected to genetic assessment. The molecular analysis of the *RET* proto-oncogene in a proband's relatives is of paramount importance because it allows for early diagnosis and treatment and consequently better prognosis (87,93) (B). For these reasons, the indication of molecular testing is considered essential and is recommended in the guidelines developed by the American Thyroid Association (ATA) and the European Thyroid Association (ETA), as well as in the Clinical Guidelines on Medullary Thyroid Carcinoma for Private Health Insurance and Plans from the Brazilian Medical Association and the National Regulatory Agency for Private Health Insurance and Plans (73, 97,98) (D).

Total thyroidectomy should be considered in asymptomatic carriers of *RET* mutations (73,89) (D/B). The appropriate age for prophylactic surgery depends on the results of *RET* molecular testing, the clinical data, and the serum calcitonin levels. The various mutation types correlate with the degree of MTC aggressiveness, and therefore molecular testing facilitates decision-making with respect to the extent of surgery and the age at which surgery should be performed. Additionally, the pre-operative serum calcitonin levels contribute to surgery planning and the establishment of disease prognosis, in addition to being used in postoperative follow-ups (6,99,100) (B/C/B). The presence of neck metastases should be also investigated with physical examinations and US before surgery (60,62,100) (B).

Based on genotype-phenotype correlation studies, ATA formulated a series of recommendations for prophylactic thyroidectomy in asymptomatic *RET* mutation carriers. The different types of mutations are classified in 4 risk-based categories according to the tumor aggressiveness (A < B < C < D). In individuals with ATA A and B mutations (codons 768, 790, 791, 804 and 891 and 609, 611, 618, 620, and 630, respectively), the risk of MTC is moderate, and in most cases, prophylactic surgery might be performed after the age of 5 years. Individuals with mutations in codon 634 (ATA risk level C) are at risk of developing MTC early in life, and prophylactic surgery should be performed before the age

of 5 years (101) (B). Individuals with phenotype MEN 2B-associated mutations (ATA risk level D) have an even higher risk of early MTC development and therefore should be subjected to prophylactic thyroidectomy prior to 1 year of age or at the time of diagnosis (73) (D).

In children and young adults with *RET* mutations, the presence of a palpable thyroid nodule at the time of diagnosis correlates strongly with persistent or recurrent MTC (100) (B). Those data reinforce the relevance of the early investigation of *RET* mutations.

Relatives who test negative for *RET* mutations are considered to have no risk of MTC and/or associated neoplasms and might thus be released from further follow-up.

### Recommendation 8

All first-degree relatives of individuals with MTC and germline *RET* mutations should be subjected to molecular screening (Recommendation B).

## 9. Does the mutation type interfere with the clinical presentation of MTC?

Most families with MEN 2A exhibit mutations in 1 of the 5 cysteine residues in exon 10 (codons 609, 611, 618, and 620) or 11 (codon 634) of the *RET* extracellular domain (Table 2). All mutations in codon 634 are associated with pheochromocytoma and/or hyperparathyroidism (87,92) (B). Specific amino acid changes in the same codon interfere with the genotype-phenotype correlation. In individuals with MEN 2A, mutation C634R is associated with a higher rate of metastasis at the time of diagnosis, compared to mutations C634W and C634Y (102) (B).

The risk of pheochromocytoma in individuals with MEN 2 varies as a function of the mutated codon. The adrenal tumor occurrence rates are 28%, 21%, and 3% in carriers of mutations in the highest-risk category (mutations in codon 918), in the high-risk category (mutations in codons 634, 630, 609, 611, 618, and 620), and in the lower-risk category (mutations in codons 768, 790, 791, 804, and 891) (72) (B). Mutation C634W correlates strongly with a high penetrance of pheochromocytoma (103) (B).

A specific mutation in codon 16 (M918T) has been found in approximately 95% of individuals with MEN 2B, the mutation A883F (exon 15) has been identified in 2-3% of the cases, and the double mutation V804M/Y806C (exon 14) in the same allele has been described in 1 patient with MEN 2B. Mutations in codons 883 and

918 correlate with the occurrence of MTC at a younger age, an increased risk of metastasis, and an increased disease-specific mortality (86,92,104) (D/B/B).

Approximately 90% of families with hereditary MTC exhibit mutations in *RET* exon 10 (codons 609, 611, 618, and 620) and exon 11 (codon 634) (6,10) (B). Substitutions in the tyrosine-kinase domain-coding exons 13 (codons 768, 790, and 791), 14 (codons 804 and 844), and 15 (codon 891) are less common. In such cases, MTC appears later, and the prognosis is more favorable compared to that of other forms of MTC (92) (B).

However, it is worth noting that individuals from the same family who carry the same *RET* mutation can exhibit variable phenotypic expressions and degrees of tumor aggressiveness (102) (B). In recent years, the presence of *RET* gene variants or polymorphisms has been associated with changes in the clinical presentation and natural history of MEN 2 (86,105) (D/B).

### Recommendation 9

The knowledge of the type of *RET* mutation provides relevant information about the clinical presentation of MEN 2 and the biological behaviors of the associated neoplasms (Recommendation B).

## 10. In addition to endocrine tumors, what are the clinical manifestations associated with *RET* proto-oncogene mutations?

In addition to pheochromocytoma and hyperparathyroidism, hereditary MTC is rarely associated with cutaneous lichen amyloidosis and Hirschsprung's disease (106-108) (C/B/D).

Cutaneous lichen amyloidosis (CLA) is an itchy hyperpigmented skin lesion that appears on the upper area of the back (interscapular region). The association between mutations in *RET* codon 634 and CLA was first described in 1989 (106) (B). CLA can appear early and usually precedes thyroid disease (106,107) (C/B).

Inactivating *RET* germline mutations appear in 10-40% of cases of Hirschsprung's disease; this disease comprises the congenital absence of the intestinal intermuscular (Auerbach's), and superficial (Meissner's) and deep (Henle's) submucosal plexuses, leading to symptoms of intestinal obstruction during the neonatal period, as well as constipation, abdominal distension, and vomiting in adulthood. Mutations in exon 10 are associated with the concomitant occurrence of MEN 2

and Hirschsprung's disease (108) (B). The affected individuals carry a single mutation, thus suggesting that the effects of that mutation vary as a function of the tissues in which *RET* is expressed (109) (C).

### Recommendation 10

The presence of CLA or Hirschsprung's disease indicates the suspected occurrence of hereditary MTC and therefore the need to perform a *RET* molecular assessment (Recommendation B).

## 11. When and how to screen for pheochromocytoma and hyperparathyroidism?

MEN 2A is the most common form of MEN and is characterized by the occurrence of MTC, pheochromocytoma, and hyperparathyroidism. MTC occurs in 95% of individuals with MEN 2A, while the risks of unilateral or bilateral pheochromocytoma and hyperparathyroidism are 57%, and 15-30%, respectively (84,110) (D/D). Adrenal disease is usually benign, multicentric, and bilateral, and, as a rule, it is detected after the onset of MTC. Hyperparathyroidism usually involves all of the parathyroid glands, and gland hyperplasia is the most commonly detected histological lesion in early-stage disease. However, when diagnosis is delayed, adenoma occurs concomitantly with hyperplasia (84) (D). MEN 2B is the less common variety of MEN 2 and exhibits a more aggressive form of MTC, as well as the occurrence of pheochromocytoma; however, hyperparathyroidism does not occur (84) (D).

A recent study assessed the mean age at onset of pheochromocytoma in individuals with MEN 2A, according to the ATA risk categories described above. The authors found that the first pheochromocytomas were diagnosed at ages 25, 34, 40, and 56 year old in individuals classified as ATA risk levels D, C, B, and A, respectively and that the occurrence frequencies were 27, 32, 17, and 3% in categories D, C, B, and A, respectively (111) (B).

The youngest ages at pheochromocytoma diagnosis were 12 and 5 years old in carriers of mutations in codons 918 and 634, respectively (72,112,113) (B/D/B). Less aggressive mutations such as those in codons 609, 611, and 618 and in codons 768, 790, and 891 are associated with a later onset of pheochromocytoma, specifically at ages 19 and 28 years old, respectively (72,114) (B/B). Therefore, the investigation of adrenal tumors in patients with MEN 2 should begin at 8 years of age

in carriers of mutations in codons 918, 634, and 630, and after 20 years of age in the remainder of the cases (72) (B). Assessments might be performed by measuring the plasma or urine metanephrine levels (77-79) (B/B/D). The ruling out of pheochromocytoma is of paramount importance in cases of hereditary MTC because the adrenal tumor should be treated before the thyroidectomy.

Hyperparathyroidism rarely occurs in children, as the mean age at diagnosis is 38 years old in individuals with MEN 2A (115,116) (B/B). Serum calcium and albumin measurements should begin at 8 years of age in carriers of mutations in codons 630 and 634, and at 20 years of age in carriers of other mutations associated with MEN 2A, and should be repeated annually. Recently, a case of hyperparathyroidism diagnosed in a 5-year-old child with MEN 2A was reported (117) (C).

### Recommendation 11

In asymptomatic cases or in the absence of adrenal masses, urine and/or fractionated plasma metanephrines measurements should begin at 8 years of age in individuals with MEN 2B or 2A who carry mutations in codons 630 or 634, and after 20 years of age in the remainder of individuals with MEN 2A.

Hyperparathyroidism screening must be performed annually by measuring the total calcium and albumin levels, starting at 8 years age in carriers of mutations in *RET* codons 630 and 634 and at 20 years of age in the remainder of individuals with MEN 2A.

## PART II: MTC – SURGICAL TREATMENT

### 1. What is the surgical treatment for individuals with MTC limited to the thyroid gland?

Upon preoperative assessment, MTC is considered to be limited to the thyroid gland if there is no evidence of involvement of adjacent structures, or lymph node or distant metastases. In such cases, the indicated surgical treatment comprises total thyroidectomy with (elective) prophylactic dissection of the central compartment (levels VI and VII; Figure 1) (66,118-120) (B). Given the risk of hidden metastatic disease, prophylactic dissection of the lateral compartments might be added, particularly when the tumor is > 1 cm, if metastases are found in the central compartment, or elevated calcitonin levels (121-123) (B/B/D).

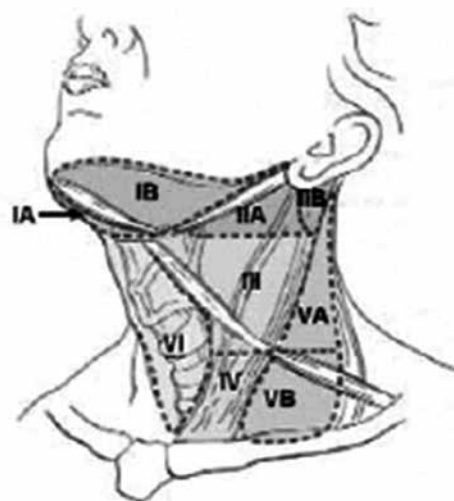


Figure 1. Cervical lymph nodes anatomy.

### Recommendation 1

The surgical treatment recommended for individuals with MTC limited to the thyroid gland is total thyroidectomy and elective dissection of the central compartment (Recommendation B).

### 2. What is the surgical approach for individuals with MTC and locoregional disease diagnosed during the preoperative assessment?

In individuals with MTC, the presence of locoregional disease indicates the need for a total thyroidectomy associated with dissection of the lymph nodes in the central compartment (levels VI and VII; Figure 1) (104) (B). Lateral lymph node dissection (levels, II, III, IV, and V) is indicated when metastases are suspected in any of those levels (121) (B). The benefit of prophylactic lateral dissection when metastases are only located in the central compartment is controversial. Some authors support the US preoperative evaluation for the detection of metastases and argue against prophylactic dissection. However, due to the high incidence of lymph node metastases and the risk of occult metastatic disease, others indicate compartment oriented lymph node dissections in the first surgery because of the complications associated with re-interventions (73,121-123) (D/B/B/D).

The current American Joint Committee on Cancer (AJCC) 6<sup>th</sup> edition TNM (tumor, node, metastasis) classification system is used for postoperative staging of MTC (Table 3) (124). The likelihood of a cure is low in cases with extrathyroid disease. The biochemical cure



**Table 3.** American Joint Committee on Cancer TNM Classification

Primary tumor (T)
T0 – No evidence of primary tumor
T1 – Tumor 2 cm or less in greatest dimension limited to the thyroid (Supplementum to the 6 <sup>th</sup> edition: T1a, tumor 1 cm or less; T1b, tumor more than 1 cm but not more than 2 cm)
T2 – Tumor more than 2 cm, but not more than 4 cm, in greatest dimension limited to the thyroid
T3 – Tumor more than 4 cm in greatest dimension limited to the thyroid or any tumor with minimal extra-thyroidal extension (e.g. extension to sternothyroid muscle or perithyroid soft tissues)
T4a – Tumor of any size extending beyond the thyroid capsule to invade subcutaneous soft tissues, larynx, trachea, esophagus, or recurrent laryngeal nerve
T4b – Tumor invades prevertebral fascia or encases carotid artery or mediastinal vessels
Regional lymph nodes (N) are the central compartment, lateral cervical, and upper mediastinal lymph nodes
NX – Regional lymph nodes cannot be assessed
N0 – No regional lymph node metastases
N1 – Regional lymph node metastases
N1a – Metastasis to Level VI (pretracheal, paratracheal, and prelaryngeal/Delphian lymph nodes)
N1b – Metastasis to unilateral, bilateral, or contralateral cervical or superior mediastinal lymph nodes
Distant metastases (M)
MX – Distant metastasis cannot be assessed
M0 – No distant metastasis
M1 – Distant metastasis
Stage
• Stage I: T1, N0, M0
• Stage II: T2, N0, M0
• Stage III: T3, N0, M0 T1, N1a, M0 T2, N1a, M0 T3, N1a, M0
• Stage IVA: T4a, N0, M0 T4a, N1a, M0 T1, N1b, M0 T2, N1b, M0 T3, N1b, M0 T4a, N1b, M0
• Stage IVB: T4b, any N, M0
• Stage IVC: any T, any N, M1

Sixth edition (115).

rates in individuals with preoperative basal calcitonin levels > 300 pg/mL, a primary tumor > 10 mm, and persistent metastatic disease after lymph node dissection are below 50% (7) (B). As a rule, only 10-40% of individuals with neck metastases achieve biochemical cures (7,119) (B), while relapses occur in 3.3% of the individuals who attain normal basal calcitonin levels after a follow-up of

0.7-7.5 years (125) (B). Similar cure rates (~38%) are reported in individuals who are subjected to extensive surgery (7) (B). Therefore, as extensive surgery is not associated with higher cure rate, less aggressive procedures should be indicated in cases with advanced local disease or distant metastases in order to maintain control of local disease while preserving the parathyroid function, vocal cords, and deglutition (73,104) (D/B).

### Recommendation 2

In cases with locoregional disease, total thyroidectomy with central compartment lymph node dissection is indicated (Recommendation B). Lateral lymph node dissection is indicated when metastases are present or suspected (Recommendation B). Less aggressive surgery should be indicated in cases with advanced local disease and/or distant metastases to achieve local disease control while preserving the patient's voice, deglutition, and parathyroid function (Recommendation B).

### 3. What is the management of individuals with postoperative diagnoses of MTC?

In individuals with MTC that was diagnosed after a total lobectomy (thyroid lobe and isthmus), thyroidectomy can be complemented by central compartment dissection or only expectant management in selected cases (126,127) (B). According to some authors, the latter alternative might apply to individuals with undetectable calcitonin levels at 2 months after thyroidectomy, unifocal MTC limited to the gland, tumor-free surgical margins, the absence of C cell hyperplasia, the absence of neck lymph node metastases in physical examination or on US, and a diagnosis of sporadic MTC based on negative *RET* molecular testing (120,126,127) (B).

### Recommendation 3

Completion thyroidectomy and prophylactic central compartment dissection are indicated in patients with postoperative diagnoses of MTC (Recommendation B). Expectant management might be considered in selected cases (Recommendation B).

### 4. What is the approach to the parathyroid glands in surgery for MTC?

As a rule, normal parathyroid glands should be preserved when thyroidectomy is performed. However, those glands might be accidentally removed or their vascularization might be compromised during surgery, espe-



cially for those glands located in the lower poles. The risk increases when a central compartment dissection is performed (124,125) (D/B). When devascularization occurs, the affected glands should be grafted onto the sternocleidomastoid muscle. In cases with a risk of hyperparathyroidism, such as the presence of MEN 2A-related mutations, grafting should be performed in the non-dominant forearm to facilitate the gland removal procedure in the event of recurrent hyperparathyroidism (128-130) (B).

The hyperparathyroidism occurs in approximately 10 to 20% of patients with MEN 2A. It is usually associated with mild and often asymptomatic disease, especially in young patients. When indicated treatment, it is important to establish whether the disease is restricted to one or multiple glands and then, decide the most appropriate surgical procedure. The following surgical procedures may be used, depending on the number of glands involved: total parathyroidectomy with auto-transplantation, subtotal parathyroidectomy, or removal of a single gland (128,129) (B). The occurrence of permanent hypoparathyroidism is usually associated with total parathyroidectomy, although also already been reported after subtotal parathyroidectomy, or even after excision of two glands (130) (D). In cases of hyperparathyroidism that appear in individuals who previously underwent surgery for MTC, the affected gland should be identified via imaging methods such as US, CT, or sestamibi scintigraphy before surgery (129,131) (B). The successful use of calcimimetics has been reported in cases of persistent hyperparathyroidism (132) (B).

#### Recommendation 4

In cases without preoperative hyperparathyroidism, the “*in situ*” preservation of the parathyroid glands is always desirable. When the glands are accidentally removed or there is a risk of devascularization, the glands should be autografted into the sternocleidomastoid muscle (Recommendation B). In cases with hyperparathyroidism, MEN 2A, or prior surgery for MTC, the affected parathyroid gland should be identified with imaging methods to decide upon a subtotal or total parathyroidectomy, followed by a forearm autograft (Recommendation B).

### 5. What is the surgical approach in asymptomatic individuals with *RET* mutations?

Asymptomatic individuals with *RET* proto-oncogene mutations should be assessed before surgery by

measuring the serum calcitonin levels and using neck US to identify the presence of thyroid nodules and lymph node metastases, as these indicate the need for a different surgical approach (6,64) (B). In such cases, the ATA guidelines recommend the application of a risk categorization system relative to the minimum age at the onset of MTC and the tumor aggressiveness, including the likelihood of metastasis, likelihood of cure, morbidity, and mortality (73,133) (D). That system clusters codons into risk levels ranging from A (least aggressive) to D (most aggressive; see **Part I: MTC – Diagnosis – Question 8 of the present consensus**). Based on the risk level that corresponds to the affected *RET* codon, therapeutic decision-making is performed according to the best age for so-called prophylactic thyroidectomy and the need for neck dissection. Preferably, the surgical approach should be performed in reference centers with experienced surgeons and a large volume of thyroid surgeries.

Additionally, the likelihood of pheochromocytoma onset and the age at which to begin investigating this onset are estimated according to those risk levels (see **Part I: MTC – Diagnosis – Question 6 of the present consensus**). When pheochromocytoma is diagnosed, it should be subjected to surgical treatment before MTC (122,134,135) (B).

#### Recommendation 5

The surgical approach in asymptomatic individuals with *RET* proto-oncogene mutations should consider the risk stratification according to the codon that exhibits the mutation, as follows:

- **Group D (MEN 2B):** total thyroidectomy in the first year of life; if there is evidence of lymph node metastases, the thyroid nodule is > 5 mm, or the serum calcitonin level is > 40 pg/mL, central compartment dissection is also indicated. Individuals older than 1 year of age are indicated for (elective) “prophylactic” central dissection.
- **Group C:** total thyroidectomy before 5 years of age.
- **Groups A and B:** total thyroidectomy after 5 years of age if there is a lack of evidence for MTC (normal basal serum calcitonin levels and normal neck US).

Individuals in groups A, B, and C should only be subjected to central compartment dissection if there is clinical and/or imaging evidence of metastatic disease, the nodule size is  $\geq 5$  mm, and the serum calcitonin level is  $> 40$  pg/mL (Recommendation B).

## 6. What is the surgical approach in individuals with MTC and distant metastases?

The presence of distant metastases makes a biochemical cure of MTC unlikely. For this reason, the presence of distant metastases should be carefully assessed when the serum calcitonin level is  $> 400$  pg/mL (125,136,137) (B/B/D). The surgical treatment of individuals with metastatic disease should focus on local disease control and mainly on the patients' quality of life (137) (D).

### Recommendation 6

The surgical treatment of individuals with advanced local disease or distant metastases should be less aggressive and aimed at local disease control, while preserving the patient's voice, deglutition, and the parathyroid function and avoiding potential hemorrhagic complications due to the invasion of vascular structures (Recommendation B).

## 7. What are the indications for mediastinal lymph node dissection in MTC patients?

The mediastinum is divided into a superior portion, which is located above the pericardium, and 3 inferior divisions, the anterior, middle, and posterior. The middle mediastinum contains the heart and pericardium, the anterior mediastinum is bounded anteriorly by the pericardium and posteriorly by the sternum and contains mainly the thymus, and the posterior mediastinum is the area behind the pericardium and contains the esophagus and the thoracic aorta, among other structures (138) (B). The superior mediastinum contains the thymus and the brachiocephalic artery anteriorly and the trachea and esophagus posteriorly. The superior mediastinum corresponds to level VII of the neck lymph nodes and is included in the dissection of the central compartment (104,139) (B). Therefore, elective superior mediastinal dissection is usually performed during surgery for MTC via the cervical access. The presence of metastases in lymph nodes of inferior mediastinum, diagnosed by imaging methods (CT or MRI), can be considered as distance metastatic disease, which significantly decreases the chance for cure. Thus,

the dissection of this area should only be offered as a palliative treatment in patients with high risk of airway obstruction or bleeding (64,121) (B).

### Recommendation 7

Elective superior mediastinal dissection is usually performed during surgery for MTC (Recommendation B). The dissection of the lower mediastinum should be considered only as a palliative treatment in patients with high risk of airway obstruction or bleeding (Recommendation B).

## 8. What is the required preoperative care for individuals with MTC and suspected or confirmed pheochromocytoma?

In individuals with pheochromocytoma and MTC, adrenalectomy should precede thyroidectomy. An investigation of pheochromocytoma is mandatory in cases with suspected MEN 2 (72,74,140) (B/B/D) and is also indicated in individuals with apparently sporadic MTC that has not yet been subjected to *RET* molecular testing. Although the occurrence of pheochromocytoma is rather unlikely in these cases, its eventual identification before thyroid surgery is critical, as the complications that arise in undiagnosed cases are severe (72,74) (B).

A diagnosis of pheochromocytoma is established through the identification of excessive catecholamine production by measuring the plasma and/or urine levels of catecholamines and/or metanephrines. The measurement of plasma metanephrines seems to be most useful in cases of hereditary pheochromocytoma, with sensitivity and specificity rates of 99% and 98%, respectively. When a plasma metanephrine measurement is not available, urine levels might be assessed (75,76) (B). CT or MRI of the abdomen should be performed to establish the localization of the pheochromocytoma. CT can identify the localization of hereditary adrenal tumors in 76% of evaluated cases (80) (B).

Adrenalectomy is indicated for the treatment of pheochromocytoma, preferably by laparoscopy after appropriate preoperative preparation and before surgery for MTC or hyperparathyroidism. The resection of the adrenal medulla (adrenal-sparing surgery), in an attempt to preserve the cortex and avoid adrenal insufficiency, should be considered in cases of bilateral pheochromocytoma (73,140) (D). A recent multicenter study involving a large number of patients with MEN 2A-associated pheochromocytoma showed that

the recurrence rate in these cases is low (3%), when performed in specialized centers (141) (B). Preparation for surgery should be individualized according to patient symptomatology. In general, it is recommended the use of alpha-blockers for 1-2 weeks to reduce systemic vasoconstriction (140) (D). Release salt intake and / or saline infusion may also be indicated for the expansion of blood volume (140) (D).

### **Recommendation 8**

A proper investigation is needed to confirm or rule out the presence of pheochromocytoma before thyroidectomy (Recommendation B). In individuals with pheochromocytoma and MTC, adrenal surgery should precede thyroidectomy (Recommendation B).

## **PART III: MTC – FOLLOW-UP**

### **1. Which tests should be performed during the postoperative follow-up of individuals with MTC?**

After surgery, patients should be assessed regarding the presence of residual disease, the localization of metastases, and the identification of progressive disease.

Measurements of the serum levels of calcitonin and CEA are of paramount importance during the postoperative follow-ups of individuals with MTC because these biomarkers might indicate the presence and volume of residual disease (142) (B). However, as their nadirs might occur after several weeks (142,143) (B/C), measurements should be performed at least 2-3 months after surgery.

The specificities of immunometric assays for calcitonin measurement that use 2 monoclonal or 1 monoclonal and 1 polyclonal antibody are 95-100% (40,41) (B/A). To avoid mistakes in the interpretation of results, it should be noted that the absolute values provided by different assays might not be fully comparable. Additionally, the possibility of a hook effect or non-calcitonin-secreting tumors should be considered (false low calcitonin levels) (38,39) (C).

The calcitonin levels might decrease from 24 hours to 4 weeks after surgery, but this could also occur several months later in some cases (142,144,145) (B). Persistently high calcitonin levels might be found in patients with kidney failure or liver cirrhosis and MTC, due to an increase in the hormone half-life caused by decline of the renal or hepatic function, thus requiring

a differential diagnosis with an actual increase in secretion due to a persistent thyroid neoplasm (146,147) (C/D).

In most individuals with sporadic MTC, the calcitonin levels tend to remain high due to residual disease. The likelihood of attaining undetectable calcitonin levels is 83-95% in individuals without lymph node metastases who were subjected to thyroidectomy and neck dissection, but the frequency decreases to 21-30% when neck lymph node metastases are present (9,121,148) (B).

Although also CEA behaves as a marker of MTC, its levels are not always elevated in all patients and do not systematically correlate with the calcitonin levels. The CEA levels might return to normal values after surgery, even in the presence of elevated calcitonin levels; this might be due to the presence of small residual neoplastic foci. In contrast, in individuals with progressive disease, the CEA levels might increase without a corresponding elevation in the calcitonin levels. Increased serum CEA levels are considered to indicate a poor prognosis (149) (C).

### **Recommendation 1**

Measurements of serum calcitonin and CEA should be performed 2-3 months after surgery (Recommendation B). If normal calcitonin values are observed, these measurements should be repeated 6-12 months later. Persistently calcitonin/CEA levels are suggestive of persistent or recurrent disease. In such cases, an investigation must be continued to establish the extent of disease.

### **2. Which factors determine the prognosis of individuals with MTC?**

The likelihood of attaining a cure for MTC mostly depends on the tumor stage at the time of diagnosis and a full surgical resection. The main factors associated with poor prognosis include an older age at diagnosis, the primary tumor size, the presence of local and distant metastases, the presence of somatic mutations, and the calcitonin doubling time (150-152) (B).

The most recent data about the 10-year survival rates for MTC are 95.6%, 75.5% and 40% for patients with tumors confined to the thyroid, local and distant metastases, respectively (12) (B), and are similar to those previously reported (100%, 93%, 71% e 21%, for stages I, II, III e IV, respectively) (153) (B). The sur-

vival rates are higher, the regional control of disease is better, and the occurrence of distant metastases is less frequent in individuals < 45 years of age (154) (B). A tumor size < 0.5 cm correlates with the absence of postoperative clinically or laboratory detectable disease (155) (B).

Stage T4b tumors and/or the presence of lymph node and/or distant metastases are associated with lower remission and survival rates (156) (B). Additionally, the localization of metastases influences the prognosis; for example, bone metastases are associated with a poorer prognosis, compared to metastases in soft tissues (11) (B).

Prophylactic thyroidectomy is indicated in all *RET* mutation carriers, and minimally invasive surgery might be considered in asymptomatic carriers. The type of *RET* mutation correlates with the biological behavior of MTC, and therefore identifying the mutation type might facilitate decision-making with respect to the most adequate age for and the extent of surgery (73,99) (D/C). The use of prophylactic surgery improves the cure rates (100) (B). In individuals with hereditary MTC, a palpable thyroid nodule and lymph node metastases at the time of diagnosis are associated with persistent disease (100) (B).

The calcitonin and CEA levels might remain steadily high for several years or might exhibit rapid and progressive increases. Serial calcitonin and CEA measurements allow a more accurate assessment of the marker levels through calculations of their doubling times (DT); these might be performed with a tool available at the ATA website (<http://www.thyroid.org/thyroid-physicians-professionals/calculators/thyroid-cancer-carcinoma/>). The calcitonin DT has prognostic value in individuals with MTC, as it correlates with the survival and tumor recurrence rates (157) (B). A calcitonin DT calculation requires a minimum of 4 measurements at 6-month intervals. The 5 and 10 – year survival rates are 25% and 8%, respectively, when the DT is < 6 months, and 92% and 37%, respectively, when the DT ranges from 6 months to 2 years. The prognosis was found to be even more favorable in individuals with a DT > 2 years (158) (B).

CEA is a less specific marker of MTC, and the comparison of its DT relative to that of calcitonin revealed diverging results. In one study that compared those markers in a multivariate analysis, both markers behaved as independent predictors of survival; however, the calcitonin DT had a better performance (158) (B).

In contrast, according to another study, the CEA DT had a greater impact on prognosis (159) (B). Those conflicting results notwithstanding, both markers are useful and allow the identification of high-risk individuals. Therefore, when the calcitonin and CEA DTs indicate rapidly progressing disease, a more thorough assessment that includes imaging tests should be considered whenever possible to localize the disease and indicate the proper treatment.

Recently, Tuttle and Ganly (137) (D) formulated a novel approach to the assessment of postoperative MTC progression, consisting of a dynamic risk stratification similar to that developed for well-differentiated thyroid carcinomas (Table 4). An excellent response is defined as undetectable calcitonin levels after adequate surgical treatment, and the likelihood for achieving such responses is greater when the preoperative calcitonin and CEA levels are low, the primary tumor is small, there are no neck metastases, and the disease is in an early stage. Under such conditions, the 5 and 10 – year recurrence rates vary from < 1 – 8.5%, and the survival rates after surgery are 97-99% at 5 years and 95-97% at 10 years (137,160,161) (D/B/B).

**Table 4.** Risk stratification system for evaluation of medullary thyroid carcinoma after initial therapy

Response to initial therapy	Definitions
Excellent	No clinical, imaging or biochemical evidence of disease
Biochemical incomplete	Increased levels of tumor makers (calcitonin, CEA), without structural evidence of the disease
Structural incomplete	Persistent anatomical disease; presence distant metastases
Indeterminate	Unspecific abnormalities on imaging tests, non-normalized tumor marker levels, or no detectable evidence of anatomical disease

Incomplete responses are exhibited by 45-70% of the cases and are characterized by evidence of persistent disease after the initial treatment (73,136,137,161) (D/B/D/B). Additionally, the presence of distant metastases after the initial treatment is considered an incomplete response to the initial treatment. The 5 and 10 – year survival rates of individuals with persistently elevated calcitonin levels are 80-86% and 70%, respectively (153,161-163) (B/A). The cases with unspecific abnormalities on imaging tests, non-normalized tumor marker levels, or no detectable evidence of anatomical and biochemical disease are classified as indeterminate responses (137,164) (D/B).

## Recommendation 2

The main prognostic factors of survival in individuals with MTC are age, the tumor stage at the time of diagnosis, and the calcitonin and CEA doubling times (Recommendation B). In individuals with hereditary MTC, the main prognostic factor of cure and survival is the performance of a prophylactic thyroidectomy following the identification of *RET* gene mutations (Recommendation B).

### 3. Which tests should be performed in individuals with persistently detectable calcitonin levels after initial surgery?

The postoperative serum calcitonin levels determine the strategies used for further assessments. Calcitonin levels < 150 pg/mL correlate with the presence of locoregional disease, but the likelihood of distant metastases is low or they are few in number (68,165) (B).

The initial assessment test is neck US. The rate of local MTC relapse might be as high as 58% (62,68,166) (B/B/D). The sensitivity of neck US for diagnosing locoregional metastases is 97%, compared to 72% with CT and 55% with positron emission tomography (PET)-CT (10) (B). When suspected metastatic lymph nodes are found, a puncture biopsy might help to elucidate the diagnosis, and the sensitivity and specificity of this test increase when calcitonin is measured in the washout fluid (22) (B). CT can identify 100% of the cases with mediastinal lymph node involvement, versus 65% with PET-CT (10) (B).

The presence of distant metastases might be investigated with CT of the neck and/or chest, MRI, bone scintigraphy, and [ $^{18}\text{F}$ ]-fluorodeoxyglucose ( $^{18}\text{F}$ -FDG) PET-CT. The sensitivities of these tests for detecting metastatic disease vary from 50-80%. The likelihood of identifying metastatic disease is lower in individuals with discrete calcitonin elevation (10,167-170) (B), but high when the calcitonin levels exceed 150 pg/mL (165) (B).

The median calcitonin levels in individuals with 1 and 2-4 metastatic sites are 1,510 pg/mL and 18,450 pg/mL, respectively (165) (B). The most frequent sites of distant metastasis are the liver (49%), bones (45%), and lungs (35%) (10) (B). The sensitivities of CT and US for diagnosing liver metastases are similar (90% and 85%, respectively), but lower than that of MRI (100%) (10) (B). Bone scintigraphy is indicated for investigating low-mechanical risk lesions (ribs, sternum, clavicles, and skull), and axial skeleton MRI is indicated for high-

mechanical risk lesions (spine, pelvic bones, and long bones). CT is the most accurate method for diagnosing lung metastases. Therefore, the best test combination for detecting distant metastases includes chest CT, liver MRI, and bone scintigraphy and/or axial skeleton MRI (10) (B).

Experiences with the use of [ $^{18}\text{F}$ ]-dihydroxyphenylalanine ( $^{18}\text{F}$ -DOPA) PET in metastatic MTC remain limited. This method has a sensitivity rate of 63% and might be used to investigate metastases in cases of slowly progressive MTC (168,171) (B). Metaiodobenzylguanidine (MIBG) scintigraphy might be useful in some cases, while somatostatin receptor scintigraphy is an additional option when the serum calcitonin levels are > 800 pg/mL (172) (B).

In individuals with high calcitonin levels and negative imaging tests,  $^{18}\text{F}$ -FDG PET-CT had sensitivity, specificity, and diagnostic accuracy rates of 88%, 84.6%, and 87%, respectively, for the detection of occult recurrences of MTC (173) (B). In a comparison of  $^{18}\text{F}$ -FDG,  $^{18}\text{F}$ -DOPA, and  $^{68}\text{Ga}$ -somatostatin analogue PET-CT in individuals with recurrent MTC, the metastatic lesion detection rates were 28%, 85%, and 20%, respectively. According to those data,  $^{18}\text{F}$ -DOPA PET-CT seems to be the most useful method for detecting MTC recurrences in individuals with elevated serum calcitonin levels (174) (B). However, other studies showed no significant differences between PET  $^{18}\text{F}$ -DOPA and  $^{18}\text{F}$ -FDG in the same population (175) (B).

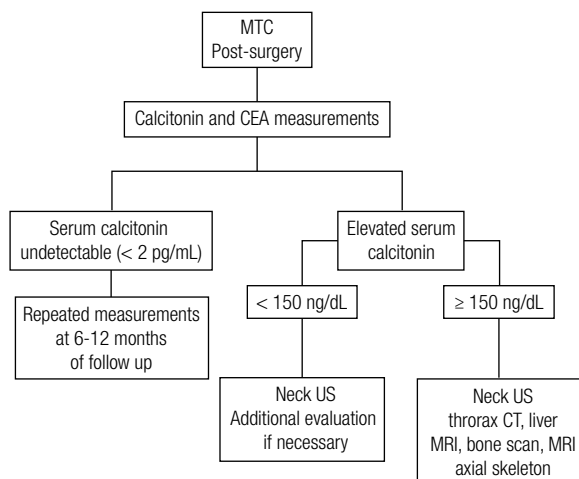
## Recommendation 3 (Flowchart 2)

Basal calcitonin levels < 150 pg/mL are associated with the presence of locoregional disease, and neck US should be the first test used in the assessment (Recommendation B). The likelihood of detecting distant metastases is higher among patients with calcitonin levels > 150 pg/mL. In such cases, chest CT, abdominal MRI, and bone scintigraphy should be performed to establish the presence of mediastinal and lung, liver, and bone metastases, respectively (Recommendation B).

### 4. Which tests should be performed during the follow-up of individuals with undetectable calcitonin levels after surgery?

Serum calcitonin is the most sensitive marker of residual MTC after surgery. According to some studies, the calcitonin levels are below the threshold of detection in 100% of the individuals subjected to total





**Flowchart 2.** Evaluation of patients with medullary thyroid carcinoma post-surgery.

thyroidectomy (176) (B). The likelihood of residual/recurrent disease in individuals with undetectable basal and post-pentagastrin stimulation calcitonin levels after surgery was reported to be approximately 3% (125) (B).

The likelihood that calcitonin levels will become undetectable after total thyroidectomy is 95% in individuals with thyroid gland-restricted disease. The presence of neck metastases reduces the likelihood that calcitonin will return to normal values to 30% (9). Although the average time for the recurrence of MTC is  $3.2 \pm 2.2$  years, the calcitonin levels should be measured every 6-12 months for a still-undefined period of time, including after they have become undetectable after surgery, due to the risk of disease relapse (125) (B).

It is worth observing that a few cases of individuals with advanced MTC and normal serum calcitonin levels were reported (39,177) (C). Those patients' follow-ups should include imaging modalities. Measurements of the calcitonin levels in the FNAB washout fluid might facilitate the proper diagnoses of suspected MTC metastatic lesions (22,23) (B/C).

#### Recommendation 4

Measurements of serum calcitonin levels should be performed every 6-12 months for a still-undefined period of time in individuals with undetectable levels after surgery due to the risk of disease relapse (Recommendation B). Measurements of the calcitonin level in the FNAB washout fluid might facilitate the diagnoses of suspected lesions (Recommendation B).

#### 5. When is the pentagastrin or calcium stimulation test for calcitonin indicated in patients already subjected to surgery?

In some individuals with undetectable basal calcitonin levels, pentagastrin and/or calcium stimulation might increase these levels, thus indicating the presence of residual disease. However, the localization of residual disease is very difficult to establish with imaging methods in the vast majority of such cases (134,176,178) (B/B/C). Further disadvantages associated with these stimulation tests are their costs, side effects, and the unavailability of pentagastrin in Brazil.

#### Recommendation 5

The pentagastrin/calcium stimulation test is not indicated for the follow-up of individuals with undetectable basal serum calcitonin, as positive results denote residual diseases that are difficult to locate with imaging methods (Recommendation B).

#### 6. What should comprise the management of patients with persistently detectable calcitonin levels after primary surgery?

Curative reoperation (to achieve undetectable serum calcitonin levels) is indicated in individuals who exhibit evidence of persistent disease due to an incomplete primary surgery or a disease recurrence in the neck. The presence of inoperable distant metastases should be ruled out before a cervical reoperation is considered. Surgery might also have palliative indications in cases with the risk of compression or invasion of the trachea or the great vessels (179) (D). Expectant management, including periodical clinical and laboratory assessments, is indicated in cases of indolent disease that have already been subjected to appropriate surgical treatments (179) (D). Follow-up measurements of serum calcitonin in individuals with MTC might determine the later management.

Discrete increases in the calcitonin levels ( $< 150$  pg/mL) at 2-3 months after surgery are associated with locoregional disease or small distant metastases in most cases (68,165) (B). When residual or recurrent disease is detected in the neck, surgical reintervention should be considered. The rates of calcitonin normalization after cervical reoperation vary from 16-38% (180-184) (B). A retrospective study found that reoperation allowed the identification of residual disease in the lateral lymph nodes in 64% of cases, in the central compartment in 22%, and in the anterior medi-

astinum in 14% of cases. The serum calcitonin levels returned to normal in only 6% of the investigated individuals; however, the remainder of the sample exhibited 50% reductions or stabilization of the calcitonin levels (181) (B). Another study followed up individuals who were subjected to reoperation for MTC over a period of 8-10 years and found calcitonin levels < 10 pg/mL in 26% of the participants and < 100 pg/mL in an additional 20.4% of patients. Disease could not be detected with imaging methods in any of those individuals (184) (B).

Although reoperation might reduce the disease progression in selected individuals, a biological cure of MTC is seldom achieved in such cases. For that reason, the surgical approach to recurrent or persistent MTC in individuals with no or minimal distant metastases should include dissection of the affected central (level VI) or lateral (levels IIA, III, IV, and V) compartments. Expectant management is recommended for cases in which the anatomical localization of the metastases cannot be established (179).

Significantly elevated calcitonin levels (> 150 pg/mL) at 2-3 months after surgery are usually associated with the presence of distant metastases, and the higher the calcitonin level, the higher the likelihood of identifying the lesion localization (185) (B). As a rule, the management of individuals with calcitonin levels > 150 pg/mL is similar to that of patients with lower levels (186) (D).

The therapeutic strategy for individuals with locoregional and distant metastases should be decided on an individual basis, while considering the indolent course of MTC and the morbidity associated with the available treatments. The presence of neck lymph nodes < 1 cm and asymptomatic distant metastases does not suggest a need for intervention, as treatment has not proven beneficial in such cases. Possible therapeutic options include surgery, percutaneous interventions, liver metastasis embolization, radiotherapy, and tyrosine-kinase inhibitors (187) (D). It is worth observing that the likelihood of a cure in individuals with distant metastases is minimal. The relative risks and benefits of any procedure should be carefully assessed when deciding whether palliative therapy or watchful waiting is indicated.

### Recommendation 6

Serum calcitonin is the most relevant biomarker for the follow up individuals with MTC (Recommendation B). Discrete increases in the calcitonin levels (< 150 pg/mL) usually denote the presence of locoregional disease

(Recommendation B). More substantial elevations (> 150 pg/mL) are suggestive of distant metastases (Recommendation B). The best methods for investigating metastases are US for the neck, CT for the chest, MRI for the liver, and bone scintigraphy and/or axial skeleton MRI for the bones (Recommendation B).

A new surgical procedure should be considered in presence of residual or recurrent local disease (Recommendation B). In patients with distant metastases, the treatment strategy should be individualized, taking into consideration the indolent course of CMT and the morbidity associated with available therapies (Recommendation D).

## 7. What is the appropriate management for individuals with increased calcitonin levels and negative imaging tests?

Individuals with detectable calcitonin levels after surgery should be assessed with imaging methods to locate the disease site. When imaging tests fail to identify the disease foci, the patients should be subjected to periodical assessments at intervals determined by the calcitonin and CEA DT, as these are markers of disease progression (158,165) (B). To calculate the DTs, the serum calcitonin and CEA levels should be measured every 6 months, and the ideal interval for assessments of individuals with MTC corresponds to one-fourth of the DT or each year, whichever is shorter.

### Recommendation 7

Individuals with elevated serum calcitonin levels and negative imaging tests should be assessed at least every 6 months, and these assessments should include measurements of the calcitonin and CEA levels to calculate their DTs (Recommendation B).

## 8. What should comprise the treatment of individuals with MTC and distant metastases?

The following questions should be considered during decision-making, with respect to the best management of individuals with metastatic MTC:

- Is the patient symptomatic or asymptomatic?
- Where are the metastases located?
- Are there lesions that require intervention due to imminent risk or associated symptoms (*e.g.*, brain lesions, painful bone lesions or those with a risk of fracture, or chest pain and the risk of bronchial obstruction)?

- Is the locoregional disease controlled?
- What is the speed of metastatic disease progression?

The treatment of distant metastases is indicated in cases associated with an imminent risk of serious complications such as brain metastases, lesions that cause spinal cord compression or airway affection, hormone-secreting metastases, or bone metastases that exhibit an active or imminent risk of fracture. Expectant management might be indicated in asymptomatic individuals who exhibit small indolent metastases. Patients with rapidly progressive disease, as evidenced by imaging or laboratory testing, are candidates for systemic novel drug treatment.

The disease progression speed might be assessed from the calcitonin and CEA DTs or imaging results that have been interpreted according to the Response Evaluation Criteria In Solid Tumors (RECIST), in which increases > 20% in the sum of the lesions' diameters are classified as progressive disease (158,165,188) (B).

#### **Recommendation 8**

Systemic treatment should be considered for symptomatic individuals and/or those with documented significant disease progression (according to radiological methods and/or a calcitonin or CEA DT < 6 months) (Recommendation B).

### **9. What should comprise the treatment of individuals with hormone-secreting metastases?**

The ectopic production of corticotropin-releasing hormone (CRH) and adrenocorticotrophic hormone (ACTH) and the secretion of VIP, insulin, and glucagon were described in individuals with MTC (52,53,189,190) (B/B/D/C).

Diarrhea might appear due to increased intestinal motility (191) (C) or the hypersecretion of calcitonin and/or VIP (52,192) (B/C). According to recommendations, treatment should initially include ant motility agents (loperamide or codeine). Further options for unsuccessful cases include the use of somatostatin analogues (193-195) (B) and the selective resection or arterial chemoembolization of liver metastases to reduce the hypercalcitonemia caused by those lesions (196,197) (B/C).

MTC comprises 2-6% of ectopic Cushing's syndrome cases (198,199) (B/C), and treatment might

include surgery or chemoembolization for liver metastases. Additionally, adrenolytic drugs (ketoconazole, mitotane, or metyrapone) might be used, while bilateral adrenalectomy is indicated in uncontrolled cases (198-200) (B/C/C). Recently, it has been reported a sorafenib-induced reduction of cortisol and ACTH levels, associated with dramatic clinical improvement, in a patient with advanced MTC and ectopic ACTH syndrome (201) (C).

#### **Recommendation 9**

Advanced MTC metastatic disease might be attended by systemic hormonal changes secondary to the increased calcitonin levels and/or the ectopic production of some specific hormones. Treatment should be planned on an individual basis according to the clinical manifestations of the existing dysfunction (Recommendation B).

### **10. What are the indications for chemotherapy and/or radiotherapy in the management of individuals with metastatic MTC?**

#### **Radiotherapy**

The role of radiotherapy in the treatment of MTC is rather limited (202-204) (B/B/D). In individuals at a high risk of local recurrence (locally invasive tumors, microscopic residual disease, and neck lymph node involvement), radiotherapy was shown to reduce the local recurrence rate in 86% of patients at a 10 – year follow-up (205) (B).

The indication for radiotherapy in systemic metastatic disease is restricted to the palliative treatment of painful bone metastases or those at risk of fracture, as described for bone metastases secondary to other types of tumors (206) (B), and to the treatment of hemoptysis or airway obstruction in individuals with extensive mediastinal and/or lung involvement (204,207) (D/C).

#### **Systemic chemotherapy**

The results of studies of single or combined chemotherapy agents have not been satisfactory. No phase III studies with large numbers of patients have been conducted. A combination of doxorubicin, dacarbazine, and streptozocin induced partial responses in 15% of a sample of individuals with MTC (208,209) (B). Additionally, the results were limited in studies that used cyclophosphamide, vincristine, cisplatin, and bleomycin (208,210-212) (B). Therefore, as conventional

chemotherapy has not been effective, it is exclusively recommended for selected individuals with rapidly progressive metastatic disease.

### Recommendation 10

Radiotherapy should be considered for local disease control (Recommendation B), the palliative treatment of painful bone metastases or those at risk of fracture (Recommendation B), and for the treatment of hemoptysis or airway obstruction in individuals with extensive mediastinal and/or lung involvement (Recommendation D). The effects of conventional chemotherapy are limited, and thus it should only be considered in selected cases (significant progression of the tumor mass) (Recommendation B).

## 11. What new drugs are available for the management of individuals with metastatic MTC?

In recent years, cumulative knowledge about the molecular mechanisms and intracellular signaling pathways involved in the pathogenesis of neoplasms such as MTC has allowed the development of novel targeted therapies.

Uncontrolled tyrosine-kinase receptor activation is one of the main mechanisms involved in cancer development and progression (213,214) (D). Vascular endothelial growth factor (VEGF) performs critical functions in physiological and pathological angiogenesis, as well as in lymphangiogenesis (215) (D). Inhibition of VEGF action by blocking its receptors represents a novel approach to anticancer therapy (213,216,217) (B/D/D). Recent studies conducted with novel drugs that inhibit VEGF and its receptors in thyroid tumors yielded satisfactory results (218). In addition to VEGF, MTC pathogenesis also involves the presence of somatic or germline mutations in the *RET* proto-oncogene. *RET* comprises 21 exons and encodes a tyrosine-kinase receptor that is expressed in neural crest-derived cells (2,4) (D). Therefore, the use of drugs with anti-tyrosine kinase activities represents a novel therapeutic option for MTC management.

The initial results of clinical studies that used novel drugs such as tyrosine-kinase inhibitors to treat MTC were published in 2008 ([www.clinicaltrials.gov](http://www.clinicaltrials.gov)). Clinical trials that employ such agents use RECIST to assess the responses to treatment as follows: complete response (disappearance of all target lesions), partial response (at least a 30% reduction in the sum of the longest target lesion diameters), progressive disease (at least a 20% increase in the sum of the longest target

lesion diameters), and stable disease (neither sufficient shrinkage to qualify as a partial response nor sufficient increase to qualify as progressive disease) (219) (D).

Overall, the partial response rate is approximately 30%, whereas stable disease is the most commonly achieved outcome. Two tyrosine-kinase inhibitors have been approved by the FDA (U. S. Food and Drug Administration) to treat rapidly progressive metastatic MTC, specifically vandetanib and cabozantinib (<http://www.fda.gov/>); however, only the former has been approved in Brazil.

Vandetanib is an oral agent that selectively targets the RET receptor, VEGF receptors (VEGFR), and the epidermal growth factor receptor (EGFR) (220,221) (D/D). A phase III clinical trial assessed the efficacy of vandetanib in 331 individuals with metastatic MTC who were randomized to receive vandetanib (300 mg) or a placebo. The results showed a significant increase in progression-free survival in the vandetanib-treated group, compared to the placebo group (30.2 vs. 19.2 months, respectively; hazard risk (HR) = 0.46, 95% confidence interval (CI) = 0.31-0.69). The rate of mortality at 2 – year follow-up was 15% (222,223) (B). Another Phase II clinical study evaluated 19 patients using a reduced dose of vandetanib (100 mg/d). In this small group of patients, vandetanib used was associated with decreased progression-free survival with fewer adverse effects (224) (B). This same dose (100 mg/d) was also successfully used in children with MEN 2B (225) (B). A recent systematic review on the use of vandetanib in MTC indicates the medication in patients with loco regional disease unresectable, symptomatic distant metastatic disease and disseminated metastatic disease (226) (B). Preclinical studies have indicated that *RET* codon 804 mutations (V804L, V804M) induce resistance to vandetanib (227) (B).

Cabozantinib (XL184) is a powerful inhibitor of the hepatocyte growth factor receptor (MET), VEGFR2, and RET. A multicenter randomized study of 300 individuals with documented MTC progression during the previous 14 months found a significant increase in progression-free survival in the cabozantinib-treated group (140 mg/d), compared to the placebo group (11.2 vs. 4.0 months, respectively; RR = 0.28, 95% CI = 0.19-0.40,  $p < 0.0001$ ) (228,229) (B).

The effect of vandetanib or cabozantinib on the survival rate of MTC patients remains unknown, but interim analyses of the overall survival did not show a difference between the study drug-treated and placebo groups (222,228) (B/B).



Table 5 summarizes the main available drugs, as well as their corresponding targets and outcomes (222,228-242) (B/B/B/C/B/C/B/C/C/B/C/B/C/C/B/C).

The most common side effects of the tyrosine-kinase inhibitors include diarrhea, nausea, skin rash, hypertension, and fatigue (243) (D). Additionally adverse events include neutropenia, leukopenia, hand-foot syndrome, stomatitis, proteinuria, abdominal pain, face swelling, thrombocytopenia and QTc prolongation – it is suggested that patients be monitored by conducting periodic electrocardiograms. The levo-thyroxine dose for replacement therapy usually needs to be increased. As a rule, the side effects of these inhibitors are well tolerated, and toxicity is controllable in most individuals. Nevertheless, severe adverse events have also been reported, including aspiration pneumonia, respiratory failure, septicemia, acute heart failure, and arrhythmia (222,231,236,244-248) (B/B/B/B/C/C/B/C).

Other therapeutic approaches for metastatic MTC are currently being investigated, including anti-CEA antibody-targeted radiotherapy, gene therapy, and other radiopharmaceuticals. Currently, such medications are only used in research protocols (249,250) (D/D).

### Recommendation 11

The results reported to date indicate that tyrosine-kinase inhibitors represent a relevant therapeutic option for the treatment of locally advanced or metastatic MTC (Recommendation A). Nevertheless, the corresponding data regarding long-term survival are not yet available. As a function of their side effect profiles,

caution is required when identifying patients who might benefit from these drugs (Recommendation D). Currently, two tyrosine-kinase inhibitors, vandetanib and cabozantinib, have been approved by the FDA for the treatment of rapidly progressive metastatic MTC, while only the former has been approved in Brazil.

## 12. What should comprise the management of distant metastases?

### Bone metastases

The incidence of bone metastases in thyroid carcinoma is approximately 5.0%, with median survival time after metastasis of  $5.3 \pm 1.3$  years; patients with hypercalcemia have lower survival (251) (B). The term skeletal-related event (SRE) is used to quantify the morbidity associated with bone metastases. The clinical determinants that compose the SRE include spinal cord compression, pathologic fractures, and the need for external radiotherapy or surgery to afford pain relief or control tumor-related hypercalcemia. Imaging exams are essential to determine the location and extent of the bone lesions; skeletal CT or MRI and FDG-PET/CT are the best currently available methods (10,252) (B/D).

The management of bone metastases depends on their number, localization and associated symptoms. If the disease is localized, surgical resection significantly improves patient prognosis and survival, and may be curative (253) (D). Spinal cord compression indicates emergency surgery and the use of systemic corticosteroids. Active or imminent fractures in body-supporting bones require surgical treatment. Radiotherapy is useful

**Table 5.** Tyrosine kinase inhibitors for treatment of medullary thyroid carcinoma

Drugs approved	Targets	Patients (n)	Dose <sup>a</sup>	PFS drug vs. Placebo (months)	Hazard Ratio <sup>b</sup>	References
Vandetanib (ZD6474)	VEGFR-1, VEGFR-2, VEGFR-3, RET, EGFR	331	300 mg	30.5 vs. 19.3	0.46	222
Carbozantinib (XL 184)	VEGFR-2, RET, MET	330	140 mg	11.2 vs. 4.0	0.28	228,229
Investigational drugs	Targets	Patients (n)	Dose <sup>a</sup>	Partial response (%)	Stable Disease <sup>c</sup> (%)	References
Montesinib (AMG 706)	VEGFR-1, VEGFR-2, VEGFR-3, C-KIT, RET, PDGFR	91	125 mg	2	48	230,231
Sorafenib (BAY 43-9006)	VEGFR-2, VEGFR-3, c-Kit, RET	21	400 mg	6	50	232,233
Sunitinib (SU 11248)	VEGFR-1, VEGFR-2, VEGFR-3, RET, c-Kit	7	37,5 mg	28	46	234,235,236
Axitinib (AG-013736)	VEGFR-1, VEGFR-2, VEGFR-3, c-Kit	11	5 mg	18	27	237,238
Imatinib (STI571)	RET, c-Kit, PDGFR	9	600 mg	0	55	239,240
		15	600 mg	0	27	241

a. The drugs were used once daily, except for the treatment with sorafenib; axitinib were administered twice daily.

b / c. Results are expressed as hazard ratio of objective response (b; drug vs. placebo) and rate of disease control (c).



for painful bone metastases, when surgery is contraindicated, or if resection was incomplete (252,253) (B/D).

The indication of bisphosphonates given per the intravenous route for the control of bone metastasis-related pain has been well established in other solid and hematological malignancies (254-256) (B). One recent study showed that zoledronic acid could effectively reduce skeletal-related events, including bone fractures, spinal cord compression, and hypercalcemia in individuals with differentiated thyroid carcinoma and bone metastases (257) (B).

### **Liver metastases**

The liver is the most frequent site of MTC metastases. The overall survival of patients with liver metastases who underwent radiofrequency ablation was 6 years (258) (B). The lesions are usually multiple and disseminated (259) (B). Treatment should be considered for large or progressive lesions, as well as for those associated with the occurrence of diarrhea and/or pain. The available options for treatment include chemoembolization (40-60% achieve partial response/disease stabilization) and tyrosine kinase inhibitor therapy for progressive disease (197,243) (C/D).

### **Lung and mediastinal metastases**

Mediastinal lymph node involvement is frequent in advanced MTC, and its presence usually indicates an incurable disease. Therefore, when the lymph node affection is stable and not associated with clinical manifestations, expectant management is indicated, and the patients should be monitored with imaging methods and measurements of the calcitonin/CEA levels (188) (B).

When airway compression or bleeding occur, surgery, radiotherapy, or radiofrequency ablation should be considered for the management of lung and/or mediastinal metastases (260) (D).

### **Brain metastases**

Individuals with isolated brain metastases are candidates for surgical resection. Radiotherapy might be considered if surgery is not possible (261-263) (B).

### **Recommendation 12**

The currently available treatments for individuals with distant metastases of MTC, which include surgery, chemotherapy, radiotherapy, and tyrosine-kinase inhibitors, are palliative and might be indicated in selected

cases to control the disease progression or to improve the patient's quality of life.

### **13. When are radioactive iodine treatment and/or levothyroxine suppressive therapy indicated in individuals with MTC?**

Unlike differentiated thyroid cancer, which originates in the follicular cells, MTC originates in the C or parafollicular cells; therefore, radioactive iodine treatment and/or levothyroxine suppressive therapy are not indicated for MTC management (73) (D). In recent studies, the use of radioactive iodine did not show any effects relevant to the postoperative management of individuals with MTC (264) (B).

### **Recommendation 13**

Neither radioactive iodine treatment (Recommendation B) nor levothyroxine suppressive therapy is indicated in MTC (Recommendation B).

## **SUMMARY OF RECOMMENDATIONS**

To summarize, the main recommendations for the diagnostic assessment, treatment, and follow-up of MTC are as follows:

### **PART I: MTC – DIAGNOSIS**

1. A thyroid nodule is the most common clinical manifestation of MTC. MTC should be specifically suspected in individuals with family history of MTC, *RET* mutations or associations with pheochromocytoma, hyperparathyroidism, cutaneous lichen amyloidosis, Marfanoid habitus, or mucosal neuromas.
2. FNAB should be included in assessments of thyroid nodules suspected of MTC. The differential diagnosis might be facilitated by the use of additional techniques such as the measurement of calcitonin in the FNAB washout fluid and immunocytochemistry.
3. MTC screening via a serum calcitonin measurement in individuals with thyroid nodules remains controversial. Because of problems with reference value standardization and its doubtful cost-effectiveness, the measurement of serum calcitonin is not indicated in the routine investigation of thyroid nodules.

4. The preoperative calcitonin levels correlate with the tumor size and the presence of local or distant metastases. The individuals with suspected MTC and calcitonin levels > 150 ng/mL must be investigated for the presence of locoregional and distant metastases by imaging tests (**Flow-chart 1**).
5. Neck US is indicated in all individuals with suspected MTC (Recommendation B). In addition to identifying characteristics suggestive of malignancy in the thyroid nodules and allowing the performance of US-guided FNAB, US is the most sensitive test for detecting neck metastases and thus contributes to therapeutic planning.
6. In individuals with neck metastases and/or calcitonin levels > 400 mg/mL, the presence of distant metastases should be investigated before surgery. The presence of pheochromocytoma must be investigated by the measurement of plasma fractionated metanephrines or urine metanephrine levels, if not available the blood measurement. The presence of hyperparathyroidism might be investigated through a serum calcium level measurement after adjusting for the albumin concentration.
7. A molecular assessment is indicated for all individuals with C cell hyperplasia, (familial or apparently sporadic) MTC, and/or MEN 2. The molecular diagnosis might guide the choice of therapeutic procedures might guide the choice of therapeutic procedures and could consequently change the natural course of disease, indicate genetic counseling, and help to establish the disease prognosis.
8. All first-degree relatives of individuals with MTC and germline RET mutations should be subjected to molecular screening.
9. The knowledge of the type of RET mutation provides relevant information about the clinical presentation of MEN 2 and the biological behaviors of the associated neoplasms
10. The presence of CLA or Hirschsprung's disease indicates the suspected occurrence of hereditary MTC and therefore the need to perform a RET molecular assessment.
11. In asymptomatic cases or in the absence of adrenal masses, urine and/or fractionated plasma metanephrines measurements should begin

at 8 years of age in individuals with MEN 2B or 2A who carry mutations in codons 630 or 634, and after 20 years of age in the remainder of individuals with MEN 2A. Hyperparathyroidism screening must be performed annually by measuring the total calcium and albumin levels, starting at 8 years age in carriers of mutations in RET codons 630 and 634 and at 20 years of age in the remainder of individuals with MEN 2A.

## PART II. MTC – SURGICAL TREATMENT

1. The surgical treatment recommended for individuals with MTC limited to the thyroid gland is total thyroidectomy and elective dissection of the central compartment.
2. In cases with locoregional disease, total thyroidectomy with central compartment lymph node dissection is indicated (B). Lateral lymph node dissection is indicated when metastases are present or suspected (B). Less aggressive surgery is indicated in cases with advanced local disease and/or distant metastases to achieve local disease control while preserving the patient's voice, deglutition, and parathyroid function.
3. In cases with a postoperative MTC diagnosis, completion thyroidectomy and prophylactic central dissection are indicated. Watchful waiting might apply to selected individuals.
4. In cases without preoperative hyperparathyroidism, the "*in situ*" preservation of the parathyroid glands is always desirable. When the glands are accidentally removed or there is a risk of devascularization, the glands should be autografted into the sternocleidomastoid muscle. In cases with hyperparathyroidism, MEN 2A, or prior surgery for MTC, the affected parathyroid gland should be identified with imaging methods to decide upon a subtotal or total parathyroidectomy, followed by a forearm autograft.
5. The surgical approach in asymptomatic carriers *RET* proto-oncogene mutations should consider the risk stratification according to the affected codon, as follows:
  - **Group D (MEN 2B):** total thyroidectomy within the first year of life. In cases with evidence of lymph node metastases, nodule sizes >

5 mm, or serum calcitonin levels > 40 pg/mL, central compartment dissection is also indicated. Individuals older than 1 year of age are indicated for (elective) “prophylactic” central dissection.

– **Group C:** total thyroidectomy before 5 years of age.

– **Groups A and B:** total thyroidectomy after 5 years of age in the absence of evidence of MTC (normal serum calcitonin levels and neck US). Contrariwise, surgery should be performed before 5 years of age.

Individuals in groups A, B, and C should be subjected to central compartment dissection when there is clinical and/or imaging evidence of metastatic disease, the nodule size is  $\geq 5$  mm, and the serum calcitonin level is > 40 pg/mL (D).

6. Individuals with advanced local disease or distant metastases should be subjected to less aggressive surgeries aimed at achieving local disease control while preserving the patient’s voice, deglutition, and parathyroid functions, as well as avoiding hemorrhagic complications due to the invasion of vascular structures (D).
7. Elective superior mediastinal dissection is usually performed during surgery for MTC. The dissection of the lower mediastinum should be considered only as a palliative treatment in patients with high risk of airway obstruction or bleeding.
8. In individuals with pheochromocytoma and MTC, adrenalectomy should precede thyroidectomy. Therefore, the presence of pheochromocytoma should be established or ruled out before thyroid surgery is performed.

### PART III. MTC – FOLLOW-UP

1. Serum calcitonin and CEA levels should be measured 2-3 months after surgery. Once the calcitonin levels normalize, this measurement should be repeated after 6-12 months. Persistently elevated calcitonin/CEA levels are suggestive of disease persistence or recurrence and indicate the need for further investigation to establish the disease extension.
2. The main prognostic factors of survival in individuals with MTC are age, the tumor stage

at the time of diagnosis, and the calcitonin and CEA doubling times. In individuals with hereditary MTC, the main prognostic factor of cure and survival is the performance of a prophylactic thyroidectomy following the identification of RET gene mutations.

3. Basal calcitonin levels < 150 pg/mL are associated with the presence of locoregional disease, and neck US should be the first test used in the assessment. The likelihood of detecting distant metastases is higher among patients with calcitonin levels > 150 pg/mL. In such cases, chest CT, abdominal MRI, and bone scintigraphy should be performed to establish the presence of mediastinal and lung, liver, and bone metastases, respectively.
4. Measurements of serum calcitonin levels should be performed every 6-12 months for a still-undefined period of time in individuals with undetectable levels after surgery due to the risk of disease relapse. Measurements of the calcitonin level in the FNAB washout fluid might facilitate the diagnoses of suspected lesions.
5. The pentagastrin/calcium stimulation test is not indicated for the follow-up of individuals with undetectable basal serum calcitonin, as positive results denote residual diseases that are difficult to locate with imaging methods.
6. Serum calcitonin is the most relevant biomarker for the follow up individuals with MTC. Discrete increases in the calcitonin levels (< 150 pg/mL) usually denote the presence of locoregional disease. More substantial elevations (> 150 pg/mL) are suggestive of distant metastases. The best methods for investigating metastases are US for the neck, CT for the chest, MRI for the liver, and bone scintigraphy and/or axial skeleton MRI for the bones.
7. Individuals with elevated serum calcitonin levels and negative imaging tests should be assessed at least every 6 months, and these assessments should include measurements of the calcitonin and CEA levels to calculate their DTs.
8. Systemic treatment should be considered for symptomatic individuals and/or those with documented significant disease progression (according to radiological methods and/or a calcitonin or CEA DT < 6 months).

9. Advanced MTC metastatic disease might be attended by systemic hormonal changes secondary to the increased calcitonin levels and/or the ectopic production of some specific hormones. Treatment should be planned on an individual basis according to the clinical manifestations of the existing dysfunction.
10. Radiotherapy should be considered for local disease control, the palliative treatment of painful bone metastases or those at risk of fracture, and for the treatment of hemoptysis or airway obstruction in individuals with extensive mediastinal and/or lung involvement. The effects of conventional chemotherapy are limited, and thus it should only be considered in selected cases (significant progression of the tumor mass).
11. The results reported to date indicate that tyrosine-kinase inhibitors represent a relevant therapeutic option for the treatment of locally advanced or metastatic MTC (Recommendation A). Nevertheless, the corresponding data regarding long-term survival are not yet available. As a function of their side effect profiles, caution is required when identifying patients who might benefit from these drugs (Recommendation D). Currently, two tyrosine-kinase inhibitors, vandetanib and cabozantinib, have been approved by the FDA for the treatment of rapidly progressive metastatic MTC, while only the former has been approved in Brazil. Advanced metastatic MTC might be associated with systemic hormonal changes consequent to increased calcitonin levels and/or the ectopic production of specific hormones. Treatment should be established on an individual basis according to the clinical manifestations of the existing dysfunction.
12. The currently available treatments for individuals with distant metastases of MTC, which include surgery, chemotherapy, radiotherapy, and tyrosine-kinase inhibitors, are palliative and might be indicated in selected cases to control the disease progression or to improve the patient's quality of life.
13. Neither radioactive iodine treatment nor levothyroxine suppressive therapy is indicated in MTC.

Acknowledgments: we would like to thank Dr. Carmen Cabanelas Pazos de Moura, President of the Thyroid Department of the Brazilian Society of Endocrinology & Metabolism, for her sup-

port of this work. We are also grateful to Dr. Nathalia Carvalho de Andrada [*Projeto Diretrizes da Associação Médica Brasileira, Conselho Federal de Medicina (AMB/CFM)*] for reviewing the strength of evidence and the degree of recommendations of this consensus.

Disclosure: Debora R. Siqueira, Marco A. V. Kulcsar, Alfio J. Tincani, and Gláucia M. F. S. Mazeto have nothing to declare. Ana Luiza Maia and Lea M. Z. Maciel served as consultant/advisor for AstraZeneca and Bayer within the past 2 years.

## REFERENCES

1. Davies L, Welch HG. Increasing incidence of thyroid cancer in the United States, 1973-2002. *JAMA*. 2006;295:2164-7.
2. Punaes MK, Rocha AP, Gross JL, Maia AL. Medullary thyroid carcinoma: clinical and oncological features and treatment. *Arq Bras Endocrinol Metabol*. 2004;48:137-46.
3. Wells SA Jr, Pacini F, Robinson BG, Santoro M. Multiple endocrine neoplasia type 2 and familial medullary thyroid carcinoma: an update. *J Clin Endocrinol Metab*. 2013;98:3149-64.
4. Eng C, Smith DP, Mulligan LM, Nagai MA, Healey CS, Ponder MA, et al. Point mutation within the tyrosine kinase domain of the RET proto-oncogene in multiple endocrine neoplasia type 2B and related sporadic tumours. *Hum Mol Genet*. 1994;3:237-41.
5. Siqueira DR, Romitti M, da Rocha AP, Ceolin L, Meotti C, Estivallet A, et al. The RET polymorphic allele S836S is associated with early metastatic disease in patients with hereditary or sporadic medullary thyroid carcinoma. *Endocr Relat Cancer*. 2010;17:953-63.
6. Cohen R, Campos JM, Salaun C, Heshmati HM, Kraimps JL, Proye C, et al. Preoperative calcitonin levels are predictive of tumor size and postoperative calcitonin normalization in medullary thyroid carcinoma. Groupe d'Etudes des Tumeurs a Calcitonine (GETC). *J Clin Endocrinol Metab*. 2000;85:919-22.
7. Machens A, Schneyer U, Holzhausen HJ, Dralle H. Prospects of remission in medullary thyroid carcinoma according to basal calcitonin level. *J Clin Endocrinol Metab*. 2005;90:2029-34.
8. Moley JF, DeBenedetti MK. Patterns of nodal metastases in palpable medullary thyroid carcinoma: recommendations for extent of node dissection. *Ann Surg*. 1999;229:880-7.
9. Scollo C, Baudin E, Travagli JP, Caillou B, Bellon N, Leboulleux S, et al. Rationale for central and bilateral lymph node dissection in sporadic and hereditary medullary thyroid cancer. *J Clin Endocrinol Metab*. 2003;88:2070-5.
10. Giraudet AL, Vanel D, Leboulleux S, Auperin A, Dromain C, Chami L, et al. Imaging medullary thyroid carcinoma with persistent elevated calcitonin levels. *J Clin Endocrinol Metab*. 2007;92:4185-90.
11. Girelli ME, Nacamulli D, Pelizzo MR, De Vido D, Mian C, Piccolo M, et al. Medullary thyroid carcinoma: clinical features and long-term follow-up of seventy-eight patients treated between 1969 and 1986. *Thyroid*. 1998;8:517-23.
12. Roman S, Lin R, Sosa JA. Prognosis of medullary thyroid carcinoma: demographic, clinical, and pathologic predictors of survival in 1252 cases. *Cancer*. 2006;107:2134-42.
13. Levels of Evidence and Grades of Recommendations – Oxford Centre for Evidence-Based Medicine. Available at: <http://www.cebm.net/index.aspx?o=1025>. Accessed on: Oct 1, 2014.
14. Rosário PW, Ward LS, Carvalho GA, Graf H, Maciel RM, Maciel LM, et al. Thyroid nodules and differentiated thyroid cancer: update on the Brazilian consensus. *Arq Bras Endocrinol Metabol*. 2013;57:240-64.

15. Steiner AL, Goodman AD, Powers SR. Study of a kindred with pheochromocytoma, medullary thyroid carcinoma, hyperparathyroidism and Cushing's disease: multiple endocrine neoplasia, type 2. *Medicine*. 1968;47:371-409.
16. Papaparaskeva K, Nagel H, Droese M. Cytologic diagnosis of medullary carcinoma of the thyroid gland. *Diagn Cytopathol*. 2000;22:351-8.
17. Essig GF Jr, Porter K, Schneider D, Debora A, Lindsey SC, Busoneiro G, et al. Fine needle aspiration and medullary thyroid carcinoma: the risk of inadequate preoperative evaluation and initial surgery when relying upon FNAB cytology alone. *Endocr Pract*. 2013;19:920-7.
18. Bugalho MJ, Santos JR, Sobrinho L. Preoperative diagnosis of medullary thyroid carcinoma: fine needle aspiration cytology as compared with serum calcitonin measurement. *J Surg Oncol*. 2005;91:56-60.
19. Chang TC, Wu SL, Hsiao YL. Medullary thyroid carcinoma: pitfalls in diagnosis by fine needle aspiration cytology and relationship of cytomorphology to RET proto-oncogene mutations. *Acta Cytol*. 2005;49:477-82.
20. Shah SS, Faquin WC, Izquierdo R, Khurana KK. FNA of misclassified primary malignant neoplasms of the thyroid: impact on clinical management. *Cytojournal*. 2009;6:1.
21. Forrest CH, Frost FA, de Boer WB, Spagnolo DV, Whitaker D, Sterrett BF. Medullary carcinoma of the thyroid: accuracy of diagnosis of fine-needle aspiration cytology. *Cancer*. 1998;84:295-302.
22. Boi F, Maurelli I, Pinna G, Atzeni F, Piga M, Lai ML, et al. Calcitonin measurement in wash-out fluid from fine needle aspiration of neck masses in patients with primary and metastatic medullary thyroid carcinoma. *J Clin Endocrinol Metab*. 2007;92:2115-8.
23. Siqueira D, Rocha AP, Pinales MK, Maia AL. Identification of occult metastases of medullary thyroid carcinoma by calcitonin measurement in washout fluid from fine needle aspiration of cervical lymph node. *Arq Bras Endocrinol Metabol*. 2009;53:479-81.
24. Trimboli P, Cremonini N, Ceriani L, Saggiorato E, Guidobaldi L, Romanelli F, et al. Calcitonin measurement in aspiration needle washout fluids has higher sensitivity than cytology in detecting medullary thyroid cancer: a retrospective multicentre study. *Clin Endocrinol*. 2014;80:135-40.
25. Takeichi N, Ito H, Okamoto H, Matsuyama T, Tahara E, Dohi K. The significance of immunochemically staining calcitonin and CEA in fine-needle aspiration biopsy materials from medullary carcinoma of the thyroid. *Jpn J Surg*. 1989;19:674-8.
26. Takano T, Miyauchi A, Matsuzuka F, Liu G, Higashiyama T, Yokozawa T, et al. Preoperative diagnosis of medullary thyroid carcinoma by RT-PCR using RNA extracted from leftover cells within a needle used for fine needle aspiration biopsy. *J Clin Endocrinol Metab*. 1999;84:951-5.
27. Nesland JM, Sobrinho-Simoes M, Johannessen JV. Scanning electron microscopy of the human thyroid gland and its disorders. *Scanning Microsc*. 1987;1:1797-810.
28. Chang TC, Lai SM, Wen CY, Hsiao YL, Huang SH. Three-dimensional cytomorphology in fine needle aspiration biopsy of medullary thyroid carcinoma. *Acta Cytol*. 2001;45:980-4.
29. Costante G, Meringolo D, Durante C, Bianchi D, Nocera M, Tumino S, et al. Predictive value of serum calcitonin levels for preoperative diagnosis of medullary thyroid carcinoma in a cohort of 5817 consecutive patients with thyroid nodules. *J Clin Endocrinol Metab*. 2007;92:450-5.
30. Karges W, Dralle H, Raue F, Mann K, Reiners C, Grussendorf M, et al. Calcitonin measurement to detect medullary thyroid carcinoma in nodular goiter: German evidence-based consensus recommendation. *Exp Clin Endocrinol Diabetes*. 2004;112:52-8.
31. Pina G, Dubois S, Murat A, Berger N, Niccoli P, Peix JL, et al. Groupe des Tumeurs Endocrines. Is basal ultrasensitive measurement of calcitonin capable of substituting for the pentagastrin-stimulation test? *Clin Endocrinol (Oxf)*. 2013;78:358-64.
32. Colombo C, Verga U, Mian C, Ferrero S, Perrino M, Vicentini L, et al. Comparison of calcium and pentagastrin tests for the diagnosis and follow-up of medullary thyroid cancer. *J Clin Endocrinol Metab*. 2012;97:905-13.
33. Mian C, Perrino M, Colombo C, Cavedon E, Pennelli G, Ferrero S, et al. Refining calcium test for the diagnosis of medullary thyroid cancer: cutoffs, procedures, and safety. *J Clin Endocrinol Metab*. 2014;99:1656-64.
34. Tashjian AH Jr, Howland BG, Melvin KE, Hill CS Jr. Immunoassay of human calcitonin. *N Engl J Med*. 1970;283:890-5.
35. Karanikas G, Moameni A, Poetzi C, Zettinig G, Kaserer K, Bieglmayer C, et al. Frequency and relevance of elevated calcitonin levels in patients with neoplastic and nonneoplastic thyroid disease and in healthy subjects. *J Clin Endocrinol Metab*. 2004;89:515-9.
36. Preissner CM, Dodge LA, O'Kane DJ, Singh RJ, Grebe SK. Prevalence of heterophilic antibody interference in eight automated tumor marker immunoassays. *Clin Chem*. 2005; 51:208-10.
37. Rosario PW, Calsolari MR. Influence of chronic autoimmune thyroiditis and papillary thyroid cancer on serum calcitonin levels. *Thyroid*. 2013;23:671-4.
38. Leboeuf R, Langlois MF, Martin M, Ahnadi CE, Fink GD. "Hook effect" in calcitonin immunoradiometric assay in patients with metastatic medullary thyroid carcinoma: case report and review of the literature. *J Clin Endocrinol Metab*. 2006;91:361-4.
39. Dora JM, Canalli MH, Capp C, Pinales MK, Vieira JG, Maia AL. Normal perioperative serum calcitonin levels in patients with advanced medullary thyroid carcinoma: case report and review of the literature. *Thyroid*. 2008;18:895-9.
40. Hasselgren M, Hegedus L, Godballe C, Bonnema SJ. Benefit of measuring basal serum calcitonin to detect medullary thyroid carcinoma in a Danish population with a high prevalence of thyroid nodules. *Head Neck*. 2010;32:612-8.
41. Papi G, Corsello SM, Cioni K, Pizzini AM, Corrado S, Carapezzi C, et al. Value of routine measurement of serum calcitonin concentrations in patients with nodular thyroid disease: a multicenter study. *J Endocrinol Invest*. 2006;29:427-37.
42. Elisei R, Bottici V, Luchetti F, Di Coscio G, Romei C, Grasso L, et al. Impact of routine measurement of serum calcitonin on the diagnosis and outcome of medullary thyroid cancer: experience in 10,864 patients with nodular thyroid disorders. *J Clin Endocrinol Metab*. 2004;89:163-8.
43. Borget I, De Pouvourville G, Schlumberger M. Editorial: calcitonin determination in patients with nodular thyroid disease. *J Clin Endocrinol Metab*. 2007;92:425-7.
44. Cheung K, Roman SA, Wang TS, Walker HD, Sosa JA. Calcitonin measurement in the evaluation of thyroid nodules in the United States: a cost-effectiveness and decision analysis. *J Clin Endocrinol Metab*. 2008;93:2173-80.
45. Rieu M, Lame MC, Richard A, Lissak B, Sambort B, Vuong-Ngoc P, et al. Prevalence of sporadic medullary thyroid carcinoma: the importance of routine measurement of serum calcitonin in the diagnostic evaluation of thyroid nodules. *Clin Endocrinol (Oxf)*. 1995;42:453-60.
46. Ozgen AG, Hamulu F, Bayraktar F, Yilmaz C, Tuzun M, Yetkin E, et al. Evaluation of routine basal serum calcitonin measurement for early diagnosis of medullary thyroid carcinoma in seven hundred seventy-three patients with nodular goiter. *Thyroid*. 1999;9:579-82.
47. Hahm JR, Lee MS, Min YK, Lee MK, Kim KW, Nam SJ, et al. Routine measurement of serum calcitonin is useful for early detec-



- tion of medullary thyroid carcinoma in patients with nodular thyroid diseases. *Thyroid*. 2001;11:73-80.
48. Ahmed SR, Ball DW. Clinical review: Incidentally discovered medullary thyroid cancer: diagnostic strategies and treatment. *J Clin Endocrinol Metab*. 2011;96:1237-45.
49. Elisei R. Routine serum calcitonin measurement in the evaluation of thyroid nodules. *Best Pract Res Clin Endocrinol Metab*. 2008;22:941-53.
50. Vierhapper H, Raber W, Bieglmayer C, Kaserer K, Weinhausl A, Niederle B. Routine measurement of plasma calcitonin in nodular thyroid diseases. *J Clin Endocrinol Metab*. 1997;82:1589-93.
51. Pacini F, Fontanelli M, Fugazzola L, Elisei R, Romei C, Di Coscio G, et al. Routine measurement of serum calcitonin in nodular thyroid diseases allows the preoperative diagnosis of unsuspected sporadic medullary thyroid carcinoma. *J Clin Endocrinol Metab*. 1994;78:826-9.
52. Said SI. Evidence for secretion of vasoactive intestinal peptide by tumours of pancreas, adrenal medulla, thyroid and lung: support for the unifying APUD concept. *Clin Endocrinol (Oxf)*. 1976;5 Suppl:201S-4S.
53. Holm R, Sobrinho-Simoes M, Nesland JM, Gould VE, Johannesen JV. Medullary carcinoma of the thyroid gland: an immunocytochemical study. *Ultrastruct Pathol*. 1985;8:25-41.
54. Pacini F, Castagna MG, Cipri C, Schlumberger M. Medullary thyroid carcinoma. *Clin Oncol (R Coll Radiol)*. 2010;22:475-85.
55. Machens A, Ukkat J, Hauptmann S, Dralle H. Abnormal carcinoembryonic antigen levels and medullary thyroid cancer progression: a multivariate analysis. *Arch Surg*. 2007;142:289-93.
56. Machens A, Dralle H. Biomarker-based risk stratification for previously untreated medullary thyroid cancer. *J Clin Endocrinol Metab*. 2010;95:2655-63.
57. Peccin S, de Castros JA, Furlanetto TW, Furtado AP, Brasil BA, Czepielewski MA. Ultrasonography: is it useful in the diagnosis of cancer in thyroid nodules? *J Endocrinol Invest*. 2002;25:39-43.
58. Alexander EK, Marqusee E, Orcutt J, Benson CB, Frates MC, Doubilet PM, et al. Thyroid nodule shape and prediction of malignancy. *Thyroid*. 2004;14:953-8.
59. Tomimori EK, Bisi H, Medeiros-Neto G, Camargo RY. [Ultrasonographic evaluation of thyroid nodules: comparison with cytologic and histologic diagnosis]. *Arq Bras Endocrinol Metabol*. 2004;48:105-13.
60. Saller B, Moeller L, Gorges R, Janssen OE, Mann K. Role of conventional ultrasound and color Doppler sonography in the diagnosis of medullary thyroid carcinoma. *Exp Clin Endocrinol Diabetes*. 2002;110:403-7.
61. Gorman B, Charboneau JW, James EM, Reading CC, Wold LE, Grant CS, et al. Medullary thyroid carcinoma: role of high-resolution US. *Radiology*. 1987;162:147-50.
62. Kouvaraki MA, Shapiro SE, Fornage BD, Edeiken-Monro BS, Sherman SI, Vassilopoulou-Sellin R, et al. Role of preoperative ultrasonography in the surgical management of patients with thyroid cancer. *Surgery*. 2003;134:946-54.
63. Hwang HS, Orloff LA. Efficacy of preoperative neck ultrasound in the detection of cervical lymph node metastasis from thyroid cancer. *Laryngoscope*. 2011;121:487-91.
64. Ahn JE, Lee JH, Yi JS, Shong YK, Hong SJ, Lee DH, et al. Diagnostic accuracy of CT and ultrasonography for evaluating metastatic cervical lymph nodes in patients with thyroid cancer. *World J Surg*. 2008;32:1552-8.
65. Moley JF, Brothier MB, Wells SA, Spengler BA, Biedler JL, Brodeur GM. Low frequency of ras gene mutations in neuroblastomas, pheochromocytomas, and medullary thyroid cancers. *Cancer Res*. 1991;51:1596-9.
66. Kebebew E, Ituarte PH, Siperstein AE, Duh QY, Clark OH. Medullary thyroid carcinoma: clinical characteristics, treatment, prognostic factors, and a comparison of staging systems. *Cancer*. 2000;88:1139-48.
67. Bergholm U, Adami HO, Bergstrom R, Johansson H, Lundell G, Telenius-Berg M, et al. Clinical characteristics in sporadic and familial medullary thyroid carcinoma. A nationwide study of 249 patients in Sweden from 1959 through 1981. *Cancer*. 1989;63:1196-204.
68. Yen TW, Shapiro SE, Gagel RF, Sherman SI, Lee JE, Evans DB. Medullary thyroid carcinoma: results of a standardized surgical approach in a contemporary series of 80 consecutive patients. *Surgery*. 2003;134:890-9.
69. Kramer CK, Leitão CB, Azevedo MJ, Canani LH, Maia AL, Czepielewski M, et al. Degree of catecholamine hypersecretion is the most important determinant of intra-operative hemodynamic outcomes in pheochromocytoma. *J Endocrinol Invest*. 2009;32:234-7.
70. Pereira MA, Souza BF, Freire DS, Lucon AM. [Pheochromocytoma]. *Arq Bras Endocrinol Metabol*. 2004;48:751-75.
71. Lenders JW, Eisenhofer G, Mannelli M, Pacak K. Pheochromocytoma. *Lancet*. 2005;366:665-75.
72. Machens A, Brauckhoff M, Holzhausen HJ, Thanh PN, Lehnert H, Dralle H. Codon-specific development of pheochromocytoma in multiple endocrine neoplasia type 2. *J Clin Endocrinol Metab*. 2005;90:3999-4003.
73. Kloos RT, Eng C, Evans DB, Francis GL, Gagel RF, Gharib H, et al. Medullary thyroid cancer: management guidelines of the American Thyroid Association. *Thyroid*. 2009;19:565-612.
74. Rodriguez JM, Balsalobre M, Ponce JL, Rios A, Torregrosa NM, Tebar J, et al. Pheochromocytoma in MEN 2A syndrome. Study of 54 patients. *World J Surg*. 2008;32:2520-6.
75. Lenders JW, Pacak K, Walther MM, Linehan WM, Mannelli M, Friberg P, et al. Biochemical diagnosis of pheochromocytoma: which test is best? *JAMA*. 2002;287:1427-34.
76. Boyle JG, Davidson DF, Perry CG, Connell JM. Comparison of diagnostic accuracy of urinary free metanephrines, vanillyl mandelic Acid, and catecholamines and plasma catecholamines for diagnosis of pheochromocytoma. *J Clin Endocrinol Metab*. 2007;92:4602-8.
77. Sawka AM, Jaeschke R, Singh RJ, Young WF Jr. A comparison of biochemical tests for pheochromocytoma: measurement of fractionated plasma metanephrines compared with the combination of 24-hour urinary metanephrines and catecholamines. *J Clin Endocrinol Metab*. 2003;88:553-8.
78. Eisenhofer G, Goldstein DS, Walther MM, Friberg P, Lenders JW, Keiser HR, et al. Biochemical diagnosis of pheochromocytoma: how to distinguish true- from false-positive test results. *J Clin Endocrinol Metab*. 2003;88:2656-66.
79. Pacak K, Ilias I, Adams KT, Eisenhofer G. Biochemical diagnosis, localization and management of pheochromocytoma: focus on multiple endocrine neoplasia type 2 in relation to other hereditary syndromes and sporadic forms of the tumour. *J Intern Med*. 2005;257:60-8.
80. Pomares FJ, Canas R, Rodriguez JM, Hernandez AM, Parrilla P, Tebar FJ. Differences between sporadic and multiple endocrine neoplasia type 2A pheochromocytoma. *Clin Endocrinol (Oxf)*. 1998;48:195-200.
81. Hamrahian AH, Ioachimescu AG, Remer EM, Motta-Ramirez G, Bogabathina H, Levin HS, et al. Clinical utility of noncontrast computed tomography attenuation value (hounsfield units) to differentiate adrenal adenomas/hyperplasias from nonadenomas: Cleveland Clinic experience. *J Clin Endocrinol Metab*. 2005;90:871-7.
82. Szolar DH, Korobkin M, Reittner P, Berghold A, Bauernhofer T, Trummer H, et al. Adrenocortical carcinomas and adrenal pheo-

- chromocytomas: mass and enhancement loss evaluation at delayed contrast-enhanced CT. *Radiology*. 2005;234:479-85.
83. Pena CS, Boland GW, Hahn PF, Lee MJ, Mueller PR. Characterization of indeterminate (lipid-poor) adrenal masses: use of washout characteristics at contrast-enhanced CT. *Radiology*. 2000;217:798-802.
  84. Kouvaraki MA, Shapiro SE, Perrier ND, Cote GJ, Gagel RF, Hoff AO, et al. RET proto-oncogene: a review and update of genotype-phenotype correlations in hereditary medullary thyroid cancer and associated endocrine tumors. *Thyroid*. 2005;15:531-44.
  85. Schuffenecker I, Virally-Monod M, Brohet R, Goldgar D, Conte-Devolx B, Leclerc L, et al. Risk and penetrance of primary hyperparathyroidism in multiple endocrine neoplasia type 2A families with mutations at codon 634 of the RET proto-oncogene. Groupe D'etude des Tumeurs à Calcitonine. *J Clin Endocrinol Metab*. 1998;83(2):487-91.
  86. Ceolin L, Siqueira DR, Romitti M, Ferreira CV, Maia AL. Molecular basis of medullary thyroid carcinoma: the role of RET polymorphisms. *Int J Mol Sci*. 2012;13:221-39.
  87. Machens A, Gimm O, Hinze R, Hoppner W, Boehm BO, Dralle H. Genotype-phenotype correlations in hereditary medullary thyroid carcinoma: oncological features and biochemical properties. *J Clin Endocrinol Metab*. 2001;86:1104-9.
  88. Ponder BA. The phenotypes associated with RET mutations in the multiple endocrine neoplasia type 2 syndrome. *Cancer Res*. 1999;59:1736s-41s.
  89. Lips CJ, Landsvater RM, Hoppener JW, Geerdink RA, Blijham G, van Veen JM, et al. Clinical screening as compared with DNA analysis in families with multiple endocrine neoplasia type 2A. *N Engl J Med*. 1994;331:828-35.
  90. Vieira AE, Mello MP, Elias LL, Lau IF, Maciel LM, Moreira AC, et al. Molecular and biochemical screening for the diagnosis and management of medullary thyroid carcinoma in multiple endocrine neoplasia type 2A. *Horm Metab Res*. 2002;34:202-6.
  91. Frilling A, Dralle H, Eng C, Raue F, Broelsch CE. Presymptomatic DNA screening in families with multiple endocrine neoplasia type 2 and familial medullary thyroid carcinoma. *Surgery*. 1995;118:1099-103.
  92. Eng C, Clayton D, Schuffenecker I, Lenoir G, Cote G, Gagel RF, et al. The relationship between specific RET proto-oncogene mutations and disease phenotype in multiple endocrine neoplasia type 2. International RET mutation consortium analysis. *JAMA*. 1996;276:1575-9.
  93. Bugalho MJ, Domingues R, Santos JR, Catarino AL, Sobrinho L. Mutation analysis of the RET proto-oncogene and early thyroidectomy: results of a Portuguese cancer centre. *Surgery*. 2007;141:90-5.
  94. Wiench M, Wygoda Z, Gubala E, Wloch J, Lisowska K, Krassowski J, et al. Estimation of risk of inherited medullary thyroid carcinoma in apparent sporadic patients. *J Clin Oncol*. 2001;19:1374-80.
  95. Elisei R, Romei C, Cosci B, Agate L, Bottici V, Molinaro E, et al. RET genetic screening in patients with medullary thyroid cancer and their relatives: experience with 807 individuals at one center. *J Clin Endocrinol Metab*. 2007;92:4725-9.
  96. Romei C, Cosci B, Renzini G, Bottici V, Molinaro E, Agate L, et al. RET genetic screening of sporadic medullary thyroid cancer (MTC) allows the preclinical diagnosis of unsuspected gene carriers and the identification of a relevant percentage of hidden familial MTC (FMTC). *Clin Endocrinol (Oxf)*. 2011;74:241-7.
  97. Maia AL, Puñales MK, Mazeto G, Caldas G, Ward LS, Kimura ET, et al. Carcinoma medular de tireoide: diagnóstico. Diretrizes Clínicas na Saúde Suplementar da Associação Médica Brasileira e Agência Nacional de Saúde Suplementar 2011. Available at: [http://www.projetodiretrizes.org.br/ans/diretrizes/cancer\\_medular\\_de\\_tireoide-diagnostico.pdf](http://www.projetodiretrizes.org.br/ans/diretrizes/cancer_medular_de_tireoide-diagnostico.pdf). Accessed on: Oct 1, 2014.
  98. Elisei R, Alevizaki M, Conte-Devolx B, Frank-Raue K, Leite V, Williams GR. 2012 European thyroid association guidelines for genetic testing and its clinical consequences in medullary thyroid cancer. *Eur Thyroid J*. 2013;1:216-31.
  99. Miccoli P, Elisei R, Donatini G, Materazzi G, Berti P. Video-assisted central compartment lymphadenectomy in a patient with a positive RET oncogene: initial experience. *Surg Endosc*. 2007;21:120-3.
  100. Punales MK, da Rocha AP, Meotti C, Gross JL, Maia AL. Clinical and oncological features of children and young adults with multiple endocrine neoplasia type 2A. *Thyroid*. 2008;18:1261-8.
  101. Machens A, Lorenz K, Dralle H. Progression of medullary thyroid cancer in RET carriers of ATA class A and C mutations. *J Clin Endocrinol Metab*. 2014;99:E286-92.
  102. Punales MK, Graf H, Gross JL, Maia AL. RET codon 634 mutations in multiple endocrine neoplasia type 2: variable clinical features and clinical outcome. *J Clin Endocrinol Metab*. 2003;88:2644-9.
  103. Milos IN, Frank-Raue K, Wohllik N, Maia AL, Pusioli E, Patocs A, et al. Age-related neoplastic risk profiles and penetrance estimations in multiple endocrine neoplasia type 2A caused by germ line RET Cys634Trp (TGC>TGG) mutation. *Endocr Relat Cancer*. 2008;15:1035-41.
  104. Pelizzo MR, Boschin IM, Bernante P, Toniato A, Piotto A, Pagetta C, et al. Natural history, diagnosis, treatment and outcome of medullary thyroid cancer: 37 years experience on 157 patients. *Eur J Surg Oncol*. 2007;33:493-7.
  105. Siqueira DR, Ceolin L, Ferreira CV, Romitti M, Maia SC, Zanini Maciel LM, et al. Role of ret genetic variants in MEN 2-associated pheochromocytoma. *Eur J Endocrinol*. 2014;170:821-8.
  106. Nunziata V, Giannattasio R, Di Giovanni G, D'Armiento MR, Mancini M. Hereditary localized pruritus in affected members of a kindred with multiple endocrine neoplasia type 2A (Sipple's syndrome). *Clin Endocrinol (Oxf)*. 1989;30:57-63.
  107. Gagel RF, Levy ML, Donovan DT, Alford BR, Wheeler T, Tschen JA. Multiple endocrine neoplasia type 2a associated with cutaneous lichen amyloidosis. *Ann Intern Med*. 1989;111:802-6.
  108. Vaclavikova E, Kavalcova L, Skaba R, Dvorakova S, Macokova P, Rouskova B, et al. Hirschsprung's disease and medullary thyroid carcinoma: 15-year experience with molecular genetic screening of the RET proto-oncogene. *Pediatr Surg Int*. 2012;28(2):123-8.
  109. Romeo G, Ceccherini I, Celli J, Priolo M, Betsos N, Bonardi G, et al. Association of multiple endocrine neoplasia type 2 and Hirschsprung disease. *J Intern Med*. 1998;243:515-20.
  110. Brandi ML, Gagel RF, Angeli A, Bilezikian JP, Beck-Peccoz P, Bordi C, et al. Guidelines for diagnosis and therapy of MEN type 1 and type 2. *J Clin Endocrinol Metab*. 2001;86:5658-71.
  111. Machens A, Lorenz K, Dralle H. Peak incidence of pheochromocytoma and primary hyperparathyroidism in multiple endocrine neoplasia 2: need for age-adjusted biochemical screening. *J Clin Endocrinol Metab*. 2013;98:E336-45.
  112. Romei C, Pardi E, Cetani F, Elisei R. Genetic and clinical features of multiple endocrine neoplasia types 1 and 2. *J Oncol*. 2012;2012:705036.
  113. Skinner MA, DeBenedetti MK, Moley JF, Norton JA, Wells SA Jr. Medullary thyroid carcinoma in children with multiple endocrine neoplasia types 2A and 2B. *J Pediatr Surg*. 1996;31:177-81.
  114. Quayle FJ, Fialkowski EA, Benveniste R, Moley JF. Pheochromocytoma penetrance varies by RET mutation in MEN 2A. *Surgery*. 2007;142:800-5.
  115. Kraimps JL, Denizot A, Carnaille B, Henry JF, Proye C, Bacourt F, et al. Primary hyperparathyroidism in multiple endocrine neoplasia type IIa: retrospective French multicentric study. Groupe

- d'Etude des Tumeurs a Calcitonine (GETC, French Calcitonin Tumors Study Group), French Association of Endocrine Surgeons. *World J Surg.* 1996;20:808-12.
116. Raue F, Kraimps JL, Dralle H, Cougard P, Proye C, Frilling A, et al. Primary hyperparathyroidism in multiple endocrine neoplasia type 2A. *J Intern Med.* 1995;238:369-73.
117. Magalhaes PK, Antonini SR, de Paula FJ, de Freitas LC, Maciel LM. Primary hyperparathyroidism as the first clinical manifestation of multiple endocrine neoplasia type 2A in a 5-year-old child. *Thyroid.* 2011;21:547-50.
118. Machens A, Holzhausen HJ, Dralle H. Contralateral cervical and mediastinal lymph node metastasis in medullary thyroid cancer: systemic disease? *Surgery.* 2006;139:28-32.
119. Tavares MR, Michaluart P Jr, Montenegro F, Arap S, Sodre M, Takeda F, et al. Skip metastases in medullary thyroid carcinoma: a single-center experience. *Surg Today.* 2008;38:499-504.
120. Lupone G, Antonino A, Rosato A, Zenone P, Iervolino EM, Grillo M, et al. Surgical strategy for the treatment of sporadic medullary thyroid carcinoma: our experience. *G Chir.* 2012;33:395-9.
121. Weber T, Schilling T, Frank-Raue K, Colombo-Benkmann M, Hinz U, Ziegler R, et al. Impact of modified radical neck dissection on biochemical cure in medullary thyroid carcinomas. *Surgery.* 2001;130:1044-9.
122. Machens A, Hauptmann S, Dralle H. Increased risk of lymph node metastasis in multifocal hereditary and sporadic medullary thyroid cancer. *World J Surg.* 2007;31:1960-5.
123. Dralle H, Machens A. Surgical management of the lateral neck compartment for metastatic thyroid cancer. *Curr Opin Oncol.* 2013;25:20-6.
124. Greene FL, Page DL, Fleming ID, Fritz A, Balch DM. 2003 AJCC Cancer Staging Manual, 6th edition. Springer Verlag, Chicago.
125. Franc S, Niccoli-Sire P, Cohen R, Bardet S, Maes B, Murat A, et al. Complete surgical lymph node resection does not prevent authentic recurrences of medullary thyroid carcinoma. *Clin Endocrinol (Oxf).* 2001;55:403-9.
126. Ito Y, Miyauchi A, Yabuta T, Fukushima M, Inoue H, Tomoda C, et al. Alternative surgical strategies and favorable outcomes in patients with medullary thyroid carcinoma in Japan: experience of a single institution. *World J Surg.* 2009;33:58-66.
127. Machens A, Dralle H. Biological relevance of medullary thyroid microcarcinoma. *J Clin Endocrinol Metab.* 2012;97:1547-53.
128. van Heerden JA, Kent RB 3rd, Sizemore GW, Grant CS, ReMine WH. Primary hyperparathyroidism in patients with multiple endocrine neoplasia syndromes. Surgical experience. *Arch Surg.* 1983;118:533-6.
129. Herfarth KK, Bartsch D, Doherty GM, Wells SA Jr, Lairmore TC. Surgical management of hyperparathyroidism in patients with multiple endocrine neoplasia type 2A. *Surgery.* 1996;120:966-73.
130. Scholten A, Schreinemakers JM, Pieterman CR, Valk GD, Vriens MR, Borel Rinkes IH. Evolution of surgical treatment of primary hyperparathyroidism in patients with multiple endocrine neoplasia type 2A. *Endocr Pract.* 2011;17:7-15.
131. Olson JA Jr, DeBenedetti MK, Baumann DS, Wells SA Jr. Parathyroid autotransplantation during thyroidectomy. Results of long-term follow-up. *Ann Surg.* 1996;223:472-8.
132. Marocchi C, Chanson P, Shoback D, Bilezikian J, Fernandez-Cruz L, Orgiazzi J, et al. Cinacalcet reduces serum calcium concentrations in patients with intractable primary hyperparathyroidism. *J Clin Endocrinol Metab.* 2009;94:2766-72.
133. Kunz PL, Reidy-Lagunes D, Anthony LB, Bertino EM, Brendtro K, Chan JA, et al. Consensus guidelines for the management and treatment of neuroendocrine tumors. *Pancreas.* 2013;42:557-77.
134. Skinner MA, Moley JA, Dilley WG, Owzar K, DeBenedetti MK, Wells SA Jr. Prophylactic thyroidectomy in multiple endocrine neoplasia type 2A. *N Engl J Med.* 2005;353:1105-13.
135. Greenblatt DY, Elson D, Mack E, Chen H. Initial lymph node dissection increases cure rates in patients with medullary thyroid cancer. *Asian J Surg.* 2007;30:108-12.
136. Machens A, Gimm O, Ukkat J, Hinz R, Schneyer U, Dralle H. Improved prediction of calcitonin normalization in medullary thyroid carcinoma patients by quantitative lymph node analysis. *Cancer.* 2000;88:1909-15.
137. Tuttle RM, Ganly I. Risk stratification in medullary thyroid cancer: Moving beyond static anatomic staging. *Oral Oncol.* 2013;49:695-701.
138. Dralle H, Damm I, Scheumann GF, Kotzerke J, Kupsch E, Geerlings H, et al. Compartment-oriented microdissection of regional lymph nodes in medullary thyroid carcinoma. *Surg Today.* 1994;24:112-21.
139. Machens A, Hauptmann S, Dralle H. Prediction of lateral lymph node metastases in medullary thyroid cancer. *Br J Surg.* 2008;95:586-91.
140. Chen H, Sippel RS, O'Dorisio MS, Vinik AI, Lloyd RV, Pacak K; North American Neuroendocrine Tumor Society (NANETS). The North American Neuroendocrine Tumor Society consensus guideline for the diagnosis and management of neuroendocrine tumors: Pheochromocytoma, paraganglioma, and medullary thyroid cancer. *Pancreas.* 2010;39:775-83.
141. Castinetti F, Qi XP, Walz MK, Maia AL, Sanso G, Peczkowska M, et al. Outcomes of adrenal-sparing surgery or total adrenalectomy in pheochromocytoma associated with multiple endocrine neoplasia type 2: an international retrospective population-based study. *Lancet Oncol.* 2014;15:648-55.
142. Stephanas AV, Samaan NA, Hill CS Jr, Hickey RC. Medullary thyroid carcinoma: importance of serial serum calcitonin measurement. *Cancer.* 1979;43:825-37.
143. Fugazzola L, Pinchera A, Luchetti F, Iacconi P, Miccoli P, Romei C, et al. Disappearance rate of serum calcitonin after total thyroidectomy for medullary thyroid carcinoma. *Int J Biol Markers.* 1994;9:21-4.
144. Tisell LE, Dilley WG, Wells SA Jr. Progression of postoperative residual medullary thyroid carcinoma as monitored by plasma calcitonin levels. *Surgery.* 1996;119:34-9.
145. Ismailov SI, Piulato NR. Postoperative calcitonin study in medullary thyroid carcinoma. *Endocr Relat Cancer.* 2004;11:357-63.
146. Henriksen JH, Schifter S, Moller S, Bendtsen F. Increased circulating calcitonin in cirrhosis. Relation to severity of disease and calcitonin gene-related peptide. *Metabolism.* 2000;49:47-52.
147. Austin LA, Heath H 3rd. Calcitonin: physiology and pathophysiology. *N Engl J Med.* 1981;304:269-78.
148. Dralle H, Damm I, Scheumann GF, Kotzerke J, Kupsch E. Frequency and significance of cervicomedistal lymph node metastases in medullary thyroid carcinoma: results of a compartment-oriented microdissection method. *Henry Ford Hosp Med J.* 1992;40:264-7.
149. Busnardo B, Girelli ME, Simioni N, Nacamulli D, Busetto E. Non-parallel patterns of calcitonin and carcinoembryonic antigen levels in the follow-up of medullary thyroid carcinoma. *Cancer.* 1984;53:278-85.
150. Miccoli P, Minuto MN, Ugolini C, Molinaro E, Basolo F, Berti P, et al. Clinically unpredictable prognostic factors in the outcome of medullary thyroid cancer. *Endocr Relat Cancer.* 2007;14:1099-105.
151. Baloch ZW, LiVolsi VA. Prognostic factors in well-differentiated follicular-derived carcinoma and medullary thyroid carcinoma. *Thyroid.* 2001;11:637-45.
152. Gawlik T, d'Amico A, Szpak-Ulczo S, Skoczylas A, Gubała E, Choraży A, et al. The prognostic value of tumor markers doubling

- times in medullary thyroid carcinoma – preliminary report. *Thyroid Res.* 2010;3:10.
153. Modigliani E, Cohen R, Campos JM, Conte-Devolx B, Maes B, Boneu A, et al. Prognostic factors for survival and for biochemical cure in medullary thyroid carcinoma: results in 899 patients. The GETC Study Group. *Groupe d'étude des tumeurs a calcitonine. Clin Endocrinol (Oxf).* 1998;48:265-73.
154. Chow SM, Chan JK, Tiu SC, Choi KL, Tang DL, Law SC. Medullary thyroid carcinoma in Hong Kong Chinese patients. *Hong Kong Med J.* 2005;11:251-8.
155. Pillarisetty VG, Katz SC, Ghossein RA, Tuttle RM, Shaha AR. Micromedullary thyroid cancer: how micro is truly micro? *Ann Surg Oncol.* 2009;16:2875-81.
156. Peixoto Callejo I, Americo Brito J, Zagalo CM, Rosa Santos J. Medullary thyroid carcinoma: multivariate analysis of prognostic factors influencing survival. *Clin Transl Oncol.* 2006;8:435-43.
157. Miyauchi A, Onishi T, Morimoto S, Takai S, Matsuzuka F, Kuma K, et al. Relation of doubling time of plasma calcitonin levels to prognosis and recurrence of medullary thyroid carcinoma. *Ann Surg.* 1984;199:461-6.
158. Barbet J, Campion L, Kraeber-Bodere F, Chatal JF. Prognostic impact of serum calcitonin and carcinoembryonic antigen doubling-times in patients with medullary thyroid carcinoma. *J Clin Endocrinol Metab.* 2005;90:6077-84.
159. Meijer JA, le Cessie S, van den Hout WB, Kievit J, Schoones JW, Romijn JA, et al. Calcitonin and carcinoembryonic antigen doubling times as prognostic factors in medullary thyroid carcinoma: a structured meta-analysis. *Clin Endocrinol (Oxf).* 2010;72:534-42.
160. Bihan H, Becker KL, Snider RH, Nysten E, Vittaz L, Lauret C, et al. Calcitonin precursor levels in human medullary thyroid carcinoma. *Thyroid.* 2003;13:819-22.
161. Walter MA, Meier C, Radimerski T, Iten F, Kranzlin M, Muller-Brand J, et al. Procalcitonin levels predict clinical course and progression-free survival in patients with medullary thyroid cancer. *Cancer.* 2010;116:31-40.
162. Cupisti K, Wolf A, Raffel A, Schott M, Miersch D, Yang Q, et al. Long-term clinical and biochemical follow-up in medullary thyroid carcinoma: a single institution's experience over 20 years. *Ann Surg.* 2007;246:815-21.
163. Rendl G, Manzl M, Hitzl W, Sungler P, Pirich C. Long-term prognosis of medullary thyroid carcinoma. *Clin Endocrinol (Oxf).* 2008;69:497-505.
164. Tuttle RM, Tala H, Shah J, Leboeuf R, Ghossein R, Gonen M, et al. Estimating risk of recurrence in differentiated thyroid cancer after total thyroidectomy and radioactive iodine remnant ablation: using response to therapy variables to modify the initial risk estimates predicted by the new American Thyroid Association staging system. *Thyroid.* 2010;20:1341-9.
165. Laure Giraudet A, Al Ghulzan A, Auperin A, Lebouilleux S, Chehboun A, Troalen F, et al. Progression of medullary thyroid carcinoma: assessment with calcitonin and carcinoembryonic antigen doubling times. *Eur J Endocrinol.* 2008;158:239-46.
166. Lundgren CI, Delbridg L, Learoyd D, Robinson B. Surgical approach to medullary thyroid cancer. *Arq Bras Endocrinol Metabol.* 2007;51:818-24.
167. Mirallie E, Vuillez JP, Bardet S, Frampas E, Dupas B, Ferrer L, et al. High frequency of bone/bone marrow involvement in advanced medullary thyroid cancer. *J Clin Endocrinol Metab.* 2005;90:779-88.
168. Koopmans KP, de Groot JW, Plukker JT, de Vries EG, Kema IP, Sluiter WJ, et al. 18F-dihydroxyphenylalanine PET in patients with biochemical evidence of medullary thyroid cancer: relation to tumor differentiation. *J Nucl Med.* 2008;49:524-31.
169. Szakall S Jr, Esik O, Bajzik G, Repa I, Dabasi G, Sinkovics I, et al. 18F-FDG PET detection of lymph node metastases in medullary thyroid carcinoma. *J Nucl Med.* 2002;43:66-71.
170. Diehl M, Risse JH, Brandt-Mainz K, Dietlein M, Bohuslavizki KH, Matheja P, et al. Fluorine-18 fluorodeoxyglucose positron emission tomography in medullary thyroid cancer: results of a multicentre study. *Eur J Nucl Med.* 2001;28:1671-6.
171. Beuthien-Baumann B, Strumpf A, Zessin J, Bredow J, Kotzerke J. Diagnostic impact of PET with 18F-FDG, 18F-DOPA and 3-O-methyl-6-[18F]fluoro-DOPA in recurrent or metastatic medullary thyroid carcinoma. *Eur J Nucl Med Mol Imaging.* 2007;34:1604-9.
172. Faggiano A, Grimaldi F, Pezzullo L, Chiofalo MG, Caraco C, Mozzillo N, et al. Secretive and proliferative tumor profile helps to select the best imaging technique to identify postoperative persistent or relapsing medullary thyroid cancer. *Endocr Relat Cancer.* 2009;16:225-31.
173. Gomez-Camarero P, Ortiz-de Tena A, Borrego-Dorado I, Vazquez-Albertino RJ, Navarro-Gonzalez E, Ruiz-Franco-Baux JV, et al. [Evaluation of efficacy and clinical impact of 18F-FDG-PET in the diagnosis of recurrent medullary thyroid cancer with increased calcitonin and negative imaging test]. *Rev Esp Med Nucl Imagen Mol.* 2012;31:261-6.
174. Treglia G, Castaldi P, Villani MF, Perotti G, de Waure C, Filice A, et al. Comparison of 18F-DOPA, 18F-FDG and 68Ga-somatostatin analogue PET/CT in patients with recurrent medullary thyroid carcinoma. *Eur J Nucl Med Mol Imaging.* 2012;39:569-80.
175. Naswa N, Sharma P, Suman Kc S, Lata S, Kumar R, Malhotra A, et al. Prospective evaluation of 68Ga-DOTA-NOC PET-CT in patients with recurrent medullary thyroid carcinoma: comparison with 18F-FDG PET-CT. *Nucl Med Commun.* 2012 33:766-74.
176. Engelbach M, Gorges R, Forst T, Pfutzner A, Dawood R, Heerdt S, et al. Improved diagnostic methods in the follow-up of medullary thyroid carcinoma by highly specific calcitonin measurements. *J Clin Endocrinol Metab.* 2000;85:1890-4.
177. Redding AH, Levine SN, Fowler MR. Normal preoperative calcitonin levels do not always exclude medullary thyroid carcinoma in patients with large palpable thyroid masses. *Thyroid.* 2000;10:919-22.
178. Wells SA Jr, Baylin SB, Linehan WM, Farrell RE, Cox EB, Cooper CW. Provocative agents and the diagnosis of medullary carcinoma of the thyroid gland. *Ann Surg.* 1978;188:39-41.
179. Randolph GW, Maniar D. Medullary carcinoma of the thyroid. *Cancer Control.* 2000;7:253-61.
180. Gimm O, Dralle H. Reoperation in metastasizing medullary thyroid carcinoma: is a tumor stage-oriented approach justified? *Surgery.* 1997;122:1124-30.
181. Kebebew E, Kikuchi S, Duh QY, Clark OH. Long-term results of reoperation and localizing studies in patients with persistent or recurrent medullary thyroid cancer. *Arch Surg.* 2000;135:895-901.
182. Tisell LE, Hansson G, Jansson S, Salander H. Reoperation in the treatment of asymptomatic metastasizing medullary thyroid carcinoma. *Surgery.* 1986;99:60-6.
183. Moley JF, DeBenedetti MK, Dilley WG, Tisell LE, Wells SA. Surgical management of patients with persistent or recurrent medullary thyroid cancer. *J Intern Med.* 1998;243:521-6.
184. Fialkowski E, DeBenedetti M, Moley J. Long-term outcome of reoperations for medullary thyroid carcinoma. *World J Surg.* 2008;32:754-65.
185. van Heerden JA, Grant CS, Gharib H, Hay ID, Ilstrup DM. Long-term course of patients with persistent hypercalcitoninemia after apparent curative primary surgery for medullary thyroid carcinoma. *Ann Surg.* 1990;212:395-400.
186. Moley JF, Fialkowski EA. Evidence-based approach to the management of sporadic medullary thyroid carcinoma. *World J Surg.* 2007;31:946-56.
187. Fialkowski EA, Moley JF. Current approaches to medullary thyroid carcinoma, sporadic and familial. *J Surg Oncol.* 2006;94:737-47.

188. Pellegriti G, Leboulleux S, Baudin E, Bellon N, Scollo C, Travagli JP, et al. Long-term outcome of medullary thyroid carcinoma in patients with normal postoperative medical imaging. *Br J Cancer*. 2003;88:1537-42.
189. Hanna FW, Ardill JE, Johnston CF, Cunningham RT, Curry WJ, Russell CF, et al. Regulatory peptides and other neuroendocrine markers in medullary carcinoma of the thyroid. *J Endocrinol*. 1997;152:275-81.
190. Jenkins PJ, Satta MA, Simmgen M, Drake WM, Williamson C, Lowe DG, et al. Metastatic parathyroid carcinoma in the MEN2A syndrome. *Clin Endocrinol (Oxf)*. 1997;47:747-51.
191. Rambaud JC, Jian R, Flourie B, Hautefeuille M, Salmeron M, Thuillier F, et al. Pathophysiological study of diarrhoea in a patient with medullary thyroid carcinoma. Evidence against a secretory mechanism and for the role of shortened colonic transit time. *Gut*. 1988;29:537-43.
192. Cox TM, Fagan EA, Hillyard CJ, Allison DJ, Chadwick VS. Role of calcitonin in diarrhoea associated with medullary carcinoma of the thyroid. *Gut*. 1979;20:629-33.
193. Vainas I, Koussis C, Pazaitou-Panayiotou K, Drimonitis A, Chrisoulidou A, Iakovou I, et al. Somatostatin receptor expression in vivo and response to somatostatin analog therapy with or without other antineoplastic treatments in advanced medullary thyroid carcinoma. *J Exp Clin Cancer Res*. 2004;23:549-59.
194. Zatelli MC, Piccin D, Tagliati F, Bottoni A, Luchin A, Vignali C, et al. Selective activation of somatostatin receptor subtypes differentially modulates secretion and viability in human medullary thyroid carcinoma primary cultures: potential clinical perspectives. *J Clin Endocrinol Metab*. 2006;91:2218-24.
195. Mahler C, Verhelst J, de Longueville M, Harris A. Long-term treatment of metastatic medullary thyroid carcinoma with the somatostatin analogue octreotide. *Clin Endocrinol (Oxf)*. 1990;33:261-9.
196. Lorenz K, Brauckhoff M, Behrmann C, Sekulla C, Ukkat J, Brauckhoff K, et al. Selective arterial chemoembolization for hepatic metastases from medullary thyroid carcinoma. *Surgery*. 2005;138:986-93.
197. Fromigue J, De Baere T, Baudin E, Dromain C, Leboulleux S, Schlumberger M. Chemoembolization for liver metastases from medullary thyroid carcinoma. *J Clin Endocrinol Metab*. 2006;91:2496-9.
198. Ilias I, Torpy DJ, Pacak K, Mullen N, Wesley RA, Nieman LK. Cushing's syndrome due to ectopic corticotropin secretion: twenty years' experience at the National Institutes of Health. *J Clin Endocrinol Metab*. 2005;90:4955-62.
199. Smallridge RC, Bourne K, Pearson BW, Van Heerden JA, Carpenter PC, Young WF. Cushing's syndrome due to medullary thyroid carcinoma: diagnosis by proopiomelanocortin messenger ribonucleic acid in situ hybridization. *J Clin Endocrinol Metab*. 2003;88:4565-8.
200. Winquist EW, Laskey J, Crump M, Khamis F, Shepherd FA. Ketoconazole in the management of paraneoplastic Cushing's syndrome secondary to ectopic adrenocorticotropin production. *J Clin Oncol*. 1995;13:157-64.
201. Barroso-Sousa R, Lerario AM, Evangelista J, Papadia C, Lourenço DM Jr, Lin CS, et al. Complete resolution of hypercortisolism with sorafenib in a patient with advanced medullary thyroid carcinoma and ectopic ACTH (adrenocorticotrophic hormone) syndrome. *Thyroid*. 2014;24(6):1062-6.
202. Terezakis SA, Lee KS, Ghossein RA, Rivera M, Tuttle RM, Wolden SL, et al. Role of external beam radiotherapy in patients with advanced or recurrent nonanaplastic thyroid cancer: Memorial Sloan-Kettering Cancer Center experience. *Int J Radiat Oncol Biol Phys*. 2009;73:795-801.
203. Schwartz DL, Rana V, Shaw S, Yazbeck C, Ang KK, Morrison WH, et al. Postoperative radiotherapy for advanced medullary thyroid cancer--local disease control in the modern era. *Head Neck*. 2008;30:883-8.
204. Brierley J, Sherman E. The role of external beam radiation and targeted therapy in thyroid cancer. *Semin Radiat Oncol*. 2012;22(3):254-62.
205. Brierley J, Tsang R, Simpson WJ, Gospodarowicz M, Sutcliffe S, Panzarella T. Medullary thyroid cancer: analyses of survival and prognostic factors and the role of radiation therapy in local control. *Thyroid*. 1996;6:305-10.
206. Hartsell WF, Scott CB, Bruner DW, Scarantino CW, Ivker RA, Roach M 3rd, et al. Randomized trial of short- versus long-course radiotherapy for palliation of painful bone metastases. *J Natl Cancer Inst*. 2005;97(11):798-804.
207. Masala S, Manenti G, Roselli M, Mammucari M, Bartolucci DA, Formica V, et al. Percutaneous combined therapy for painful sternal metastases: a radiofrequency thermal ablation (RFTA) and cementoplasty protocol. *Anticancer Res*. 2007;27:4259-62.
208. Nocera M, Baudin E, Pellegriti G, Cailleux AF, Mechelany-Corone C, Schlumberger M. Treatment of advanced medullary thyroid cancer with an alternating combination of doxorubicin-streptozocin and 5 FU-dacarbazine. *Groupe d'Etude des Tumeurs a Calcitonine (GETC)*. *Br J Cancer*. 2000;83:715-8.
209. Frame J, Kelsen D, Kemeny N, Cheng E, Niedzwiecki D, Heelan R, et al. A phase II trial of streptozotocin and adriamycin in advanced APUD tumors. *Am J Clin Oncol*. 1988;11(4):490-5.
210. Bajetta E, Rimassa L, Carnaghi C, Seregni E, Ferrari L, Di Bartolomeo M, et al. 5-Fluorouracil, dacarbazine, and epirubicin in the treatment of patients with neuroendocrine tumors. *Cancer*. 1998;15:83(2):372-8.
211. De Besi P, Busnardo B, Toso S, Girelli ME, Nacamulli D, Simioni N, et al. Combined chemotherapy with bleomycin, adriamycin, and platinum in advanced thyroid cancer. *J Endocrinol Invest*. 1991;14:475-80.
212. Schlumberger M, Abdelmoumene N, Delisle MJ, Couette JE. Treatment of advanced medullary thyroid cancer with an alternating combination of 5 FU-streptozocin and 5 FU-dacarbazine. *The Groupe d'Etude des Tumeurs a Calcitonine (GETC)*. *Br J Cancer*. 1995;71:363-5.
213. Dvorak HF. Vascular permeability factor/vascular endothelial growth factor: a critical cytokine in tumor angiogenesis and a potential target for diagnosis and therapy. *J Clin Oncol*. 2002;20:4368-80.
214. Braga-Basaria M, Ringel MD. Clinical review 158: beyond radioiodine: a review of potential new therapeutic approaches for thyroid cancer. *J Clin Endocrinol Metab*. 2003;88:1947-60.
215. Capp C, Wajner SM, Siqueira DR, Brasil BA, Meurer L, Maia AL. Increased expression of vascular endothelial growth factor and its receptors, VEGFR-1 and VEGFR-2, in medullary thyroid carcinoma. *Thyroid*. 2010;20:863-71.
216. McMahon G. VEGF receptor signaling in tumor angiogenesis. *Oncologist*. 2000;5:3-10.
217. Ferrara N. Vascular endothelial growth factor as a target for anti-cancer therapy. *Oncologist*. 2004;9:2-10.
218. Ryan AJ, Wedge SR. ZD6474--a novel inhibitor of VEGFR and EGFR tyrosine kinase activity. *Br J Cancer*. 2005;92:S6-13.
219. Therasse P, Arbutk SG, Eisenhauer EA, Wanders J, Kaplan RS, Rubinstein L, et al. New guidelines to evaluate the response to treatment in solid tumors. European Organization for Research and Treatment of Cancer, National Cancer Institute of the United States, National Cancer Institute of Canada. *J Natl Cancer Inst*. 2000;92:205-16.
220. Carlomagno F, Vitagliano D, Guida T, Ciardiello F, Tortora G, Vecchio G, et al. ZD6474, an orally available inhibitor of KDR tyrosine kinase activity, efficiently blocks oncogenic RET kinases. *Cancer Res*. 2002;62:7284-90.



221. Wedge SR, Ogilvie DJ, Dukes M, Kendrew J, Chester R, Jackson JA, et al. ZD6474 inhibits vascular endothelial growth factor signaling, angiogenesis, and tumor growth following oral administration. *Cancer Res.* 2002;62:4645-55.
222. Wells SA Jr, Robinson BG, Gagel RF, Dralle H, Fagin JA, Santoro M, et al. Vandetanib in patients with locally advanced or metastatic medullary thyroid cancer: a randomized, double-blind phase III trial. *J Clin Oncol.* 2012;30:134-41.
223. Thornton K, Kim G, Maher VE, Chattopadhyay S, Tang S, Moon YJ, et al. Vandetanib for the treatment of symptomatic or progressive medullary thyroid cancer in patients with unresectable locally advanced or metastatic disease: U.S. Food and Drug Administration drug approval summary. *Clin Cancer Res.* 2012;18(14):3722-30.
224. Robinson BG, Paz-Ares L, Krebs A, Vasselli J, Haddad R. Vandetanib (100 mg) in patients with locally advanced or metastatic hereditary medullary thyroid cancer. *J Clin Endocrinol Metab.* 2010;95(6):2664-71.
225. Fox E, Widemann BC, Chuk MK, Marcus L, Aikin A, Whitcomb PO, et al. Vandetanib in children and adolescents with multiple endocrine neoplasia type 2B associated medullary thyroid carcinoma. *Clin Cancer Res.* 2013;19(15):4239-48.
226. Cooper MR, Yi SY, Alghamdi W, Shaheen DJ, Steinberg M. Vandetanib for the treatment of medullary thyroid carcinoma. *Ann Pharmacother.* 2014 Mar;48(3):387-94.
227. Carlomagno F, Guida T, Anaganti S, Vecchio G, Fusco A, Ryan AJ, et al. Disease associated mutations at valine 804 in the RET receptor tyrosine kinase confer resistance to selective kinase inhibitors. *Oncogene.* 2004;23:6056-63.
228. Elisei R, Schlumberger MJ, Müller SP, Schöffski P, Brose MS, Shah MH, et al. Cabozantinib in progressive medullary thyroid cancer. *J Clin Oncol.* 2013;31(29):3639-46.
229. Hart CD, De Boer RH. Profile of cabozantinib and its potential in the treatment of advanced medullary thyroid cancer. *Onco Targets Ther.* 2013;6:1-7.
230. Polverino A, Coxon A, Starnes C, Diaz Z, DeMelfi T, Wang L, et al. AMG 706, an oral, multikinase inhibitor that selectively targets vascular endothelial growth factor, platelet-derived growth factor, and kit receptors, potentially inhibits angiogenesis and induces regression in tumor xenografts. *Cancer Res.* 2006;66:8715-21.
231. Schlumberger MJ, Elisei R, Bastholt L, Wirth LJ, Martins RG, Locati LD, et al. Phase II study of safety and efficacy of motesanib in patients with progressive or symptomatic, advanced or metastatic medullary thyroid cancer. *J Clin Oncol.* 2009;27:3794-801.
232. Wilhelm SM, Carter C, Tang L, Wilkie D, McNabola A, Rong H, et al. BAY 43-9006 exhibits broad spectrum oral antitumor activity and targets the RAF/MEK/ERK pathway and receptor tyrosine kinases involved in tumor progression and angiogenesis. *Cancer Res.* 2004;64:7099-109.
233. Lam ET, Ringel MD, Kloos RT, Prior TW, Knopp MV, Liang J, et al. Phase II clinical trial of sorafenib in metastatic medullary thyroid cancer. *J Clin Oncol.* 2010;28:2323-30.
234. Broutin S, Ameur N, Lacroix L, Robert T, Petit B, Oumata N, et al. Identification of soluble candidate biomarkers of therapeutic response to sunitinib in medullary thyroid carcinoma in preclinical models. *Clin Cancer Res.* 2011;17:2044-54.
235. Chow LQ, Eckhardt SG. Sunitinib: from rational design to clinical efficacy. *J Clin Oncol.* 2007;25:884-96.
236. Carr LL, Mankoff DA, Goulart BH, Eaton KD, Capell PT, Kell EM, et al. Phase II study of daily sunitinib in FDG-PET-positive, iodine-refractory differentiated thyroid cancer and metastatic medullary carcinoma of the thyroid with functional imaging correlation. *Clin Cancer Res.* 2010;16:5260-8.
237. Inai T, Mancuso M, Hashizume H, Baffert F, Haskell A, Baluk P, et al. Inhibition of vascular endothelial growth factor (VEGF) signaling in cancer causes loss of endothelial fenestrations, regression of tumor vessels, and appearance of basement membrane ghosts. *Am J Pathol.* 2004;165:35-52.
238. Cohen EE, Rosen LS, Vokes EE, Kies MS, Forastiere AA, Worden FP, et al. Axitinib is an active treatment for all histologic subtypes of advanced thyroid cancer: results from a phase II study. *J Clin Oncol.* 2008;26:4708-13.
239. de Groot JW, Plaza Menacho I, Schepers H, Drenth-Diephuis LJ, Osinga J, Plukker JT, et al. Cellular effects of imatinib on medullary thyroid cancer cells harboring multiple endocrine neoplasia Type 2A and 2B associated RET mutations. *Surgery.* 2006;139:806-14.
240. Frank-Raue K, Fabel M, Delorme S, Haberkorn U, Raue F. Efficacy of imatinib mesylate in advanced medullary thyroid carcinoma. *Eur J Endocrinol.* 2007;157:215-20.
241. de Groot JW, Zonnenberg BA, van Ufford-Mannesse PQ, de Vries MM, Links TP, Lips CJ, et al. A phase II trial of imatinib therapy for metastatic medullary thyroid carcinoma. *J Clin Endocrinol Metab.* 2007;92:3466-9.
242. Barroso-Sousa R, Lerario AM, Bezerra JE, Lourenço DM, Papadia C, Lin CS, et al. Complete resolution of hypercortisolism with sorafenib in a patient with advanced medullary thyroid carcinoma and ectopic ACTH syndrome. *Thyroid.* 2014;24(6):1062-6.
243. Ferreira CV, Siqueira DR, Ceolin L, Maia AL. Advanced medullary thyroid cancer: pathophysiology and management. *Cancer Manag Res.* 2013;5:57-66.
244. Wells SA Jr, Gosnell JE, Gagel RF, Moley J, Pfister D, Sosa JA, et al. Vandetanib for the treatment of patients with locally advanced or metastatic hereditary medullary thyroid cancer. *J Clin Oncol.* 2010;28:767-72.
245. Scheffel RS, Dora JM, Siqueira DR, Burtet LM, Cerski MR, Maia AL. Toxic cardiomyopathy leading to fatal acute cardiac failure related to vandetanib: a case report with histopathological analysis. *Eur J Endocrinol.* 2013;168:K51-4.
246. Kurzrock R, Sherman SI, Ball DW, Forastiere AA, Cohen RB, Mehra R, et al. Activity of XL184 (Cabozantinib), an oral tyrosine kinase inhibitor, in patients with medullary thyroid cancer. *J Clin Oncol.* 2011;29:2660-6.
247. Ahmed M, Barbachano Y, Riddell A, Hickey J, Newbold KL, Viros A, et al. Analysis of the efficacy and toxicity of sorafenib in thyroid cancer: a phase II study in a UK based population. *Eur J Endocrinol.* 2011;165:315-22.
248. Lenihan DJ, Cardinale DM. Late cardiac effects of cancer treatment. *J Clin Oncol.* 2012;30:3657-64.
249. Bodei L, Handkiewicz-Junak D, Grana C, Mazzetta C, Rocca P, Bartolomei M, et al. Receptor radionuclide therapy with <sup>90</sup>Y-DOTATOC in patients with medullary thyroid carcinomas. *Cancer Biother Radiopharm.* 2004;19:65-71.
250. Chatal JF, Campion L, Kraeber-Bodere F, Bardet S, Vuillez JP, Charbonnel B, et al. Survival improvement in patients with medullary thyroid carcinoma who undergo pretargeted anti-carcinoembryonic-antigen radioimmunotherapy: a collaborative study with the French Endocrine Tumor Group. *J Clin Oncol.* 2006;24:1705-11.
251. Wu K, Hou SM, Huang TS, Yang RS. Thyroid carcinoma with bone metastases: a prognostic factor study. *Clin Med Oncol.* 2008;2:129-34.
252. Farooki A, Leung V, Tala H, Tuttle RM. Skeletal-related events due to bone metastases from differentiated thyroid cancer. *J Clin Endocrinol Metab.* 2012;97:2433-9.
253. Lipton A, Theriault RL, Hortobagyi GN, Simeone J, Knight RD, Mellars K, et al. Pamidronate prevents skeletal complications and is effective palliative treatment in women with breast carcinoma and osteolytic bone metastases: long term follow-up of two randomized, placebo-controlled trials. *Cancer.* 2000;88:1082-90.

254. Vitale G, Fonderico F, Martignetti A, Caraglia M, Ciccarelli A, Nuzzo V, et al. Pamidronate improves the quality of life and induces clinical remission of bone metastases in patients with thyroid cancer. *Br J Cancer*. 2001;84:1586-90.
255. Ding X, Fan Y, Ma F, Li Q, Wang J, Zhang P, et al. Prolonged administration of bisphosphonates is well-tolerated and effective for skeletal-related events in Chinese breast cancer patients with bone metastasis. *Breast*. 2012;21:544-9.
256. Beuselinck B, Wolter P, Karadimou A, Elaidi R, Dumez H, Rogiers A, et al. Concomitant oral tyrosine kinase inhibitors and bisphosphonates in advanced renal cell carcinoma with bone metastases. *Br J Cancer*. 2012;107:1665-71.
257. Orita Y, Sugitani I, Toda K, Manabe J, Fujimoto Y. Zoledronic acid in the treatment of bone metastases from differentiated thyroid carcinoma. *Thyroid*. 2011;21:31-5.
258. Akyildiz HY, Mitchell J, Milas M, Siperstein A, Berber E. Laparoscopic radiofrequency thermal ablation of neuroendocrine hepatic metastases: long-term follow-up. *Surgery*. 2010;148(6):1288-93.
259. Mazzaglia PJ, Berber E, Milas M, Siperstein AE. Laparoscopic radiofrequency ablation of neuroendocrine liver metastases: a 10-year experience evaluating predictors of survival. *Surgery*. 2007;142(1):10-9.
260. Bezjak A. Palliative therapy for lung cancer. *Semin Surg Oncol*. 2003;21:138-47.
261. Börcek P, Asa SL, Gentili F, Ezzat S, Kiehl TR. Brain metastasis from medullary thyroid carcinoma. *BMJ Case Rep*. 2010 Dec 29;2010.
262. McWilliams RR, Giannini C, Hay ID, Atkinson JL, Stafford SL, Buckner JC. Management of brain metastases from thyroid carcinoma: a study of 16 pathologically confirmed cases over 25 years. *Cancer*. 2003;98:356-62.
263. Chiu AC, Delpassand ES, Sherman SI. Prognosis and treatment of brain metastases in thyroid carcinoma. *J Clin Endocrinol Metab*. 1997;82:3637-42.
264. Finny P, Jacob JJ, Thomas N, Philip J, Rajarathnam S, Oommen R, et al. Medullary thyroid carcinoma: a 20-year experience from a centre in South India. *ANZ J Surg*. 2007;77:130-4.