



UNICAMP

MARIANNE DE VASCONCELOS CARVALHO

**“HISTOPATHOLOGICAL AND IMMUNOHISTOCHEMICAL
ANALYSIS OF ORAL KAPOSI SARCOMA AND THYROID GLAND
IN AIDS”**

***“ESTUDO HISTOPATOLÓGICO E IMUNOISTOQUÍMICO DE
SARCOMA DE KAPOSI ORAL E GLÂNDULA TIREÓIDE DE
PACIENTES COM AIDS”***

PIRACICABA

2013



UNIVERSIDADE ESTADUAL DE CAMPINAS
FACULDADE DE ODONTOLOGIA DE PIRACICABA

MARIANNE DE VASCONCELOS CARVALHO

**“HISTOPATHOLOGICAL AND IMMUNOHISTOCHEMICAL
ANALYSIS OF ORAL KAPOSI SARCOMA AND THYROID GLAND
IN AIDS”**

Orientador: Prof. Dr. Pablo Agustin Vargas

***“ESTUDO HISTOPATOLÓGICO E IMUNOISTOQUÍMICO DE
SARCOMA DE KAPOSI ORAL E GLÂNDULA TIREÓIDE DE
PACIENTES COM AIDS”***

Tese de Doutorado apresentada ao Programa de Estomatopatologia da Faculdade de Odontologia de Piracicaba da Unicamp para a obtenção do título de Doutora em Estomatopatologia na área de Patologia.

Doctorate thesis presented to the Stomatopathology Postgraduation Programme of the Piracicaba Dental School of the University of Campinas to obtain the Ph.D. grade in Stomatopathology in the area of Pathology.

ESTE EXEMPLAR CORRESPONDE À VERSÃO FINAL DA
TESE DEFENDIDA PELA ALUNA MARIANNE DE
VASCONCELOS CARVALHO E ORIENTADA PELO PROF. DR.
PABLO AGUSTIN VARGAS

Assinatura do Orientador

PIRACICABA

2013

FICHA CATALOGRÁFICA ELABORADA POR
JOSIDELMA F COSTA DE SOUZA – CRB8/5894 - BIBLIOTECA DA
FACULDADE DE ODONTOLOGIA DE PIRACICABA DA UNICAMP

C253e Carvalho, Marianne de Vasconcelos, 1982-
Estudo histopatológico e imunoistoquímico de sarcoma de
Kaposi oral e glândula tireóide de pacientes com Aids / Marianne
de Vasconcelos Carvalho. -- Piracicaba, SP : [s.n.], 2013.

Orientador: Pablo Agustin Vargas.

Tese (Doutorado) - Universidade Estadual de Campinas,
Faculdade de Odontologia de Piracicaba.

1. Autópsia. 2. HIV. I. Vargas, Pablo Agustin, 1973-II.
Universidade Estadual de Campinas. Faculdade de
Odontologia de Piracicaba. III. Título.

Informações para a Biblioteca Digital

Título em Inglês: Histopathological and immunohistochemical analysis of
oral Kaposi sarcoma and thyroid gland in AIDS

Palavras-chave em Inglês:

Autopsy

HIV

Área de concentração: Patologia

Titulação: Doutora em Estomatopatologia

Banca examinadora:

Pablo Agustin Vargas [Orientador]

Lélia Maria Guedes Queiroz

Ana Carolina Prado Ribeiro

Jorge Esquiche León

Jacks Jorge Junior

Data da defesa: 01-03-2013


Programa de Pós-Graduação: Estomatopatologia



UNIVERSIDADE ESTADUAL DE CAMPINAS
Faculdade de Odontologia de Piracicaba




A Comissão Julgadora dos trabalhos de Defesa de Tese de Doutorado, em sessão pública realizada em 01 de Março de 2013, considerou a candidata MARIANNE DE VASCONCELOS CARVALHO aprovada.



Prof. Dr. PABLO AGUSTIN VARGAS



Profa. Dra. LÉLIA MARIA GUEDES QUEIROZ



Profa. Dra. ANA CAROLINA PRADO RIBEIRO



Prof. Dr. JORGE ESQUICHE LEÓN



Prof. Dr. JACKS JORGE JUNIOR

DEDICATÓRIA

*A **DEUS**, por tornar possível a realização de mais esta etapa em minha vida.
Aos meus pais, **Silvio** e **Lusiana**. As duas pessoas mais cultas que eu conheço. Seus ensinamentos e estímulos aos estudos com certeza me fizeram trilhar esta via acadêmica.*

*Às minhas irmãs **Dani** e **Chris**, minhas melhores amigas, nós somos tão inseparáveis que esta tese deveria ter seus nomes também. E ao meu cunhado **Alberto**, um exemplo de dedicação e inteligência.*

*Aos meus sobrinhos **Julliana** (também afilhada), **Marcelinho**, **Marina**, **Guto** e **Betinho** e minha afilhada, **Maria Letícia**. Amo vocês!*

À minha família, avôs e avós (in memorian), tios e tias, padrinhos e madrinhas, primos e primas que são parte muito importante de minha vida.

Aos meus amigos, todos eles, que mesmo de longe, fazem parte dessa conquista.

AGRADECIMENTOS ESPECIAIS

*Ao meu querido orientador, **Professor Doutor Pablo Agustin Vargas**, por todo apoio e conhecimento que, brilhantemente, deu-me durante todo curso e, especialmente, pela confiança em mim depositada em todas as engrandecedoras oportunidades. A disponibilidade que sempre manifestou e a empatia com que recebeu as minhas ideias, foram o estímulo que me permitiu vencer as inseguranças deste processo. Obrigada pelos conselhos valiosos, pelo interesse e amizade com que sempre se dispôs a me orientar.*

AGRADECIMENTOS

A todos os profissionais da Faculdade de Odontologia de Piracicaba, da Universidade Estadual de Campinas.

*À **Professora Doutora Renata Cunha Matheus Rodrigues Garcia** coordenadora da Pós-Graduação da Faculdade de Odontologia de Piracicaba, da Universidade Estadual de Campinas.*

*Ao **Professor Doutor Jacks Jorge Júnior**, diretor da Faculdade de Odontologia de Piracicaba da Universidade de Campinas, pelo incentivo e colaboração durante minha formação acadêmica.*

*Ao **Professor Doutor Alan Roger Santos Silva**, coordenador do Programa de Pós-Graduação em Estomatopatologia. Fomos, por pouco tempo, colegas de pós-graduação e suas conquistas pós doutorado foram estimulantes. Agradeço ao amigo pelos seus valiosos ensinamentos, especialmente em Estomatologia, e pelos bons momentos de descontração.*

*Ao **Professor Doutor Ricardo Della Coletta**, por sua peculiar atenção e disponibilidade sempre, tanto no papel de coordenador como no papel de professor. Agradeço pelos seus valiosos ensinamentos no laboratório de Biologia Molecular.*

*Aos **Professores Doutores Márcio Ajudarte Lopes, Oslei Paes de Almeida e Edgard Graner** pelos exemplos de pelo constante estímulo no desenvolvimento de minha carreira científica e acadêmica.*

*À **Professora Doutora Ana Carolina Prado Ribeiro** que me passou sua valiosa experiência no Laboratório de Patologia Oral, quando participamos juntas na rotina de histopatologia, sempre muito segura e delicada. Obrigada pela sua presteza e amizade.*

*Ao **Professor Doutor Jorge Esquiche León**, pelos seus valiosos ensinamentos, principalmente durante os agradáveis fins de semana na fotomicroscopia.*

*À amiga **Sibele Aquino**, pela sua fundamental ajuda, gentileza e disponibilidade durante os experimentos no laboratório de Biologia Molecular.*

*Às amigas, **Andreia Bufalino, Camilla Borges, Felipe Paiva, Marcondes Sena e Manoela Carrera** com quem não só dividi conhecimentos, como também momentos de muitas alegrias e conquistas durante nossa maravilhosa convivência. Amigos para toda a vida.*

Aos colegas pós-graduandos do Programa de Estomatopatologia da Faculdade de Odontologia de Piracicaba: **Adrielle Gouvêa Vasconcellos, Alan Roger dos Santos Silva, Alicia Rumayor Piña, Ana Camila Messetti, Ana Lucia Francisco, Ana Terezinha Mesquita, Andréia da Silva, Andréia Bufalino, Bruno de Andrade, Camila Beder, Camilla Borges Gomes, Daniel Berreta, Débora Bastos, Elizabete Bagordakis Pinto, Fabiana Seguin, Felipe Paiva Fonseca, Fernanda dos Santos Moreira, Fernanda Mariano, Harim Tavares dos Santos, Isadora Flores, José Laurentino Ferreira Filho, José Ribamar Sabino Júnior, Julianna Joanna Moraes, Juscelino de Freitas Jardim, Karina Moraes Faria, Katya Díaz, Lara Ramos Innocentini, Lays Martin Sobral, Lívia Maris Paranaíba, Luciana De Almeida, Mario Romañach, Manoela Carrera, Marco Antonio Carvalho, Marco Aurélio Andrade, Marcondes Sena Filho, Marisol Martinez, Michelle Agostini, Nathalia de Souza Lima, Patrícia Feio, Patrícia Abrahão, Priscila Campioni Rodrigues, Renato Hopp, Rogério Gondak, Rodrigo Neves Silva, Rose Ortega, Sabrina Nogueira De Moraes, Sibebe Aquino, Tânia Benetti Soares, Victor Hugo Toral Rizo, Wagner Gomes da Silva e Wilfredo Gonzalez Arriagada.**

Aos profissionais do Laboratório de Patologia Oral da Faculdade de Odontologia de Piracicaba, **Fabiana Facco Casarotti, João Carlos da Silva Júnior, Adriano Luis Martins** e em especial à **Geovania Almeida** pela disponibilidade e amizade. Aos profissionais do Orocentro da Faculdade de Odontologia de Piracicaba, **Rogério Andrade Elias, Aparecida Campion e Jeane da Costa**, bem como da Secretaria do Departamento de Diagnóstico Oral, **Luana Ganhor Alescio**.

Ao **Professor Doutor Willie van Heerden** e Patologista Oral **Belinda Bunn** do Departamento de Patologia Oral e Biologia Oral da Universidade de Pretoria, pela receptividade durante o período que estudei na África do Sul e pela valiosa colaboração ao ceder os casos para o desenvolvimento de parte deste estudo.

À **Professora Doutora Thais Mauad**, à **Doutora Sheila Siqueira** e ao **Dr René Gehard** do Departamento de Patologia da Faculdade de Medicina da Universidade de São Paulo, e, em especial ao **Doutor Leandro Liporoni** por ter participado gentilmente da leitura das lâminas. Obrigada pelo aprendizado, senso crítico e vasto conhecimento fornecido.

À minha querida ex-orientadora **Professora Doutora Lélia Maria Guedes Queiroz**, a qual participou e ainda participa da minha formação. Obrigada pela sua dedicação, orientação e paciência. Tomara que esta parceria e amizade continue sempre.

À **Fundação de Amparo à Pesquisa do Estado de São Paulo (FAPESP)** pelo auxílio concedido na forma de Bolsa de Doutorado (Processo: 2010/51803-8).

E, finalmente, obrigada a todos que fizeram parte, direta ou indiretamente, do meu doutoramento.

RESUMO

A síndrome da imunodeficiência adquirida (AIDS) é causada pelo vírus da imunodeficiência humana (HIV). A infecção já acometeu mais de 60 milhões de pessoas em todo o mundo e 25 milhões de mortes. Apesar dos progressos que a comunidade internacional obteve, a AIDS ainda é uma epidemia global e constitui um dos principais problemas de saúde pública mundial. À luz dessa afirmação, este trabalho se fundamenta na abordagem das manifestações dos pacientes com AIDS, dando foco a dois tópicos relativamente distintos, porém de bastante relevância. O primeiro deles se baseia na descrição inédita da diversidade morfológica do sarcoma de Kaposi oral (SKO), o qual é umas das manifestações mais comuns associadas ao HIV, com frequente envolvimento oral. Realizamos um estudo retrospectivo de 135 casos de SKO presentes nos arquivos da Universidade de Pretoria, África do Sul. Após a revisão histológica, o SKO foi classificado em 7 categorias com base no padrão predominante de crescimento, tais como: sólido, limfangioma-like, telangiectásico, desmoplásico, linfangiectático, equimótico e anaplásico. O significado prognóstico dessas variantes ainda precisará ser determinado, e o reconhecimento da diversidade morfológica do SKO é essencial para evitar erros diagnósticos. Em relação ao segundo capítulo, analisamos 100 tireóides obtidas de autópsias de pacientes com AIDS do Departamento de Patologia da Faculdade de Medicina da Universidade de São Paulo. Os casos foram analisados sistematicamente, a fim de determinar a frequência e as principais patologias presentes nesta glândula. Micobacteriose foi a infecção mais freqüente, seguida por citomegalovírus (CMV) e criptococose. Envolvimento da glândula tireóide ocorreu geralmente como uma parte da disseminação da doença. Os médicos devem ter atenção especial para a detecção de sinais precoces de doenças na tireóide, que podem ser confundidos com sintomas gerais de manifestações da AIDS.

Palavras-chave: Sarcoma de Kaposi oral, glândula tireóide, autópsia, HIV, AIDS.

ABSTRACT

The acquired immunodeficiency syndrome (AIDS) is caused by the human immunodeficiency virus (HIV). The infection has affected more than 60 million people around the world and over 25 million deaths. Despite the progress of the international community, AIDS is still a global epidemic and is a considerable public health problem worldwide. Due to this, this work is based on the approach of the manifestations of AIDS patients, focusing to two relatively distinct topics, but to much relevant. The first description is based on the unpublished morphological diversity oral Kaposi's sarcoma (OKS), which is one of the most common HIV manifestations, with frequent oral involvement. We performed a retrospective study of 135 cases of OKS retrieved from the archives of the University of Pretoria, South Africa. After histological review, the OKSs were classified into 7 categories based on the predominant pattern of growth, such as solid, lymphangioma-like, telangiectatic, desmoplastic, lymphangiectatic, ecchymotic, and anaplastic. Although the prognostic significance of these variants is yet to be determined, the appreciation and recognition of such morphologic diversity remains essential in distinguishing these lesions from possible mimickers. Regarding the second chapter, we analyzed 100 thyroid obtained from autopsies of patients with AIDS, Department of Pathology, Faculty of Medicine, University of São Paulo. The cases were systematically analyzed in order to determine the frequency and the main pathological features of the gland. Mycobacteriosis infection was the most frequent, followed by cytomegalovirus (CMV) and cryptococcosis. Involvement of the thyroid gland usually occurred as a part of dissemination of the disease. Physicians should pay special attention to the early signs of thyroid disease, which can be misdiagnosed with symptoms of general manifestations of AIDS.

Keywords: Oral Kaposi sarcoma. Thyroid gland, autopsy, HIV, AIDS.

SUMÁRIO

INTRODUÇÃO	1
CAPÍTULO 1: The microscopic diversity of oral kaposi sarcoma	7
CAPÍTULO 2: Thyroid gland involvement in advanced AIDS. An autopsy-based study.	27
REFERÊNCIAS	52

INTRODUÇÃO

Epidemiologia da AIDS

A síndrome da imunodeficiência adquirida (AIDS) foi descrita primeiramente em 1981 nos Estados Unidos da América, e é causada pelo vírus da imunodeficiência humana (HIV). A infecção pelo HIV é considerada uma pandemia e já acometeu mais de 60 milhões de pessoas em todo o mundo, além de ter provocado a morte de cerca de 25 milhões. Atualmente, há cerca de 34 milhões de pessoas infectadas pelo HIV no mundo. A África do Sul é o país com o maior número de pessoas soropositivas para o HIV (5,6 milhões), o que corresponde a 16,5% da população mundial infectada pelo HIV e 11,5% da população total do país. Em um ranking de 150 países, o Brasil ocupa a 16ª posição em número de pessoas soropositivas, com 490 mil infectadas, o que corresponde a 1,5% da população mundial infectada pelo HIV e 0,3% da população brasileira (UNAIDS, 2012). Segundo as estimativas, o número de pessoas vivendo com HIV com acesso ao tratamento aumentou e novas infecções pelo HIV caíram (UNAIDS, 2012). Entretanto, o HIV/AIDS ainda constitui um dos principais problemas de saúde pública brasileira e mundial, tendo ainda muito a ser feito. No Brasil, por exemplo, a taxa de prevalência da infecção pelo HIV na população jovem apresenta tendência de aumento (Ministério da Saúde, Brasil, 2012). Os dados obtidos confirmam a disposição de queda na epidemia no Brasil, porém desperta para a urgência de ações estratégicas em várias regiões do país e populações vulneráveis.

Etiopatogenia da AIDS

O HIV é um retrovírus humano, pertencente a família dos lentivírus. É um vírus esférico com núcleo eletrodens rodeado por um capsídeo protéico, que é envolvido por um envelope lipídico derivado da célula infectada. No envelope lipídico há duas glicoproteínas, gp120 e gp 41, que são fundamentais para a infecção das células pelo HIV. A gp120 presente na membrana do HIV tem

afinidade pelas moléculas CD4+ dos linfócitos T, importante células de defesa do organismo. Esta ligação faz com que haja uma mudança conformacional na gp120, fazendo com que esta se ligue a co-receptores do linfócito T, conhecidos como CCR5 (receptores das β -quimiocinas) e CXCR4 (receptores de α -quimiocinas). Esta ligação GP120-CD4-CCR5/CXCR4 faz com que haja uma mudança conformacional da proteína gp41, expondo dessa forma o peptídeo de fusão do vírus, fazendo com que a membrana viral se fusione à membrana do linfócito, permitindo dessa forma a entrada do RNA viral no interior da célula. Uma vez dentro da célula, o RNA viral sofre transcrição reversa, levando a formação de cDNA (DNA pró-viral), através da enzima transcriptase reversa do vírus. Através da enzima integrase, o cDNA se integra ao DNA da célula hospedeira. Este por sua vez, produz mais RNA viral e, através da enzima protease, traduz proteínas do nucleocapsídeo viral. Desta forma, no interior do linfócito TCD4+, o vírus tem quase todos os componentes estruturais: o RNA viral e seu nucleocapsídeo. Ao sair do linfócito, esta estrutura viral é encapsulada pela membrana celular, a qual já tem presente as proteínas gp120 e gp41. Após esta etapa, a estrutura viral está completamente formada, pronta para infectar novos linfócitos TCD4+. Todo este processo promove a destruição e comprometimento da função dessas células importantes de defesa, afetando primariamente a imunidade celular, caracterizando a imunodepressão profunda sofrida pelos pacientes infectados pelo HIV e portadores da AIDS (Cayabyab *et al.*, 2004; Abbas *et al.*, 2008; Kumar *et al.*, 2008).

Vias de transmissão do HIV

O HIV pode ser transmitido através do contato sexual, pela transmissão parenteral e vertical. Apesar da predominância da transmissão via relação homossexual masculina no início da epidemia, a transmissão via relação heterossexual é o modo predominante de infecção pelo mundo atualmente. A transmissão parenteral do HIV ocorre em três grupos de indivíduos: usuários de drogas intravenosas, hemofílicos que receberam concentrado de fator VIII e

receptores aleatórios de transfusões de sangue. Os usuários de drogas intravenosas são de longe o maior grupo, ocorrendo à transmissão pelo compartilhamento de agulhas, seringas e outros instrumentos contaminados com sangue contendo HIV (Kumar *et al.*, 2008). A transmissão vertical ocorre pela passagem do vírus das mães infectadas para seus filhos, a qual pode ocorrer por três vias: no útero, por contágio transplacentário; durante o parto, pelo canal de parto infectado; após o nascimento, pela ingestão de leite materno. Na ausência de qualquer intervenção, a taxa de transmissão do HIV se situa em torno de 30%, podendo ser reduzida em mais de 60% pelo uso de antirretrovirais durante a gestação ((Ministério da Saúde, Brasil, 2012).

AIDS e sarcoma de Kaposi oral

As manifestações da cabeça e pescoço estão entre as complicações mais comuns presentes em pacientes infectados pelo HIV. Algumas destas manifestações são os sinais iniciais da infecção, e outras estão associadas ao desenvolvimento da AIDS (Vargas *et al.*, 2003). As manifestações orais são as mais frequentes, e podem representar importantes marcadores clínicos do início da progressão da síndrome, como também da falha/resistência do tratamento antirretroviral (Sasco *et al.*, 2010). As manifestações mais comuns são as infecções por fungos, protozoários, bactérias, vírus e neoplasias (Vargas *et al.*, 2003)

O sarcoma de Kaposi (SK) epidêmico é uma das manifestações mais frequente dos pacientes com AIDS. Considerada uma neoplasia de origem vascular, a sua etiologia está estritamente relacionada à infecção pelo herpes vírus humano-8 (HHV-8). Em 22% dos casos de SK, a cavidade oral é o sítio primário de acometimento. A razão disto pode ser pelo fato de a saliva possuir altos níveis de HHV-8 em relação ao sangue, fluidos genitais e região anal (Ramírez-Amador *et al.*, 2010).

O SK associado a AIDS tem pobre prognóstico, apresentando-se uma neoplasia agressiva, podendo ter consequências potencialmente fatais. Após o surgimento do tratamento com antirretrovirais, principalmente a terapia antirretroviral altamente ativa (highly active antiretroviral treatment – HAART) o prognóstico melhorou significativamente, assim como a incidência, ocorrendo principalmente em pessoas com imunodeficiência grave não tratada (Sasco *et al.*, 2010).

AIDS e a glândula tireóide

Desde a descrição inicial da AIDS, tem havido informações crescentes sobre os efeitos do HIV no sistema endócrino, como na glândula adrenal, pituitária e tireóide, pâncreas e gônadas. Em pacientes que se encontram em estágios avançados da AIDS, condições que infectam e infiltram o sistema endócrino podem alterar a sua funcionalidade (Unachukwu *et al.*, 2009).

As principais patologias endócrinas em pacientes portadores do HIV incluem, principalmente, infecções oportunistas e neoplasias malignas, sendo estas últimas ocorrendo com menor frequência (Bonnyns & Bourdoux, 1995; Lima *et al.*, 1998; Basílio-de-Oliveira, 2000). Entretanto, em muitos casos, a ausência ou a não especificidade dos sinais e sintomas dessas patologias, especialmente as que envolvem a tireóide, dificultam o seu diagnóstico (Basílio-de-Oliveira, 2000; Rosenfeld & Reddy, 2001; Kiertiburanakul *et al.*, 2003).

Dessa forma, dados que dizem respeito à prevalência das lesões tireoidianas geralmente são oriundos de alguns poucos estudos de autópsias de pacientes que foram a óbito devido às complicações da AIDS (Lima *et al.*, 1998; Basílio-de-Oliveira, 2000). Esses estudos apontam que o envolvimento da tireóide não é um evento raro (Basílio-de-Oliveira, 2000), podendo estar presente em cerca de dois terços dos casos de autópsias (Lima *et al.*, 1998). Além disso, alguns relatos de casos isolados ou série de casos têm sido publicados (Frank *et al.*, 1987; Jinno *et al.*, 2012).

Desde a sua descrição inicial, tem havido informações crescentes sobre os efeitos do HIV na tireóide. A morbidade e mortalidade dos pacientes HIV positivos, especialmente os que se encontram nos estágios mais avançados da AIDS podem ser reflexo de endocrinopatias (Rosenfeld & Reddy, 2001). A tireóide produz e secreta hormônios, como a tiroxina (T4) e a triiodotironina (T3), que exercem importantes efeitos, regulando o metabolismo e participando do controle da homeostase de diversos componentes do organismo (Kumar et al., 2008).

Tratamento da AIDS

Desde o início da epidemia da AIDS, muito tem sido feito para proporcionar melhor qualidade de vida aos portadores do HIV e, dentre outras ações, está a distribuição universal de medicamentos, ressaltando-se que o Brasil foi o primeiro país em desenvolvimento a adotar tal medida. É evidente a eficácia terapêutica, principalmente após a introdução do conceito da HAART, que é a combinação dos inibidores de protease e transcriptase reversa, de forma a ser extremamente efetiva na redução da carga viral plasmática de RNA-HIV para níveis indetectáveis. Ao mesmo tempo em que a epidemia continua a se disseminar mundialmente, especialmente na região da África Subsaariana, o impacto da HAART é indiscutível em tornar mais lento o curso da doença e prolongar a vida; isto se aplica, evidentemente, onde há terapia gratuita disponível (do Lago & Costa, 2010)

Em 2011, 8 milhões de pessoas receberam medicamentos contra a AIDS nos países com renda baixa e média, o que significa um aumento de 1,4 milhão em relação a 2010. No entanto, apenas 54% do total estimado em 15,8 milhões de pessoas que precisariam de tratamento, recebem os medicamentos (UNIAIDS, 2012).

Apesar dos progressos que a comunidade internacional obteve, a AIDS ainda é uma epidemia global. À luz dessa afirmação, este trabalho se fundamenta

principalmente na abordagem das manifestações dos pacientes com AIDS, dando foco a dois tópicos relativamente distintos, porém de bastante relevância com a perspectiva do aprimoramento de sua compreensão. O primeiro deles se baseia na descrição inédita da diversidade morfológica do sarcoma de Kaposi oral. Esta parte do estudo foi desenvolvida durante estágio de 3 meses realizado na *University of Pretoria*, na África do Sul, país com o maior contingente de pessoas infectadas pelo HIV no mundo, o qual foi financiado pela Fundação de Amparo à Pesquisa do Estado de São Paulo (FAPESP). A importância se deve a variedade de subtipos histológicos, os quais devem ser corretamente reconhecidos e a presença de patologias concomitantes, a fim de evitar erros diagnósticos com consequentes erros terapêuticos. Futuramente, os subtipos histológicos por nós sugeridos, poderão ser correlacionados com o prognóstico de SK.

O segundo faz uma abordagem das principais alterações morfológicas na glândula tireóide de pacientes que foram à óbito devido às complicações da AIDS. Este estudo foi desenvolvido em conjunto com o Departamento de Patologia da Faculdade de Medicina da Universidade de São Paulo. O objetivo é identificar as lesões que mais acometem a glândula e dessa forma promover a detecção precoce e tratamento adequado para essas alterações.

CAPÍTULO 1

Artigo publicado no periódico *Oral Surgery, Oral Medicine, Oral Pathology and Oral Radiology*, Vol. 115 No. 2, p.241-248, February 2013.

Microscopic diversity in oral Kaposi sarcoma

Belinda K. Bunn, BDS, FC path (SA) oral path,^a Marianne de Vasconcelos Carvalho, DDS, MSc,^b Melanie Louw, MBChB, MMed,^c Pablo A. Vargas, DDS, MSc, PhD,^b

Willie F. van Heerden, BChD, MChD, FC path(SA) oral path, PhD, DSc,^a

University of Pretoria and State University of Campinas

^aOral Pathologist, Department of Oral Pathology, Oral Biology, School of Dentistry, Faculty of Health Sciences, University of Pretoria, South Africa

^bOral Pathologist, Department of Oral Diagnosis, Piracicaba Dental School, State University of Campinas, Brazil.

^cPathologist, Department of Anatomical Pathology, School of Medicine, Faculty of Health Sciences, University of Pretoria, South Africa.

Reprint requests:

Willie F. P. van Heerden, PhD, DSc

Department of Oral Pathology, Oral Biology

PO Box 1266

Pretoria, South Africa

willie.vanheerden@up.ac.za

ABSTRACT

Kaposi sarcoma is the most common HIV-associated neoplasm, frequently presenting with oral mucosal involvement. This retrospective study aimed to assess and highlight the histomorphological spectrum of oral Kaposi sarcoma. A total of 135 cases diagnosed between 1990 and 2011 were retrieved from the archives of the Oral and Dental Hospital of the University of Pretoria, South Africa. Following histologic review, each case was placed into 1 of 7 categories based on the predominant pattern of growth. These histologic divisions included lesions designated as solid, lymphangioma-like, telangiectatic, desmoplastic, lymphangiectatic, ecchymotic, and anaplastic. The presence of coexistent pathology was identified in 25 cases, largely represented by superimposed candidiasis. Concomitant cytomegalovirus and non-necrotizing granulomatous inflammation were also observed. Although the prognostic significance of these variants is yet to be determined, the appreciation and recognition of such morphologic diversity remains essential in distinguishing these lesions from possible mimickers.

INTRODUCTION

Kaposi sarcoma (KS) is a locally aggressive endothelial tumour characterized by clinical and histologic heterogeneity.¹ The spectrum of biological behavior depends on the epidemiologic form of disease.^{2,3} The earliest classic form of KS as first described by Moritz Kaposi in 1872 runs a protracted yet indolent course.^{4,5} Iatrogenic KS (transplantation associated) occurs in patients on immunosuppressive therapy and expresses borderline to intermediate behavioral qualities. Endemic (African) KS and epidemic (HIV/AIDS associated) KS are far more aggressive, fulminant forms of disease, with potentially fatal consequences.⁶ Despite distinct pathogenetic mechanisms, all forms share the fundamental clinical and morphologic features that typify KS.^{2,3} The true malignant potential of KS remains contentious, with most lesions demonstrating attributes of reactive,

hyperplastic processes while the more clinically advanced and infiltrative lesions display qualities of a frankly malignant nature.⁷

Human herpes virus-8 (HHV-8) is implicated as the etiologic agent in all forms of disease, yet infection alone is inadequate for KS initiation and progression. Underlying immune suppression is generally a prerequisite for development of KS.^{3,8,9} Epidemic KS arising in the context of the HIV/AIDS pandemic remains the most frequent clinical form of disease characterized by the greatest malevolence and poorest prognosis. This is in part because of the presence of overwhelming coexistent neoplastic and infectious disease. Disseminated KS in the untreated HIV-positive patient heralds progression to AIDS with many of these patients failing to survive beyond 6 months.⁸ More than two-thirds of the global HIV-infected population resides in poverty-stricken regions of sub-Saharan Africa, with an estimated 5.6 million sufferers in South Africa alone.¹⁰ Epidemic KS thus constitutes the bulk of our surgical cases with almost no cases of the endemic type identified. Oral mucosal lesions of epidemic KS occur concurrently with cutaneous lesions in 71% of patients. The oral cavity represents the initial site of KS in up to 22% of cases, often being the first clinical indication of infection in previously undiagnosed individuals.^{5,11} Furthermore, oral Kaposi sarcoma (OKS) is prognostically significant in antiretroviral-naive patients, portending far greater mortality than KS in untreated patients with cutaneous lesions only.¹²⁻¹⁴

The microscopic features of KS are for the most part easy to recognize; nevertheless, the increasing number of morphologic variants as reported in cutaneous KS potentially presents a diagnostic obstacle for the histopathologist. Confounding this further in epidemic cases of KS is the presence of parallel pathology, often due to disseminated infections, occurring concomitantly in KS biopsy specimens. The aim of this study was to describe the multitude of growth patterns encountered in a series of OKS lesions, including documentation of a newly recognized microscopic variant, which we have termed desmoplastic KS (DKS). The presence of coexistent infectious pathology was also investigated.

Awareness of such histologic diversity facilitates distinction of OKS from possible mimickers, allowing for accurate, timely diagnosis and optimal patient management.

MATERIALS AND METHODS

All cases diagnosed histologically as OKS between 1990 and 2011 were retrieved from the departmental archives of the Oral and Dental Hospital of the University of Pretoria, South Africa. KS from extraoral sites and cases with diagnostic ambiguity were omitted from the study. The routine hematoxylin and eosin–stained sections were retrospectively analyzed by 2 independent examiners both separately and jointly so as to characterize the morphologic features. Morphology alone was diagnostic of KS in most cases. Immunohistochemistry, including CD31, CD34, D2-40, and HHV-8, was performed where confirmation of the diagnosis was needed (Table 1). Following histopathological analysis, the cases were categorized as 1 of 7 morphologic variants according to the predominant growth pattern, which constituted more than 50% of the total volume of lesional tissue. Clinical details pertaining to each case were recorded, based on evaluation of the histology request forms and diagnostic reports (Table 2).

RESULTS

A total of 135 cases were included in this study. Most patients were clinically suspected to be HIV-positive at the time of biopsy although many had never been formally tested. HHV-8 immunohistochemistry was positive in all cases evaluated (Figure 1, A). Lesions were multifocal, with surgical accessibility dictating the site of biopsy. There were no significant differences in gender distribution (F:M = 1.1:1.0), with a peak incidence recorded in the third and fourth decades (mean = 34 years).

Solid KS (n = 59; 44%) represented the most frequent morphologic category and comprised established, exophytic, ulcerated masses with a nodular to multinodular pattern of solid, uninterrupted growth. Lesions were diffusely cellular with organized fascicles of spindle cells and occasional storiform areas (Figure 1,

B). The compact vascular spaces were mostly slit-like with associated hemorrhage, hemosiderin deposits, eosinophilic globules and chronic inflammation identified in the adjacent connective tissue (Figure 1, *C*). Dense bands of chronically inflamed fibrous connective tissue separated the cellular nodules in multinodular lesions (Figure 1, *D*). Sporadic mitoses with little evidence of atypia were noted. Plump spindle cells had an epithelioid to sieve-like appearance when cut in cross section.

Lymphangioma-like KS (LLKS) constituted the second- largest OKS category (n = 23; 17%), the hallmark of this variant being the presence of irregular, angulated lymphatic channels lined by flattened endothelial cells (Figure 2, *A*). The lymphatic channels contained lymphatic fluid and admixed red blood cells. The loose intervening stroma comprised spindle cells, foci of hemorrhage, and minimal collagenous connective tissue. Conspicuous nodular aggregates of plasma cells were a distinctive feature in several cases, a trait not documented in cutaneous LLKS (Figure 2, *B*). LLKS lesions appeared to be extensive and established with evidence of infiltration and dissection of the connective tissue deep within the submucosa. The promontory sign was especially marked in these cases.

Telangiectatic KS (TKS) comprised similarly advanced, exophytic lesions with marked surface ulceration (n = 22; 16%). These cases had prominent, engorged, ectatic vascular spaces and abundant extravasational hemorrhage (Figure 2, *C*). An overall decrease in cellularity was appreciable. Hemosiderin deposits and eosinophilic globules were plentiful. Interspersed pockets of plasma cells as seen in oral LLKS were also noteworthy (Figure 2, *D*).

Fourteen (10%) of the cases in the present series showed unusual, unique histopathological features that have not been described before. These cases were designated desmoplastic KS (DKS). Lesions categorized as DKS demonstrated diffuse and extensive growth both laterally and vertically with deep submucosal infiltration indicative of lesional advancement. In addition, a consistent histologic finding was the presence of marked stromal desmoplasia. The lesions classified as DKS were clearly more developed than typical plaque forms. Unlike the typical nodular proliferations seen in established KS, DKS showed little circumscription

and little to no surface elevation clinically. The lesional components were markedly compressed by abundant intervening fibrous connective tissue (Figure 3, *A*). Although the lesions were all extensively infiltrative, cytologic atypia was consistently absent. Tumor infiltration of skeletal muscle exhibited a tessellated pattern reminiscent of proliferative myositis in some areas. Cellular infiltration of adjacent minor salivary glands and adipose tissue was evident. Smooth muscle actin (SMA) immunohistochemical staining showed focal positivity within the stromal fibroblastic component.

The last 3 descriptive categories in this series were lymphangiectatic KS (n = 12; 9%), ecchymotic KS (n = 3; 2%), and anaplastic KS (n = 2, 1.5%) (Table 2). Lymphangiectatic KS is a well-documented cutaneous lymphedematous variant with distinctive histopathological qualities. Low-power examination of lesions imparted a cribriform to “Swiss cheese”-like pattern (Figure 3, *B*). Discrete, rounded ectatic lymphatic channels lined by prominent endothelial cells with focal hobnailing interrupted the features of conventional KS. The lymphatic spaces were completely separate and disconnected from each other with no evidence of the anastomosing, jagged architecture that exemplify LLKS. Cases assigned the diagnosis of ecchymotic KS (EKS) were microscopically dominated by extravasational hemorrhage, which obscured the cellular KS component (Figure 3, *C*). Conventional features were focally present in all cases, which aided the final diagnosis. The 2 examples of anaplastic KS (AKS) described here showed considerable intralesional variation in morphology with no distinct pattern of predominance. There was widespread cytologic atypia, pleomorphism, and brisk mitotic activity. Both tumors had focal ectatic vasculature lined by cuboidal to hobnailed endothelial cells of variable size and high nuclear to cytoplasmic ratios (Figure 3, *D*).

Several angiosarcomatous regions were observed. Parallel pathology was observed in 25 cases, predominantly as concurrent superficially invasive candidiasis. One case contained a coexisting non-necrotizing granuloma, whereas an additional lesion demonstrated triple pathology in the form of cytomegalovirus

and *Candida* coinfection. Scattered plasma cells were a conspicuous microscopic finding in all of the histologic variants described; however, the presence of dense plasma cell pockets in LLKS, TKS, and some DKS cases constituted an additional unique feature of interest.

DISCUSSION

Contrary to the dramatic decline in the prevalence of KS observed within developed countries following introduction of successful highly active antiretroviral therapy (HAART), rates continue to surge in resourcepoor regions. The impact and effects are far reaching, being no more prevalent than in South Africa, which is currently home to more HIV-infected persons than any other country.^{5,7,8,10,11,15}

OKS is most prevalent in epidemic forms of disease, occurring at all stages of HIV infection. End-stage disease (AIDS) correlates strongly with a higher clinical prevalence with lesional aggression indicating immune deterioration, low CD4 cell count, and increased HHV-8 viral loads.^{11,15-17} The high incidence of OKS might be related to salivary shedding of HHV-8 viral particles at distinctly higher levels compared with plasma. HHV-8 may also be harbored within the oropharyngeal epithelium, allowing for replication and further increased salivary shedding.^{18,19}

Microscopic recognition of KS is seldom problematic, even in lesions with unconventional morphologies. The traditional features common to all forms of disease are almost invariably present at least focally. Incisional biopsies may, however, be non-representative, displaying areas with unusual morphology thereby hampering histopathological diagnosis. KS histopathology closely mirrors the clinical evolution of lesions. Early patch stage lesions are subtle and non-specific, presenting the most frequent diagnostic challenge. Focal, superficial, sparsely cellular vascular proliferations are typical. A vague lymphoplasmacytic perivascular inflammatory infiltrate is present.^{2,7,18,20,21} As lesions increase in size, becoming thicker and more plaque-like to nodular, an increase in vascularity and cellularity is noted microscopically. The proliferation of new blood vessels lacking pericytes accounts for the extravasational hemorrhage so intricately associated with KS. The

hemorrhage is accompanied by deposition of hemosiderin and scattered amorphous hyaline globules within and between lesional cells. The most conspicuous change is the appearance of a spindle cell component that extends between the lesional vasculature.^{2,7,18,21} The inflammatory component is a persistent constituent.²⁰ The so-called promontory sign is a classic feature of nodular stage KS and describes the presence of round, regular native blood vessels that protrude into the irregular, compressed lumina of lesional vessels.^{2,7,18,21-23} The mucosal surface in OKS is often ulcerated with associated pyogenic membrane formation, neutrophilic inflammation, and granulation tissue that blend with the underlying lesional KS component.

OKS, much like its cutaneous counterpart, presents with a multitude of histopathological patterns, some of which have been alluded to in earlier studies.²¹ A similar array of morphologies was noted in this series of OKS together with recognition of a new microscopic variant in the form of DKS.

Solid KS has the conventional features encountered in nodular-stage lesions and was the most common subtype in the present series. Nodular-stage KS has a pyogenic granuloma-like clinical appearance. A pyogenic granuloma-like microscopic variant of KS has been described in some cutaneous lesions.²⁴ The oral lesions described as solid KS were, however, much larger and did not show the lobular arrangement of capillary-sized vessels attributed to this subtype. In spite of the recognizable diagnostic features, the histologic differential diagnoses would include lesions ranging from reactive and benign to distinctly malignant. Lesions bear some resemblance to nodular fasciitis, inflammatory myofibroblastic tumor, and predominantly spindled and cellular fibrous histiocytoma. Solid KS also shares features with Kaposiform hemangioendothelioma and well-differentiated angiosarcoma, whereas those with compact, organized fascicles echo fibrosarcomatous growth.

LLKS is a widely accepted cutaneous variant with a striking predilection for the lower extremities arising in background lymphedema. It is a rare cutaneous form, accounting for fewer than 5% of the variants thus far documented.²⁴ LLKS is

responsible for a bullouslike clinical appearance in skin lesions, a feature not evident in the oral cavity. The clinical significance of LLKS is unknown; however, lymphedematous cutaneous variants forecast a poor clinical outcome.^{22,24} The prominent jagged sinusoidal lymphatic vessels discerned in LLKS may prompt consideration of various vascular and lymphatic lesions, including lymphangioma, kaposiform hemangioendothelioma, lymphangiosarcoma, and well-differentiated angiosarcoma.

TKS in the current series appears to be more prevalent than its infrequently documented cutaneous analogue. TKS and EKS present in much the same way clinically as the other KS variants, but have microscopic features characterized by marked hemorrhage. These 2 variants can be distinguished from each other on the basis of their cellularity. TKS comprises large, ectatically dilated spaces that are engorged with red blood cells. There is abundant extravasational stromal hemorrhage; nevertheless, the cellular spindle cell component is still identifiable. EKS on the other hand is associated with such extensive hemorrhage that the cellular components are almost completely obscured. Focal areas showing conventional KS features are invariably present but may require serial sections for identification. In the absence of adequate clinical information or a high index of suspicion, the histologic features of both TKS and EKS may be misinterpreted as submucosal hemorrhage, traumatic hemorrhage, the pooling of blood within a vascular malformation or evidence suggestive of an underlying bleeding disorder. The diagnosis of KS may easily be overlooked in these 2 variants if biopsy specimens are superficial or nonrepresentative.

DKS is a novel histomorphological KS variant that we describe here for the first time. The histologic features unique to this variant included the depth of tumor infiltration and the abundant stromal connective tissue that compressed the cellular elements in areas. This unusual morphology in the absence of recognizable KS features necessitates confirmatory immunohistochemical staining. DKS of the oral cavity shares overlapping features to some degree with keloidal KS of the skin; the latter, however, has a tendency to clinical keloid formation, implying exophytic

growth and possible traumatic origin.^{7,24} DKS may need to be distinguished from the regressive changes seen in KS associated with HAART as well as the possibility of recrudescence of KS as a result of immune reconstitution inflammatory syndrome (IRIS).^{5,25} In this regard, DKS did not show any evidence of lesional circumscription or localization by peripheral fibrosis, nor was there a history of HAART initiation in any case. DKS may be missed completely in small, superficial fibrous biopsies. The desmoplastic stromal reaction is well documented in invasive carcinomas and refers to the interaction between tumor cells and the surrounding stroma, which constitutes the tumor microenvironment.²⁶ The fibroblasts within the tumor stroma transdifferentiate into myofibroblasts under the influence of cytokines and growth factors produced by the invasive tumor cells. The myofibroblasts may facilitate tumor progression through paracrine signaling.²⁷ Myofibroblastic transformation in tumor stroma is associated with more infiltrative, proliferative neoplasms. All cases of DKS in this series expressed variable degrees of SMA positivity within the desmoplastic stromal component, a possible indication of increased clinical aggression or progression. This correlates with the extensive lateral and vertical infiltration noted histopathologically.

Two of the samples examined were deemed to be anaplastic KS variants. AKS is a rare expression of KS, separated from other variants by its increased number of mitoses and pronounced cytologic atypia. Although documented in all clinical forms of disease, anaplastic KS is particularly prevalent in epidemic disease. AKS is characterized by extensive local destruction, deep infiltration, and a propensity for metastasis. The more vascular regions of AKS require microscopic distinction from angiosarcoma and hobnail hemangioendothelioma, whereas the predominantly cellular areas resemble malignant melanoma and spindle cell malignancies.

The diagnosis of KS, irrespective of the variant, is facilitated by recognition of focal areas showing conventional features. It is thus essential to sample lesions adequately for histopathological assessment, with serial sections being of assistance where typical features are absent. Immunoreactivity for the vascular

markers CD31 and CD34 and the lymphatic endothelial marker D2-40, in conjunction with nuclear HHV-8 immunopositivity, are useful for diagnostic confirmation. The profound immune suppression that accompanies epidemic KS predisposes patients to development of disseminated systemic opportunistic infections and other neoplasms.²⁸ The occurrence of coexistent infections, dermatoses, and neoplasms has been described in cutaneous KS and to a lesser extent in OKS.²⁸⁻³³ Twenty-five cases in this series showed coexistent pathology, most commonly in the form of superficially invasive candidiasis. This is not unexpected, considering oral candidiasis represents the most frequent intraoral manifestation of HIV, regardless of stage. Triple pathology was evident in a case of LLKS that contained endothelial cells with intranuclear cytomegalovirus (CMV) inclusions as well as invasive fungal hyphae (Figure 4). One case of DKS contained a single non-necrotizing granuloma with a sarcoid-like appearance. Limited preliminary special investigations were negative for fungal or Mycobacterial agents, not entirely ruling out an infectious origin. The coexistence of KS and granulomatous inflammation occurring at the same site has been documented in the skin.³³ The diagnosis of a sarcoid-like reaction should be made with caution following careful exclusion of a concurrent infectious process. On the contrary, non-infective granulomas may potentially represent foreign body or unusual drug reactions.³²

The microscopic diversity of OKS and the high prevalence of coexistent pathology provide the histopathologist with distinct diagnostic challenges often perpetuated by inadequate clinical details. Heightened awareness of the histopathological spectrum of OKS should expedite an accurate diagnosis. Moreover, the diagnosis of OKS should be diligently followed by serologic investigation in instances in which a patient's retroviral status is unknown. Multiple concurrent pathologic processes within the same biopsy specimen are prognostically significant, signaling marked immune deterioration or the possibility of IRIS in patients following recent HAART induction.

Statement of Clinical RelevanceStatement of Clinical Relevance

Oral Kaposi sarcoma may be the first sign of underlying immune dysfunction. The microscopic growth patterns encountered in oral Kaposi sarcoma are highlighted and characterized here in an attempt to facilitate the diagnosis with distinction from possible histopathological mimickers.

REFERENCES

1. Knuutila S, Lamovec J. Kaposi sarcoma. In: Fletcher CDM UK, Mertens F, editor. Pathology and genetics of tumours of soft tissue and bone. Lyon, France: IARC Press; 2002.
2. Newland JR, Lynch DP, Ordonez NG. Intraoral Kaposi's sarcoma: a correlated light microscopic, ultrastructural, and immunohistochemical study. *Oral Surg Oral Med Oral Pathol* 1988;66:48-58.
3. Schwartz RA. Kaposi's sarcoma: an update. *J Surg Oncol* 2004;87:146-51.
4. Kaposi M. Idiopathisches multiples Pigmentsarkom der haut. *Arch Dermatol Syph (Prague)* 1872;4:265-73.
5. Papagatsia Z, Jones J, Morgan P, Tappuni AR. Oral Kaposi sarcoma: a case of immune reconstitution inflammatory syndrome. *Oral Surg Oral Med Oral Pathol Oral Radiol Endod* 2009;108:70-5.
6. Fatahzadeh M. Kaposi's sarcoma: review and medical management update. *Oral Surg Oral Med Oral Pathol* 2012;113:2-16.
7. Schwartz RA, Micali G, Nasca MR, Scuderi L. Kaposi sarcoma: a continuing conundrum. *J Am Acad Dermatol* 2008;59:179- 206.
8. Martellotta F, Berretta M, Vaccher E, Schioppa O, Zanet E, Tirelli U. AIDS-related Kaposi's sarcoma: state of the art and therapeutic strategies. *Curr HIV Res* 2009;7:634-8.
9. Chang Y, Cesarman E, Pessin MS, Lee F, Culpepper J, Knowles DM, Moore PS. Identification of herpesvirus-like DNA sequences in AIDS-associated Kaposi's sarcoma. *Science* 1994; 266:1865-9.

10. Anonymous. Global report: UNAIDS report on the global AIDS epidemic 2010. Available at: http://www.unaids.org/documents/20101123_globalreport_em.pdf. Accessed June 15, 2012.
11. Lager I, Altini M, Coleman H, Ali H. Oral Kaposi's sarcoma: a clinicopathologic study from South Africa. *Oral Surg Oral Med Oral Pathol Oral Radiol Endod* 2003;96:701-10.
12. Rohrmus B, Thoma-Greber EM, Bogner JR, Röcken M. Outlook in oral and cutaneous Kaposi's sarcoma. *Lancet* 2000;356:2160.
13. Epstein JB, Scully C. HIV infection: clinical features and treatment of thirty-three homosexual men with Kaposi's sarcoma. *Oral Surg Oral Med Oral Pathol* 1991;71:38-41.
14. Epstein JB, Cabay RJ, Glick M. Oral malignancies in HIV disease: changes in disease presentation, increasing understanding of molecular pathogenesis, and current management. *Oral Surg Oral Med Oral Pathol Oral Radiol Endod* 2005;100:571-8.
15. Bottler T, Kuttnerberger J, Hardt N, Oehen HP, Baltensperger M. Non-HIV-associated Kaposi's sarcoma of the tongue. Case report and review of the literature. *Int J Oral Maxillofac Surg* 2007;36:1218-20.
16. Vanni T, Sprinz E, Machado MW, Santana Rde C, Fonseca BA, Schwartzmann G. Systemic treatment of AIDS-related Kaposi sarcoma: current status and perspectives. *Cancer Treat Rev* 2006;32:445-55.
17. Bower M, Nelson M, Young AM, Thirlwell C, Newsom-Davis T, Mandalia S, et al. Immune reconstitution inflammatory syndrome associated with Kaposi's sarcoma. *J Clin Oncol* 2005;23:5224-8.
18. Regezi JA, MacPhail LA, Daniels TE, Greenspan JS, Greenspan D, Dodd CL, et al. Oral Kaposi's sarcoma: a 10-year retrospective histopathologic study. *J Oral Pathol Med* 1993;22:292-7.
19. Reichart PA, Schiødt M. Non-pigmented oral Kaposi's sarcoma (AIDS). Report of two cases. *Int J Oral Maxillofac Surg* 1989;18:197-9.

20. Pantanowitz L, Moses AV, Dezube BJ. The inflammatory component of Kaposi sarcoma. *Exp Mol Pathol* 2009;87:163-5.
21. Lumerman H, Freedman PD, Kerpel SM, Phelan JA. Oral Kaposi's sarcoma: a clinicopathologic study of 23 homosexual and bisexual men from the New York metropolitan area. *Oral Surg Oral Med Oral Pathol* 1988;65:711-6.
22. Pantanowitz L, Grayson W, Simonart T, Dezube BJ. Pathology of Kaposi's sarcoma. *J HIV Ther* 2009;14:41-7.
23. Eng W, Cockerell CJ. Histological features of Kaposi sarcoma in a patient receiving highly active antiviral therapy. *Am J Dermatopathol* 2004;26:127-32.
24. Grayson W, Pantanowitz L. Histological variants of cutaneous Kaposi sarcoma. *Diagn Pathol* 2008;3:31.
25. Pantanowitz L, Dezube BJ, Pinkus GS, Tahan SR. Histological characterization of regression in acquired immunodeficiency syndrome-related Kaposi's sarcoma. *J Cutan Pathol* 2004;31: 26-34.
26. Chaudhary M, Gadbail AR, Vidhale G, Mankar Gadbail MP, Gondivkar SM, Gawande M, Patil S. Comparison of myofibroblasts expression in oral squamous cell carcinoma, verrucouscarcinoma, high risk epithelial dysplasia, low risk epithelial dysplasia and normal oral mucosa. *Head Neck Pathol* 2012;6:305-13.
27. Räsänen K, Vaheiri A. Activation of fibroblasts in cancer stroma. *Exp Cell Res* 2010;316:2713-22.
28. Pietras TA, Baum CL, Swick BL. Coexistent Kaposi sarcoma, cryptococcosis, and *Mycobacterium avium* intracellulare in a solitary cutaneous nodule in a patient with AIDS: report of a case and literature review. *J Am Acad Dermatol* 2010;62:676-80.
29. Grayson W. Recognition of dual or multiple pathology in skin biopsies from patients with HIV/AIDS. *Patholog RES Int* 2011;2011:398546.
30. Ramdial PK, Sing Y, Subrayan S, Calonje E. Cutaneous colesional acquired immunodeficiency syndrome associated Kaposi sarcoma and cryptococcosis. *Am J Dermatopathol* 2010;32: 780-6.

31. Pontes HA, Guimarães DM, Pontes FS, Paiva HB, Pinto LC, de Freitas Silva BS, Dos Santos Pinto D. Kaposi sarcoma and paracoccidioidomycosis in the same fragment of oral mucosa biopsy: a rare association in a human immunodeficiency viruspositive patient. A case report. *Diagn Microbiol Infect Dis* 2011;69:196-9.
32. Kandemir NO, Yurdakan G, Bektas S, Tekin NS. Classic Kaposi sarcoma with sarcoid-like granulomas: a case report and literature review. *Exp Mol Pathol* 2009;87:89-93.
33. Glassman SJ, Hale MJ. Cutaneous cryptococcosis and Kaposi's sarcoma occurring in the same lesions in a patient with the acquired immunodeficiency syndrome. *Clin Exp Dermatol* 1995;20:480-6.

FIGURES AND LEGENDS

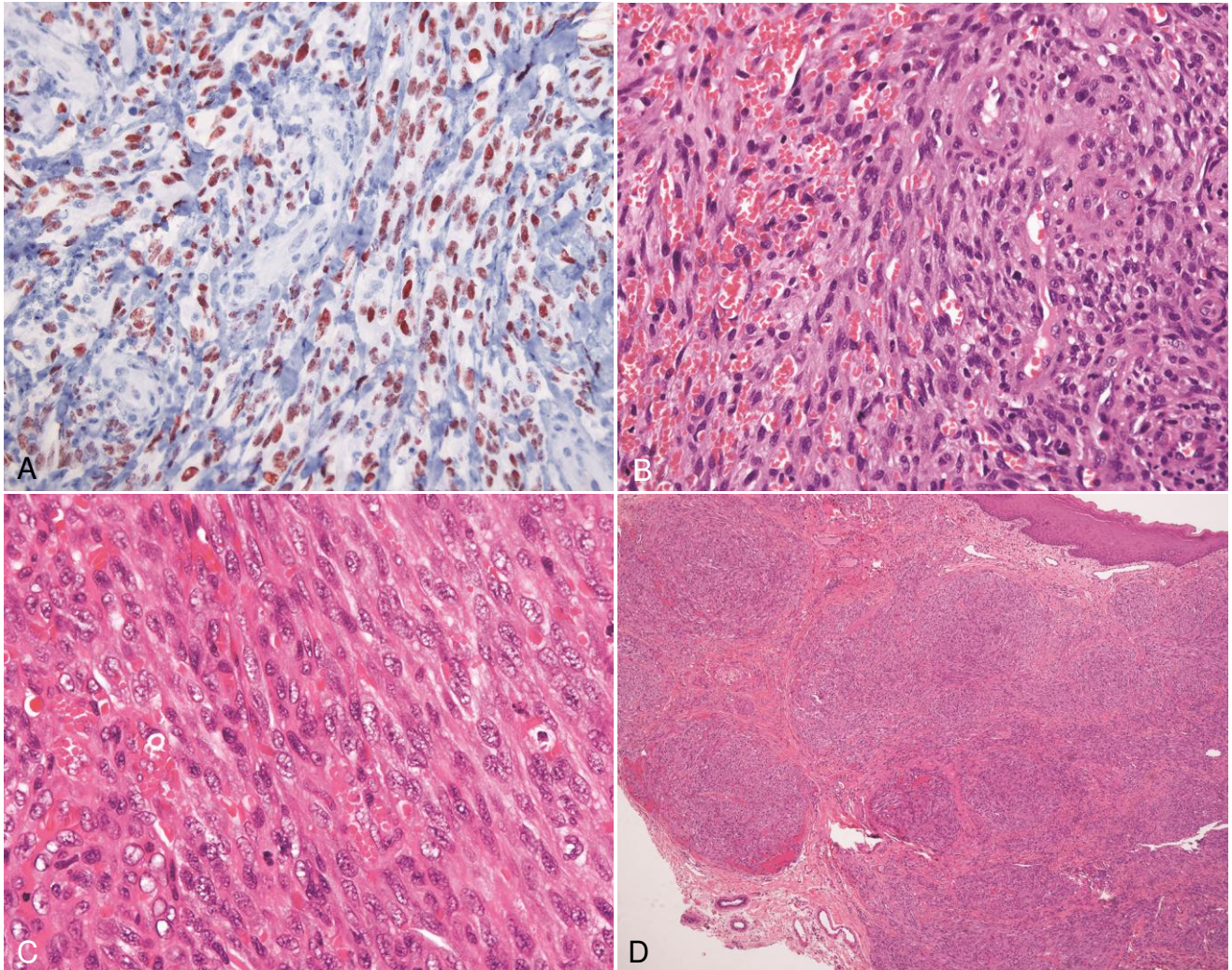


Figure 1. **A**, Strong diffuse nuclear immunoreactivity in a case of solid KS (immunohistochemical staining with HHV, original magnification $\times 200$). **B**, Solid KS with fascicular arrangement of spindle cells and extravasational hemorrhage (hematoxylineosin stain, original magnification $\times 200$). **C**, High-power magnification of solid KS showing fascicles of spindle cells, slitlike vascular channels, and scattered amorphous, eosinophilic globules (hematoxylin-eosin stain, original magnification $\times 400$). **D**, Solid KS comprising multiple lobules of spindle cells separated by fibrous bands (hematoxylin-eosin stain, original magnification $\times 40$).

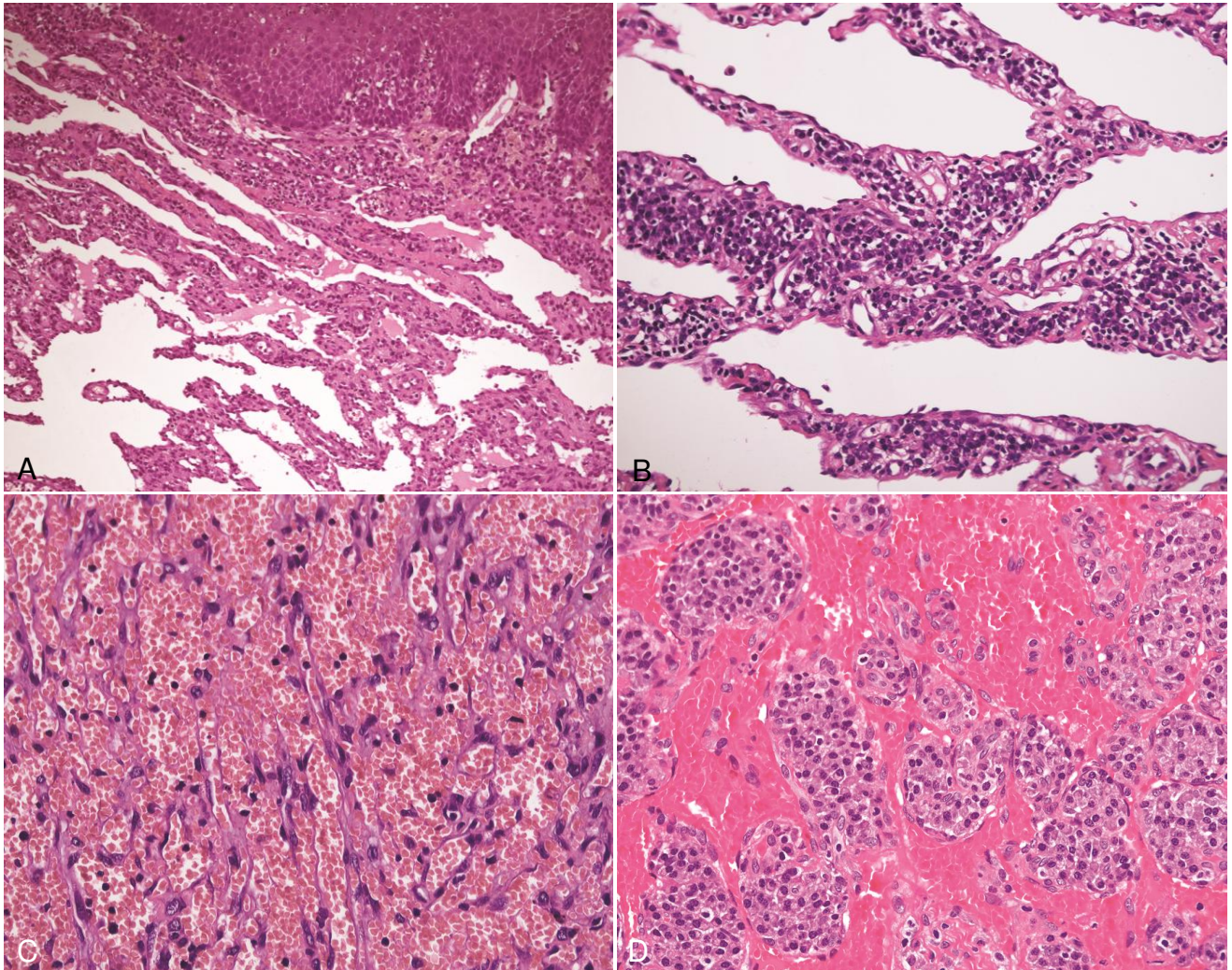


Figure 2. **A**, The characteristic irregular, angulated lymphatic channels seen in lymphangioma-like KS (hematoxylin-eosin stain, original magnification $\times 100$). **B**, Aggregates of plasma cells in a case of lymphangioma-like KS (hematoxylin-eosin stain, original magnification $\times 200$). **C**, Engorged vascular spaces of telangiectatic KS (hematoxylin-eosin stain, original magnification $\times 200$). **D**, Conspicuous nodular aggregates of plasma cells in telangiectatic KS (hematoxylin-eosin stain, original magnification $\times 200$).

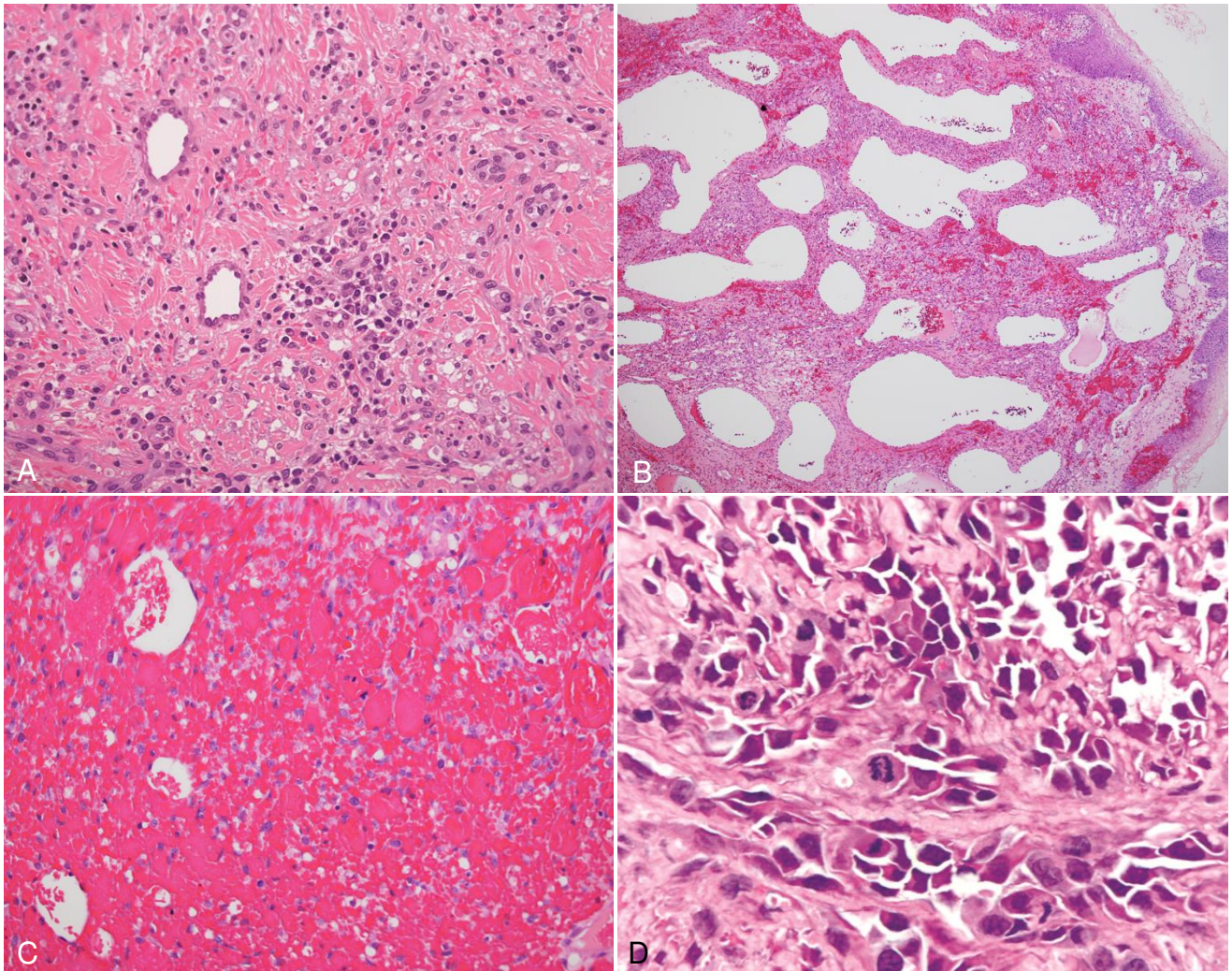


Figure 3. **A**, Desmoplastic KS typified by abundant collagenous connective tissue which separates the cellular constituents (hematoxylin-eosin stain, original magnification $\times 200$). **B**, Rounded, nonanastomosing vasculature identified in lymphangiectatic KS (hematoxylin-eosin stain, original magnification $\times 400$). **C**, Ecchymotic KS is dominated by extravasational hemorrhage, which at times obscures the cellular KS components (hematoxylin-eosin stain, original magnification $\times 200$). **D**, Anaplastic KS with vascular spaces lined by pleomorphic endothelial cells exhibiting features of hobnailing and nuclear hyperchromasia. Increased numbers of mitotic figures are readily recognized (hematoxylin-eosin stain, original magnification $\times 400$).

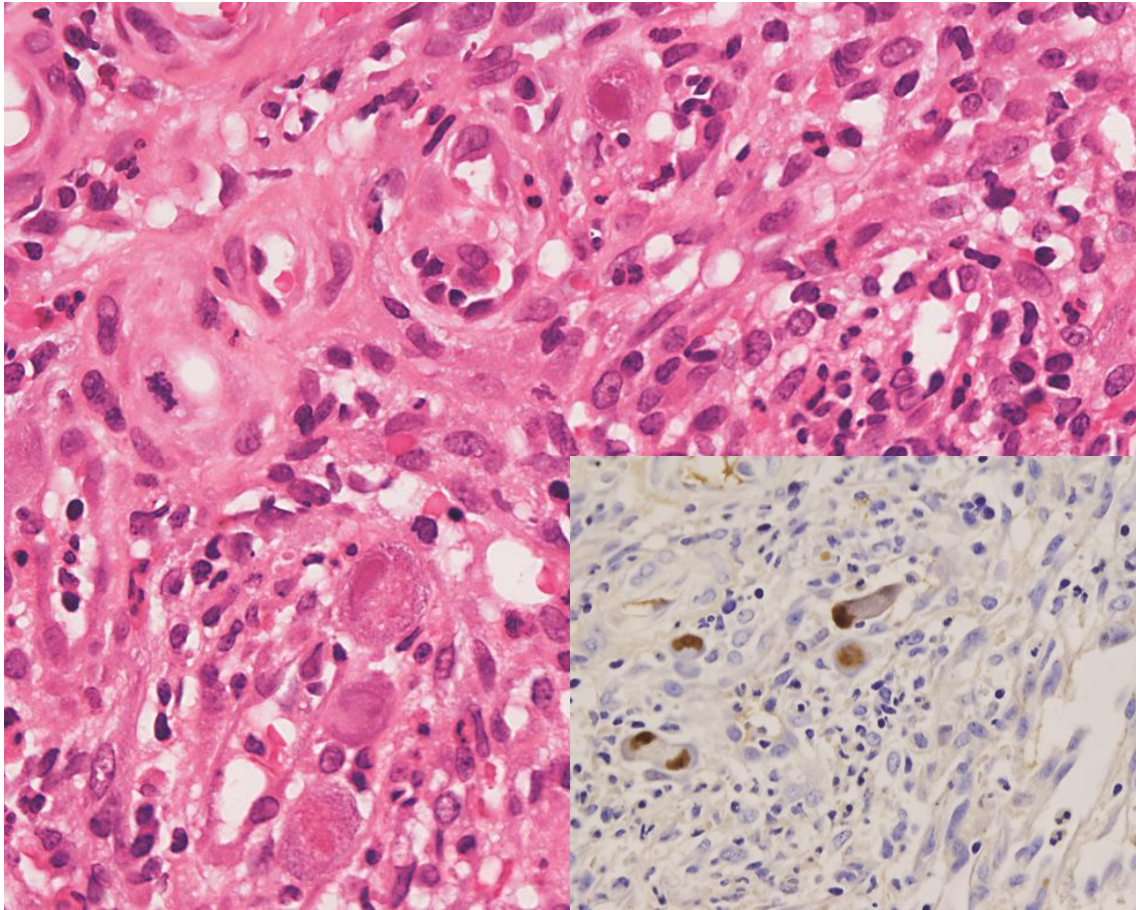


Figure 4. Coexistent pathology is highlighted in this case of KS and CMV. Scattered prominent endothelial cells contain large intranuclear viral inclusions (hematoxylin-eosin stain, original magnification $\times 400$). The insert demonstrates positive CMV immunoreactivity (immunohistochemical staining with CMV, original magnification $\times 400$).

TABLES

Table 1. Confirmatory immunohistochemical staining

<i>Antibody</i>	<i>Clone</i>	<i>Dilution</i>
CD31	JC70A†	1:200
CD34	QBEnd 10†	1:50
HHV8-LNA	1 3B10*	1:100
D2-40	D2-40†	1:100

†Dako, Glostrup, Denmark

*Novocastra Laboratories, Newcastle upon Tyne, UK

Table 2. Microscopic variants diagnosed in oral Kaposi sarcoma lesions

<i>Variant</i>	<i>Cases</i>	<i>Age (mean)</i>	<i>Gender</i>
Solid KS	59	8-58 (33)	30F, 25 M, 4 NS
Lymphangioma-like KS	23	21-70 (36)	14F, 8M, 1 NS
Telangiectatic KS	22	18-58 (34)	14F, 7M, 1 NS
Desmoplastic KS	14	22-57 (38)	4F, 10M
Lymphangiectatic KS	12	10-45 (30)	6F, 5M, 1 NS
Ecchymotic KS	3	16-27 (22)	1F, 2M
Anaplastic KS	2	35-50 (43)	1F, 1M

F, female; *M*, male; *NS*, not stated.

CAPÍTULO 2

Artigo enviado para possível publicação no periódico *Histopathology*

Thyroid gland involvement in advanced AIDS. an autopsy-based study.

Marianne de Vasconcelos Carvalho, DDS, MSc^a; René Gerhard, MD, PhD^b;
Leandro Liporoni, MD²; Ricardo Della Coletta, DDS, PhD^a; Pablo Agustin Vargas,
DDS, PhD, FRCPath^a

^a Department of Oral Diagnosis, Oral Pathology, Piracicaba Dental School, University of Campinas (FOP-UNICAMP), Piracicaba, São Paulo State, Brazil.

^b Department of Pathology, Clinics Hospital University of São Paulo School of Medicine (HC-FMUSP), São Paulo, São Paulo State, Brazil.

Running title: Thyroid involvement in AIDS patients.

*Corresponding author:

Prof. Pablo Agustin Vargas,
Oral Diagnosis Department,
Piracicaba Dental School, University of Campinas,
Avenida Limeira 901, Piracicaba-São Paulo State,
Caixa Postal 52, CEP: 13414-903, Brazil.

E-mail: pavargas@fop.unicamp.br

Phone: + 55 19 2106-5319; Fax: + 55 19 2106-5218

ABSTRACT

Background: Infection with human immunodeficiency virus (HIV) and the resulting acquired immunodeficiency syndrome (AIDS) can affect any endocrine organ system, including the thyroid gland. **Aims:** One-hundred thyroids obtained at autopsy from individuals with AIDS were analyzed systematically in order to describe the histological alterations and determine the frequency of the diseases.

Methods and results: Thyroid glands were obtained from 70 (70%) men and 30 (30%) women with a mean age of 36.5 years. Thirty-six individuals (36%) exhibited 40 alterations in the gland, including six concomitant lesions. The most common lesions diagnosed in this study were colloid goiter (n=16, 16%), mycobacteriosis (n=14, 14%), cytomegalovirus (n=2, 2%), cryptococcosis (n=2, 2%), non-Hodgkin's lymphoma (n=1, 1%), papillary thyroid carcinoma (n=4, 4%), medullary thyroid carcinoma (n=1), lymphocytic focal thyroiditis (n=1, 1%), and fat cell infiltration (n=1, 1%). Concomitant lesions were mycobacteriosis and colloid goiter (n=5, 5%) and mycobacteriosis and cytomegalovirus (n=1, 1%). **Conclusion:** Clinicians should consider the high index of suspicion and caution in the diagnosis of thyroid lesions in patients with advanced AIDS.

Keywords: AIDS, autopsy, mycobacteriosis, neoplastic lesions, PCR, thyroid.

INTRODUCTION

A number of endocrine abnormalities, such as hormone insufficiency, are due to infiltration of the endocrine glands by tumors or to infection with opportunistic organisms.^{1,2} Among individuals infected with human immunodeficiency virus (HIV), thyroid disease is observed in 1 to 2% and 35% may exhibit subtle abnormalities in thyroid function.³ Manifestations can be seen at any time during the course of the disease, from the asymptomatic HIV-positive stage to full-blown acquired immunodeficiency syndrome (AIDS). However, thyroid disease frequently occurs in the absence of clinical symptoms.^{4,5}

Few studies are available about the thyroid gland, most of them representing case reports showing the presence of opportunistic agents such as

Pneumocystis jirovecii, CMV, *Mycobacterium tuberculosis* and malignancies diagnosed by fine-needle aspirative biopsy or functional changes in the patient's gland in life.^{1,4}

Therefore, anatomopathological studies, particularly autopsy studies, are useful to demonstrate the frequency and most common types of thyroid disease. In this respect, opportunistic infections have been shown to be the main alterations in thyroid tissue.⁴⁻⁶

The objective of the present study was to describe the histological alterations found in the thyroid gland of 100 individuals with AIDS autopsied between 1996 and 1999 at the Department of Pathology, University of São Paulo Medical School, Brazil.

MATERIALS AND METHODS

The use of autopsy samples in the present study was approved by the Department of Pathology, University of São Paulo Medical School, and the Ethics Committee of the Piracicaba Dental School, University of Campinas (Protocol 138/2012).

Patient population

A retrospective autopsy study was conducted in which pathological abnormalities of the thyroid were analyzed in individuals who died of complications of AIDS. One-hundred thyroid glands from individuals admitted to the University Hospital of the University of São Paulo Medical School between 1996 and 1999 were studied. None of the individuals had access to highly active antiretroviral therapy. Clinical records were reviewed to obtain age, gender, and CD4 and CD8 counts. The final autopsy reports were analyzed for main findings.

Tissue processing and histological analysis

After dissection, six sections were obtained from each thyroid gland. The material was fixed in 10% buffered formalin for 24 h and embedded in paraffin.

Histological sections (5 µm) were cut, processed for routine staining with hematoxylin and eosin (H/E), and examined by light microscopy. The histological findings were classified as follows: no abnormalities, opportunistic infections, neoplastic conditions, other findings, and concomitant lesions.

Histochemistry, nested polymerase chain reaction (PCR), and immunohistochemistry

In some cases, histochemistry, immunohistochemistry and nested PCR were performed to confirm the histological diagnosis. Specific histochemical stains such as Ziehl-Neelsen (ZN), Gomori-Grocott (GG), periodic acid-Schiff (PAS), mucicarmine (MUC), and Alcian blue (AB) were used when fungal or bacterial infections were suspected. For this purpose, 5-µm thick histological sections were processed for histochemical staining and examined by light microscopy.

For immunohistochemistry, 3-µm thick histological sections were treated with the following antibodies: CK19, galectin-3 and HBME-1 for the diagnosis of papillary carcinoma; calcitonin, chromogranin A and carcinoembryonic antigen for the diagnosis of medullary carcinoma; anti-CMV antibody for the diagnosis of cytomegalovirus, and CD20, CD79a, CD3, CD45RO, CD138, anti-EBV and Plasma cell for the diagnosis of non-Hodgkin's lymphoma (NHL) (Table 1).

Nested PCR was performed in all cases with a suspicion of mycobacteriosis (n= 14) by H/E or ZN staining.

DNA extraction for PCR

DNA was extracted using the QIAamp® DNA Formalin-Fixed and Paraffin-Embedded (FFPE) Tissue kit (Qiagen). Genomic DNA extracted from formalin-fixed and paraffin-embedded subcutaneous tissue of mice infected with *M. tuberculosis* was used as positive control and oral mucosal fibrous hyperplasia specimens were used as negative control. The quantity of extracted DNA was determined in a spectrophotometer (NanoDrop 2000c Spectrophotometer, Thermo Scientific, USA).

DNA amplification of the genus Mycobacterium by nested PCR

Nested PCR amplifying a small region of the gene encoding the 65-kDa antigen, which is highly conserved in a variety of *Mycobacterium* species, was used for identification of the genus *Mycobacterium*.⁷ The integrity of DNA samples was checked by amplification of FGFR2 exon 16. The primer sequences and their predicted product sizes are shown in Table 2. The total reaction volume in each round of PCR was 50 μ l and the mixture contained 5 μ l 10X PCR buffer, 3 μ l 50 mM MgCl₂, 1 μ l 10 mM dNTP mix, 1 μ l of each primer (10 μ M solution), and 0.5 μ l 5 U/ μ l Taq DNA polymerase (Invitrogen, Life Technologies, Brazil). The amount of DNA used for the first round of PCR was 300 ng. For the second round of PCR, 15 μ l of the first round was used. The PCR conditions were initial denaturation at 94°C for 4 min, followed by 35 cycles at 94°C for 1 min, 57°C for 2 min and 72°C for 2 min, and a final extension at 72°C for 7 min (first round). The second round consisted of initial denaturation at 94°C for 4 min, followed by 35 cycles at 94°C for 1 min, 55°C for 2 min and 72°C for 2 min, with a final extension at 72°C for 7 min. The FGFR2 PCR conditions were initial denaturation at 94°C for 5 min, followed by 40 cycles at 94°C for 1 min, 60°C for 30 s and 72°C for 1 min, with a final extension at 72°C for 10 min. Fifteen microliters of the samples and negative control and 3 μ l of the positive control of the second round of amplification were resolved on 8% non-denaturing polyacrylamide gel and fragments were detected by silver staining as described elsewhere.⁸

RESULTS

Patient population

The sample consisted of 100 cases of individuals who died of complications of AIDS and 11 cases that died of complications unrelated to AIDS (control group).

In the AIDS group (n=100), 70 (70%) individuals were male and 30 (30%) were female. Age ranged from 8 to 68 years, with a mean \pm standard deviation (SD) of 36.5 \pm 11 years. The last CD4 count obtained before death was retrieved

from 69 individuals, with a mean of 71.2 ± 108.4 cells/ μ l. Mycobacteriosis, septic shock, and pneumonia were the main causes of death.

In the control group (n=11), 7 (63.7%) individuals were male and 4 (36.3%) were female. Age ranged from 32 to 77 years, with mean of 58.4 ± 12.4 years. Cerebrovascular accident was the main cause of death.

Histological findings of the thyroid gland

Sixty-four (64%) of the 100 individuals with AIDS showed no histopathological alterations in the thyroid. Thirty-six (36%) individuals exhibited 40 lesions in the thyroid gland, including 6 concomitant lesions. Adhered parathyroid glands and solid cell nests were found in nine and three autopsies, respectively. Table 3 shows the individual age, gender, CD4 count, main autopsy findings, and histopathological alterations in the thyroid gland.

Four of the 11 control individuals had no microscopical alterations. Histopathological abnormalities were observed in 7 individuals and the most frequent lesion was colloid goiter in 4. Parathyroid glands adhered to the thyroid were seen in 1 case.

Opportunistic infections in AIDS individuals

The most common opportunistic infections were mycobacteriosis (n=14, 14%) followed by CMV (n=2, 2%), cryptococcosis (n=2, 2%), and concomitant mycobacteriosis and CMV (n=1, 1%).

With respect to mycobacteriosis, chronic non-caseating, partly granulomatous, inflammation was observed in 7 cases, one presenting multinucleated giant cells. Chronic granulomatous inflammation with areas of necrosis were seen in 5 cases (Figure 1A, B), 1 presenting multinucleated giant cells. The other 2 cases exhibited an infiltrate of foamy macrophages. Seven of the 14 cases were positive by ZN staining (Figure 1C) and 7 were negative. In the latter cases, the microorganisms were detected by nested PCR (Figure 2).

Two (2%) individuals presented cryptococcosis in the thyroid parenchyma. Numerous fungal cells of different shapes and sizes, which were stained by GG,

PAS, MUC, and AB, were observed in thyroid glands that showed a normal architecture and no inflammatory response (Figure 3A-F).

CMV inclusions were seen in follicular cells of the glandular parenchyma in 2 cases (Figure 4). There was also no inflammatory reaction surrounding the virus in these cases.

Neoplastic conditions in AIDS individuals

One (1%) individual had a diffuse large B-cell lymphoma (DLBCL) that diffusely affected the thyroid gland (Figure 5A,B). The neoplastic cells were positive for CD45, CD20 and CD79a and negative for anti-EBV, Plasma cell, CD138 and CD3 immunomarkers.

Four (4%) individuals had papillary thyroid carcinoma. Two were microcarcinomas, one was the classic variant (Figure 6A-C), and 1 was the follicular variant. In all cases, the neoplastic cells were immunoreactive for CK19, HBME-1, and galectin-3 (Figure 6D-F). One (1%) individual had medullary thyroid carcinoma, which was immunoreactive for calcitonin, chromogranin A, and CEA (Figure 7A-E).

Other findings in AIDS individuals

The most frequent finding was colloid goiter (n=16, 16%). Lymphocytic focal thyroiditis was observed in 1 case and fat cell infiltration in another.

Concomitant lesions in AIDS individuals

Concomitant mycobacteriosis and CMV infection in the thyroid gland were observed in 1 case and mycobacteriosis and colloid goiter in 5.

DISCUSSION

There are few studies in the literature reporting thyroid disorders in AIDS patients.⁴⁻⁶ This retrospective study demonstrated involvement of the thyroid gland in 36% of AIDS patients, in agreement with the literature.^{5,6}

Immunosuppressed patients, such as patients with AIDS, leukemia, autoimmune diseases and organ-transplant recipients on pharmacological immunosuppression, are particularly at risk of fungal thyroiditis. In contrast to most organs of the body, the thyroid gland is remarkably resistant to infection.⁹ In the present study, mycobacteriosis was the most frequent opportunistic infection (14%), followed by CMV (2%) and cryptococcosis (2%).

Mycobacterium tuberculosis is the causative agent of most cases of tuberculosis.^{5,7} Thyroid tuberculosis was first described in 1862 by Lebert in a patient with disseminated mycobacterial infection.¹⁰ The frequency of thyroid tuberculosis among HIV-infected patients infected with *M. tuberculosis* is 1% on *antemortem* examination.^{11,12} Although the condition has been recognized for more than a century, most cases have been identified on *postmortem* examination. The frequency of mycobacteriosis was 14% in the present investigation, in agreement with other autopsy studies reporting a frequency of 17.2% to 28%.^{4,5}

Mycobacterial organisms may spread to the thyroid gland from an adjacent focus or may seed the gland during hematogenous dissemination, in miliary tuberculosis.^{12,13} About 62.5% of the present individuals with mycobacterial thyroiditis had miliary tuberculosis. The predominant morphological pattern was a poorly organized granuloma, reflecting a low cell-mediated immune response in these patients.⁷ This was also confirmed by the small number of CD4 T lymphocytes.

Mycobacteria are usually identified in paraffin-embedded tissue by ZN staining. In the present study, the microorganism was detected by this method in half the cases. The other cases were diagnosed by nested PCR. According to Ohtomo et al.,¹⁴ ZN staining is a sensitive method, but better results are obtained by PCR. However, Rangel et al.⁷ found no difference between these two methods used to diagnose mycobacteriosis in the parotid gland of autopsied individuals with AIDS.

CMV is recognized as one of the main infectious agents in AIDS. Analysis of the pathological findings of CMV infection in AIDS patients indicates several target

organs, including the lung, eyes, gastrointestinal tract, and parotid gland.¹⁵⁻¹⁷ Somewhat less common are reports of CMV infection in endocrine organs and the potential of endocrine dysfunction due to CMV is still unknown.¹⁶ In most cases, the diagnosis is made on *postmortem* examination. Autopsy studies of AIDS individuals demonstrated CMV infection of the thyroid in 14% and 17% of cases.^{5,6} Frank et al.¹⁵ observed CMV infection of the thyroid in four of seven cases analyzed (71.5%). Infection with CMV was uncommon in the present study (observed in 2% of cases). This finding agrees with another autopsy study in which no case was identified.⁴ CMV inclusions in the thyroid can affect both endothelial and epithelial cells. In the present study, viral inclusions were observed in follicular cells.

Case reports and autopsy studies of fungal infections in the thyroid of patients with AIDS include infection with *Candida spp.*, *Histoplasma capsulatum*, *Cryptococcus neoformans*, and *Coccidioides immitis*.^{4,5,9,18} In the present study, the frequency of cryptococcosis in the thyroid was 2% among 10 individuals with disseminated cryptococcal infection. Other investigators reported a frequency of 5 to 8.5%. Cryptococcal thyroiditis is rare and occurs in the setting of widespread systemic infection in immunocompromised patients. At present, the most common predisposing factor to cryptococcosis worldwide is AIDS.⁹ Cryptococcosis is an infection caused by the yeast-like fungus *Cryptococcus neoformans*. Inside the host and on certain culture media, a large polysaccharide capsule surrounds each yeast cell.^{9,19} Histopathological identification of cryptococcosis is based on the micromorphological and staining features of cryptococcal cells using histochemical techniques such as GG, PAS, MUC, AB, and Fontana-Masson.^{17,20}

Infection with HIV is associated with an increased risk of developing cancer. Cancers such as Kaposi's sarcoma and NHL have long been recognized to be associated with HIV infection and have been classified as AIDS-defining diseases.²¹ The number of individuals with neoplastic conditions as main disease was small in the present study (2%). Six (6%) individuals had thyroid neoplasms, in accordance with the literature.^{5,6} Kaposi's sarcoma is the most frequent malignancy

of the thyroid seen in AIDS patients. However, no case was observed in the present study. Only 1 (1%) of the current cases was cancer related with HIV infection; from 1 individual with AIDS associated NHL disseminated the thyroid gland was diffusely involved, which showed features of a (DLBCL).

Concurrently, a record linkage study conducted in some countries of Sub-Saharan Africa found several cancer sites to be associated with a higher incidence in HIV-infected populations, such as the kidney, thyroid and uterus.²¹ In the present study, five individuals (5%) had thyroid carcinoma, in agreement with Basílio-de-Oliveira.⁴ Four cases (4%) were papillary thyroid carcinoma and 2 (2%) of these were microcarcinomas. However, this prevalence is similar to or lower than those reported in other autopsy studies investigating the thyroid of HIV-negative individuals, with prevalence rates ranging from 1 to 35.6%.²²

In the present study, the most common non-neoplastic and non-infectious lesion was colloid goiter (16%). Four cases of colloid goiter were associated with mycobacteriosis. A similar incidence (17.2%) has been reported in an autopsy study of AIDS individuals.⁴ Colloid goiter is characterized by hyperplasia of thyroid follicular cells and has a multifactorial etiology. One of the most accepted and well-documented hypothesis is the reduced production of thyroid hormone and consequent increase in the levels of thyroid-stimulating hormone (TSH). The causal factors of colloid goiter include foods that inhibit hormone synthesis, mutations in TSH receptors, iodine-poor diets, globulin stimulation of thyroid development, growth hormone, insulin-like growth factor, and genetic factors.²³

One interesting finding was the presence of fatty infiltration in 1 case (1%). Fat cells are generally present in endocrine organs such as the parathyroid gland, thymus, and pancreas.²⁴ The differential diagnoses of fat in the thyroid include benign entities such as adenolipoma and intrathyroid thymic or parathyroid lipoma and malignant tumors such as liposarcoma.²⁵ The fat cells may also be associated with thyroid lesions such as malignancies, amyloid goiter, hyperplastic nodules, chronic thyroiditis, goiter, and atrophy.^{4,24} Few cases of diffuse lipomatosis of the thyroid gland have been reported in the literature.²⁴ Lima et al.⁴ found fat cells in

13.7% of cases, which were associated with lesions in three. No other changes were observed in the remaining cases. According to the authors, the high frequency of fatty deposits in the thyroid gland may be due to follicular inactivity caused by the debilitating condition of the patient, with consequent atrophy. This is similar to the mechanism observed in cases of pancreatic and salivary gland lipomatosis. However, fat cells are occasionally also found in normal thyroids near the capsule, around vessels, or in connective tissue septa.²⁴ In the present study, fat cells were observed in focal areas of connective tissue septa in the thyroid gland in the absence of other alterations.

Lymphocytic focal thyroiditis was observed in 1 case (1%) and was characterized by aggregates of lymphocytes and plasma cells in the thyroid parenchyma, causing focal destruction of thyroid follicles. We agree with Bisi et al.²⁶ who stated that lymphocytic focal thyroiditis is not a true primary thyroiditis, but rather a residual nonspecific inflammation caused by acute infection, trauma, chemicals, and radiation.

Coexisting lesions in the thyroid gland of AIDS patients are rare. We observed 1 case (1%) of mycobacteriosis associated with CMV infection. Kiertiburanakul et al.¹² and Zhang et al.¹⁶ reported the coexistence of tuberculosis and cryptococcosis and of CMV infection and Kaposi's sarcoma, respectively. These manifestations in the thyroid gland are probably a consequence of profound immunosuppression.

In summary, this large autopsy series showed involvement of the thyroid gland in individuals with AIDS. Mycobacteriosis was the most frequent infection, followed by CMV and cryptococcosis. Thyroid gland involvement was generally due to disease dissemination and few lesions had been diagnosed previously. Clinicians should be aware of the early signs of thyroid disease, which might be mistaken for general symptoms of AIDS such as wasting syndrome and therefore remain untreated.

REFERENCES

1. Luckhaus J. Endocrine involvement in HIV infections. *Zentralbl Gynakol.* 1999;121;30-2.
2. Noureldeen A, Qusti SY, Khoja GM. Thyroid function in newly diagnosed HIV-infected patients. *Toxicol Ind Health.* 2012 [In Press].
3. Hoffmann CJ, Brown TT. Thyroid function abnormalities in HIV-infected patients. *Clin Infect Dis.* 2007;45;488-94.
4. Lima MK, Freitas LL, Montandon C, Filho DC, Silva-Vergara ML. The Thyroid in Acquired Immunodeficiency Syndrome. *Endocr Pathol.* 1998;9;217-223.
5. Basílio-De-Oliveira CA. Infectious and neoplastic disorders of the thyroid in AIDS patients: an autopsy study. *Braz J Infect Dis.* 2000;4;67-75.
6. Welch K, Finkbeiner W, Alpers CE et al. findings in the acquired immune deficiency syndrome. *JAMA.* 1984;252;1152-9 Autopsy.
7. Rangel AL, Coletta RD, Almeida OP et al. Parotid mycobacteriosis is frequently caused by *Mycobacterium tuberculosis* in advanced AIDS. *J Oral Pathol Med.* 2005;34;407-12
8. Sanguinetti CJ, Dias Neto E, Simpson AJ. Rapid silver staining and recovery of PCR products separated on polyacrylamide gels. *Biotechniques.* 1994;17;914–21.
9. Goldani LZ, Zavascki AP, Maia AL. Fungal thyroiditis: an overview. *Mycopathologia.* 2006;161;129-39.
10. Simkus A. Thyroid TB. *Medicina (Kaunas).* 2004;40;201–204.
11. Shafer RW, Kim DS, Weiss JP, Quale JM. Extrapulmonary tuberculosis in patients with human immunodeficiency virus infection. *Medicine.* 1991;70;384–97.
12. Kiertiburanakul S, Sungkanuparph S, Malathum K, Prachartam R. Concomitant tuberculous and cryptococcal thyroid abscess in a human immunodeficiency virus-infected patient. *Scand J Infect Dis.* 2003;35;68-70
13. Ozekinci S, Mizrak B, Saruhan G, Senturk S. Histopathologic diagnosis of thyroid tuberculosis. *Thyroid.* 2009;19;983-6.

14. Ohtomo K, Wang S, Masunaga A, Aikichi, Iwamoto, Sugawara I. Secondary infections of AIDS autopsy cases in Japan with special emphasis on *Mycobacterium avium* intracellular complex infection. *Tohoku J Exp Med.* 2000;192;99–109.
15. Frank TS, LiVolsi VA, Connor AM. Cytomegalovirus infection of the thyroid in immunocompromised adults. *Yale J Biol Med.* 1987;60;1-8.
16. Zhang X, el-Sahrigy D, Elhosseiny A, Melamed MR. Simultaneous cytomegalovirus infection and Kaposi's sarcoma of the thyroid diagnosed by fine needle aspiration in an AIDS patient. A case report and first cytologic description of the two entities occurring together. *Acta Cytol.* 2003;47;645-8.
17. Vargas PA, Mauad T, Böhm GM, Saldiva PH, Almeida OP. Parotid gland involvement in advanced AIDS. *Oral Dis.* 2003;9;55-61.
18. Jinno S, Chang S, Jacobs MR. Coccidioides thyroiditis in an HIV-infected patient. *J Clin Microbiol.* 2012;50;2535-7.
19. Perfect JR, Casadevall A. Cryptococcosis. *Infect Dis Clin North Am.* 2002;16;837–874.
20. Gazzoni AF, Oliveira Fde M, Salles EF et al. Unusual morphologies of *Cryptococcus* spp. in tissue specimens: report of 10 cases. *Rev Inst Med Trop Sao Paulo.* 2010;52;145-9.
21. Sasco AJ, Jaquet A, Boidin E et al. The challenge of AIDS-related malignancies in sub-Saharan Africa. *PLoS One.* 2010;5:e8621.
22. de Matos PS, Ferreira AP, Ward LS. Prevalence of papillary microcarcinoma of the thyroid in Brazilian autopsy and surgical series. *Endocr Pathol.* 2006;17;165-73.
23. Lima MA, Tiveron FS, Santos VM, Lima LM, Silva GP, Borges MF. C-cells in colloid goiter. *Rev Hosp Clin Fac Med Sao Paulo.* 2003;58;310-4.
24. Arslan A, Alıç B, Uzunlar AK, Büyükbayram H, Sarı I. Diffuse lipomatosis of thyroid gland. *Auris Nasus Larynx.* 1999;26;213-5
25. Gupta R, Arora R, Sharma A, Dinda AK. Diffuse lipomatosis of the thyroid gland: a pathologic curiosity. *Indian J Pathol Microbiol.* 2009;52;215-6.

26. Bisi H, Fernandes VS, de Camargo RY, Koch L, Abdo AH, de Brito T. The prevalence of unsuspected thyroid pathology in 300 sequential autopsies, with special reference to the incidental carcinoma. *Cancer*. 1989;64;1888-93.

FIGURES AND LEGENDS

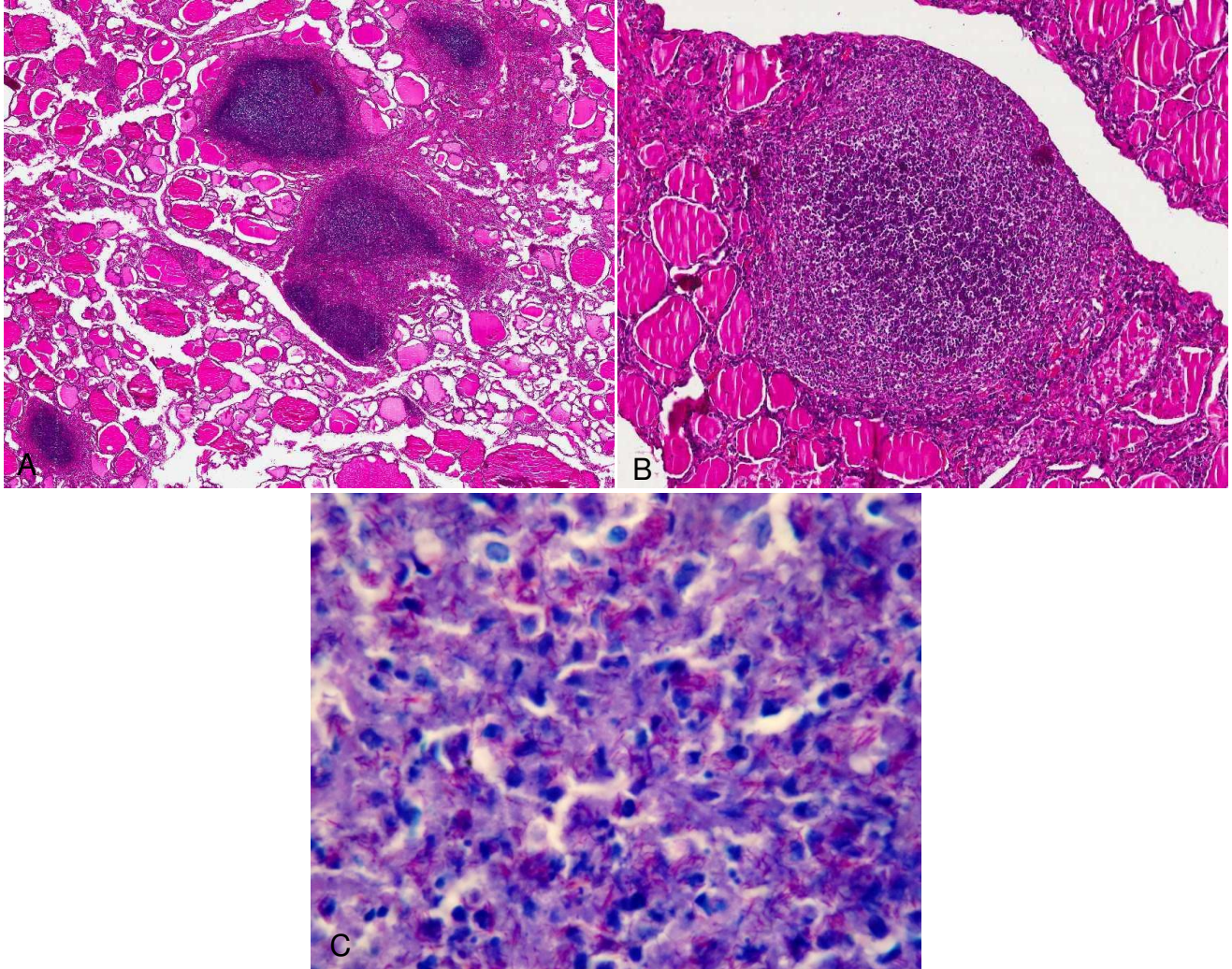


Figure 1. **A** and **B**, Mycobacteriosis showing chronic granulomatous inflammation with areas of necrosis without multinucleated giant cells (hematoxylin-eosin stain, original magnification $\times 15$ and $\times 70$). **C**, Mycobacteria in thyroid gland diagnosed by Ziehl-Neelsen (ZN) histochemical stain (histochemical staining with ZN, original magnification $\times 1000$).

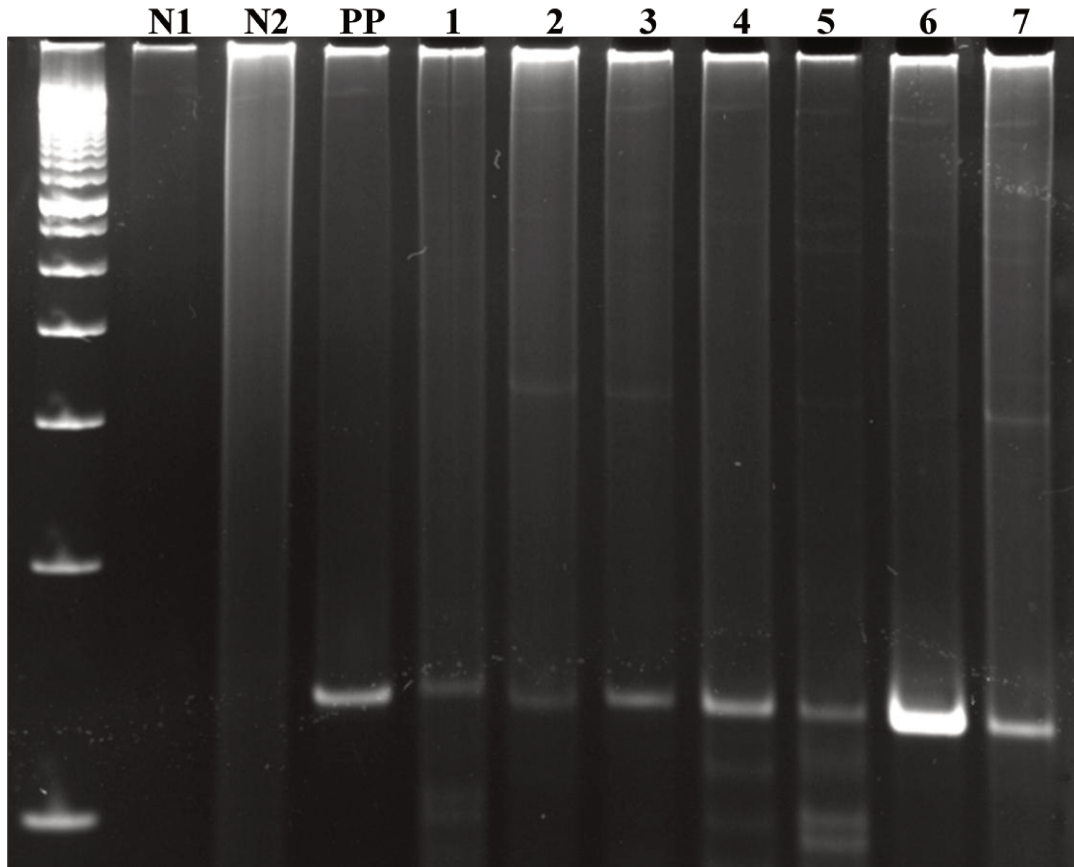


Figure 2. Gel electrophoresis showing: PCR-amplified products of Nested PCR for amplification of small region of gene responsible for conserved protein in the genus *Mycobacterium*. Lanes 1 to 7 were the negative cases for Ziehl–Neelsen stain; PP, positive control (formalin-fixed and paraffin-embedded subcutaneous tissue infected of the mice with *M. tuberculosis*); N2, negative control (formalin-fixed, paraffin-embedded fibrous hyperplasia from oral mucosa); N1 negative control (No template).

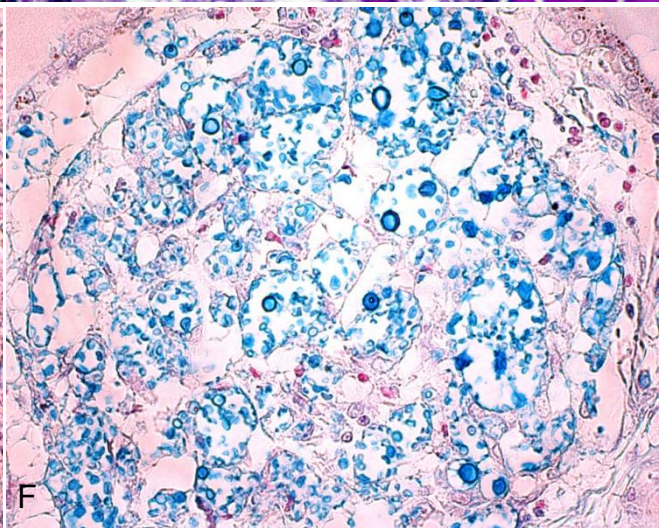
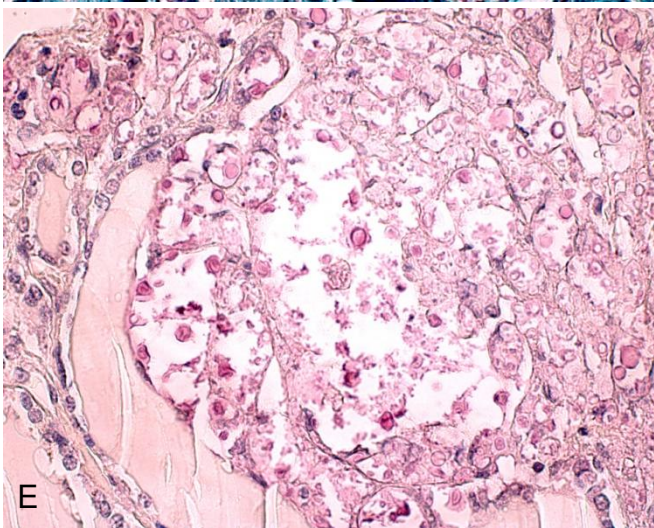
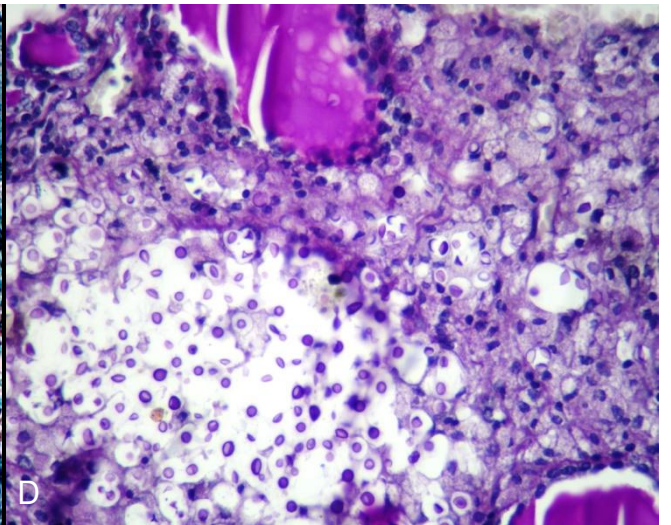
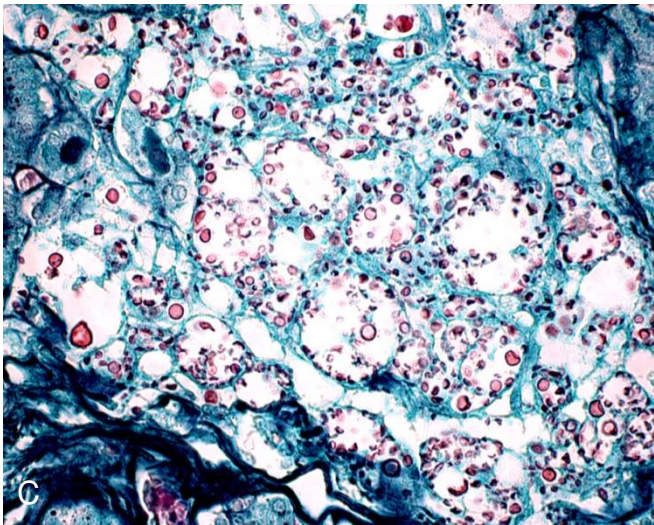
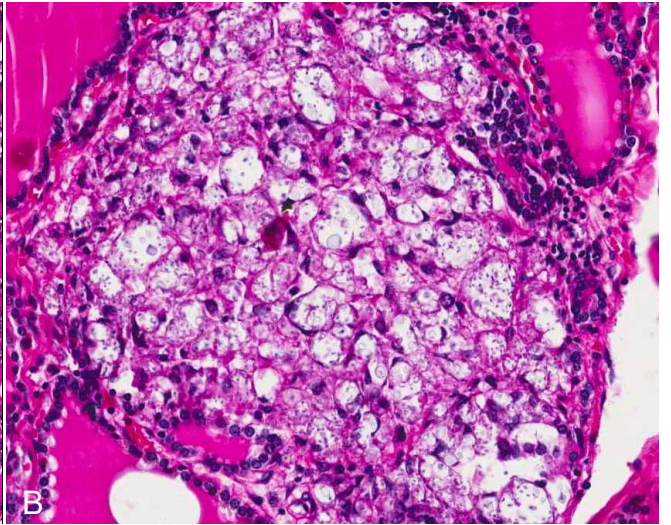
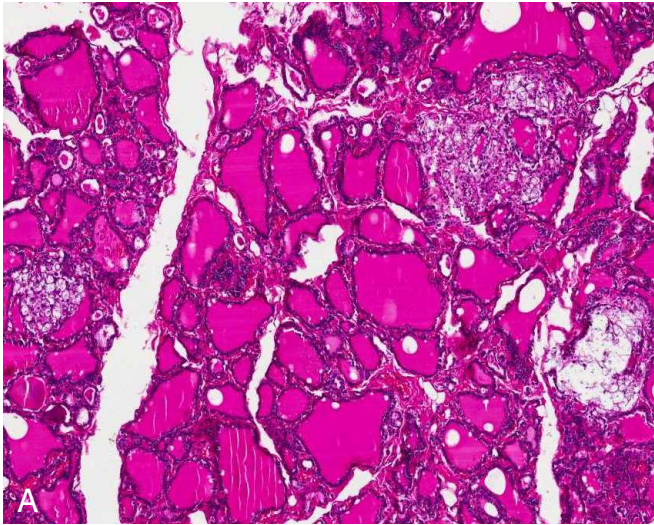


Figure 3. A and B, Numerous cryptococcal spores with thick capsule among thyroid follicles cells (hematoxylin-eosin stain, original magnification $\times 50$ and $\times 200$); **C, D, E and F**, note the *Cryptococcus* spores detected by Gomori–Grocott, Periodic acid-Schiff, Mucicarmine and Alcian Blue, respectively (histochemical staining, original magnification $\times 400$).

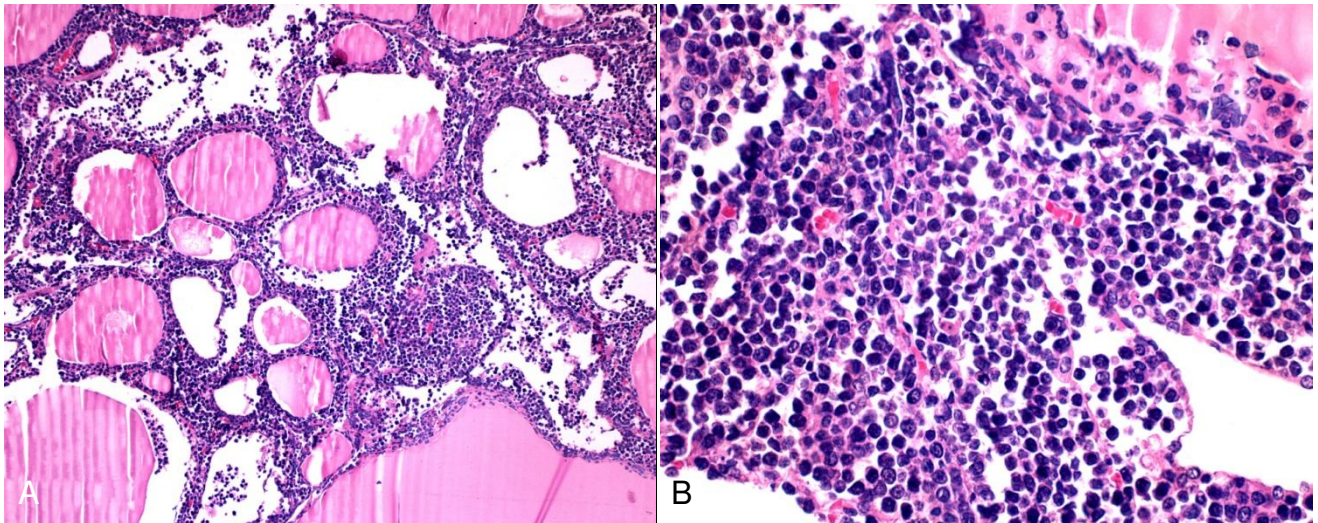
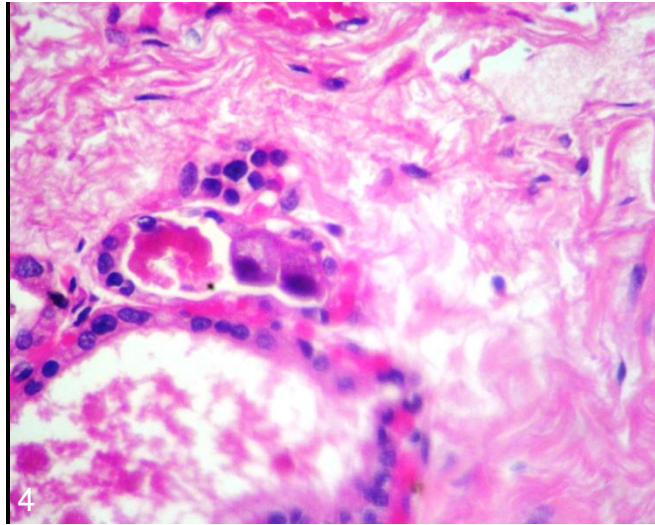


Figure 4. Follicle cells of thyroid gland showing cytomegaly characterized by cell enlargement of both cell & nucleus, without inflammatory reaction (hematoxylin-eosin stain, original magnification $\times 1000$).

Figure 5. A and B, Neoplastic lymphoid cells of non-Hodgkin lymphoma infiltrating the parenchyma of the thyroid gland (hematoxylin-eosin stain, original magnification $\times 100$ and $\times 400$).

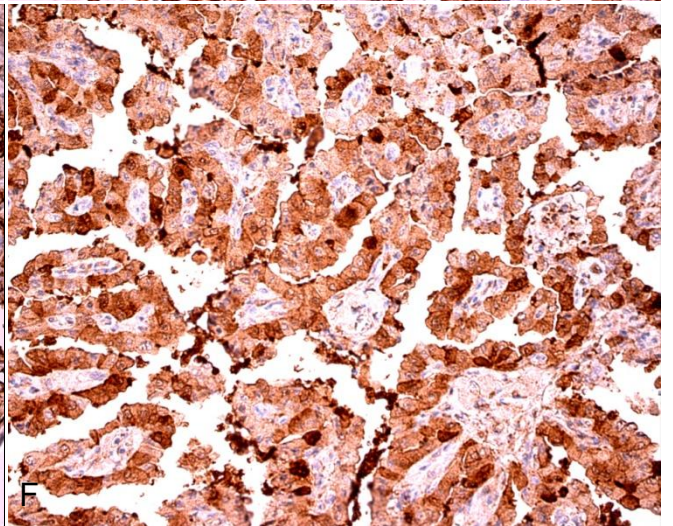
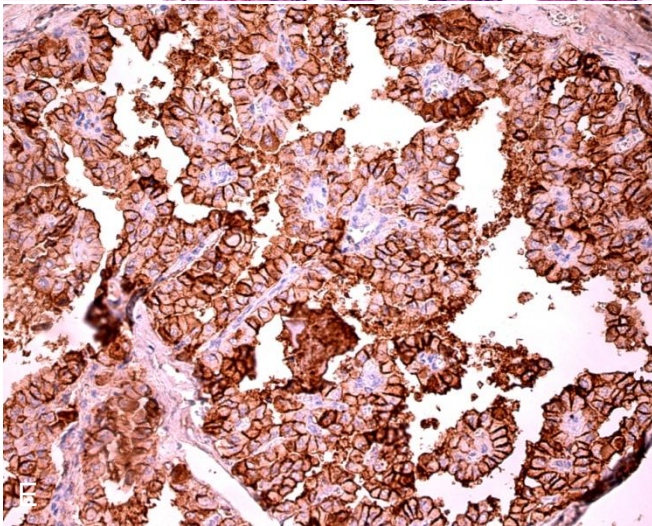
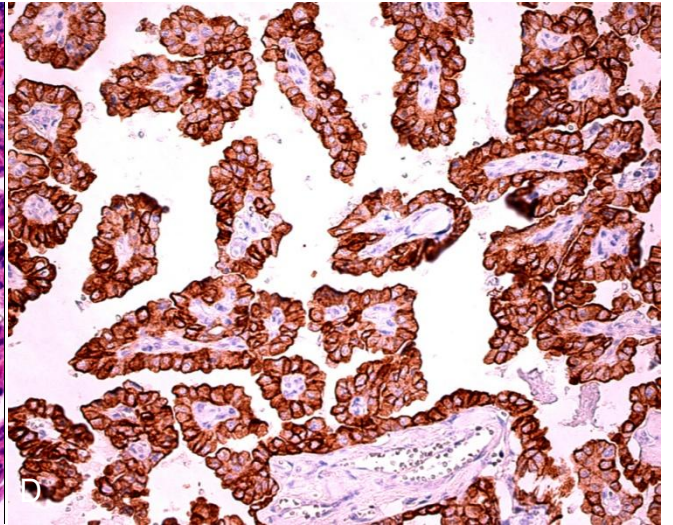
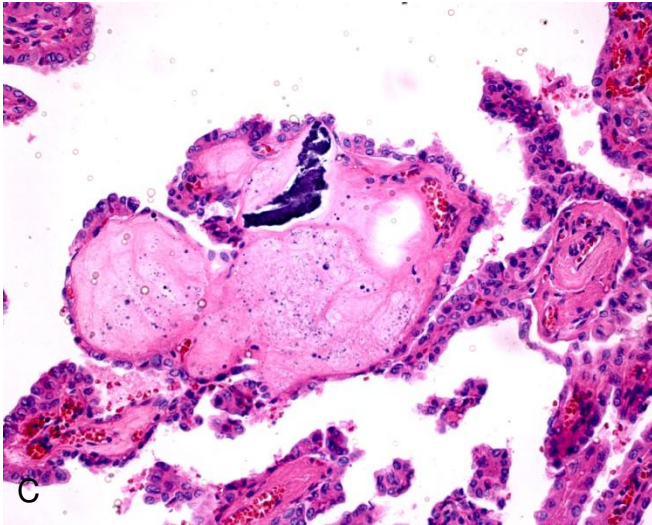
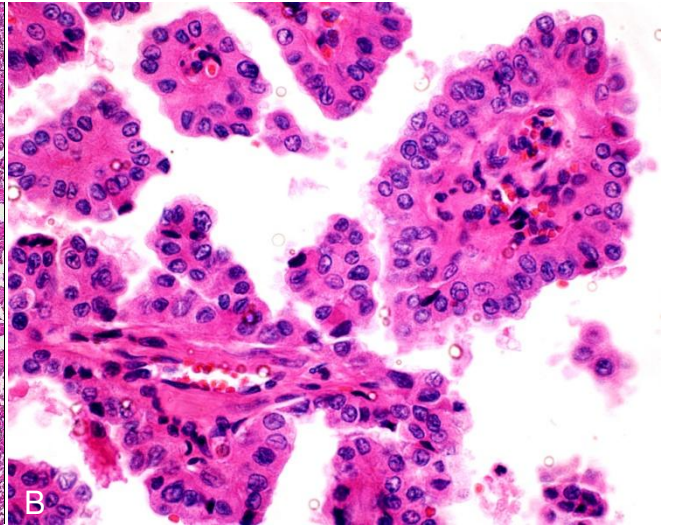
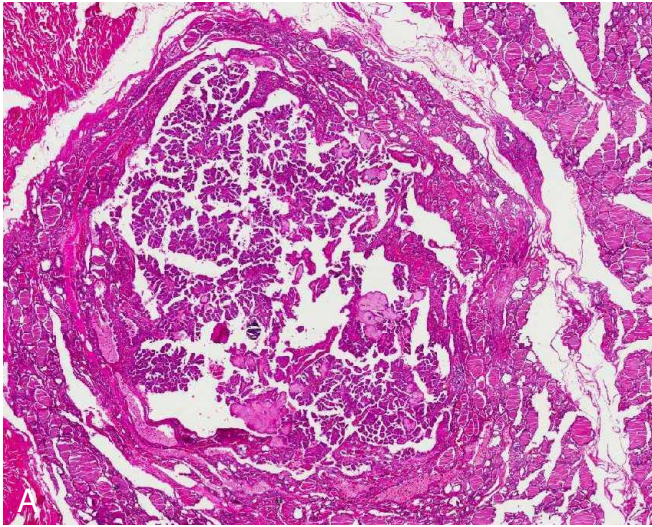


Figure 6. A, Circumscribed papillary thyroid carcinoma with a typical papillary growth pattern (hematoxylin-eosin stain, original magnification $\times 10$). **B,** Note the characteristics nuclear features: clearing appearance (ground glass), irregularity of nuclear contours, grooves, nuclear pseudoinclusions and overlapping (hematoxylin-eosin stain, original magnification $\times 400$). **C,** Some papillary structures are markedly edematous and calcification is a common feature (hematoxylin-eosin stain, original magnification $\times 100$). **D,** CK19 staining showing strong cytoplasmic and membranous reactivity of tumour cells (immunohistochemical staining, original magnification $\times 200$). **E,** HBME-1 staining showing cytoplasmic and membranous staining of tumour cells (immunohistochemical staining, original magnification $\times 200$). **F,** Galectin-3 showing cytoplasmic staining of tumor cells (immunohistochemical staining, original magnification $\times 200$).

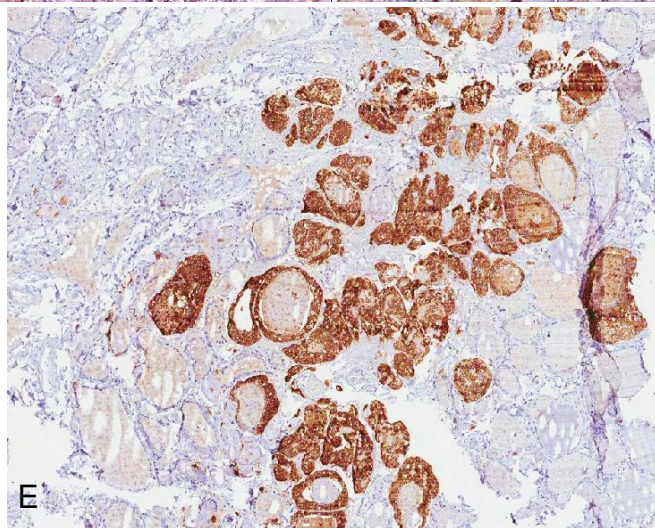
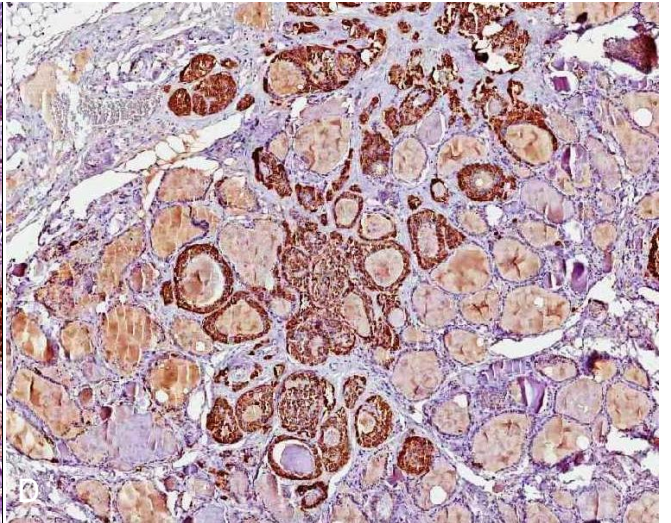
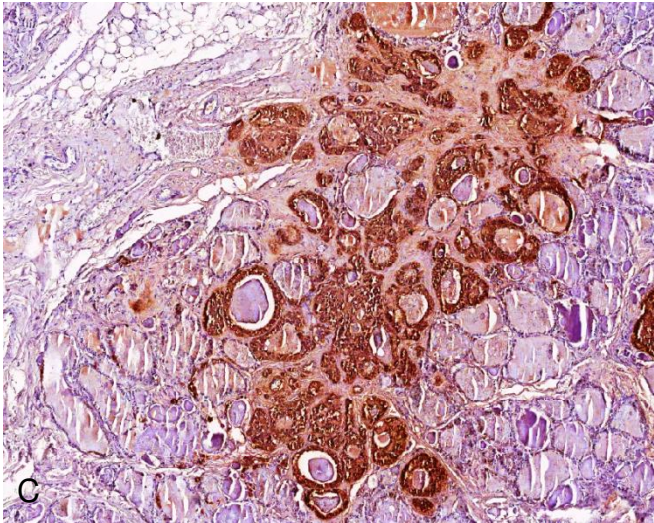
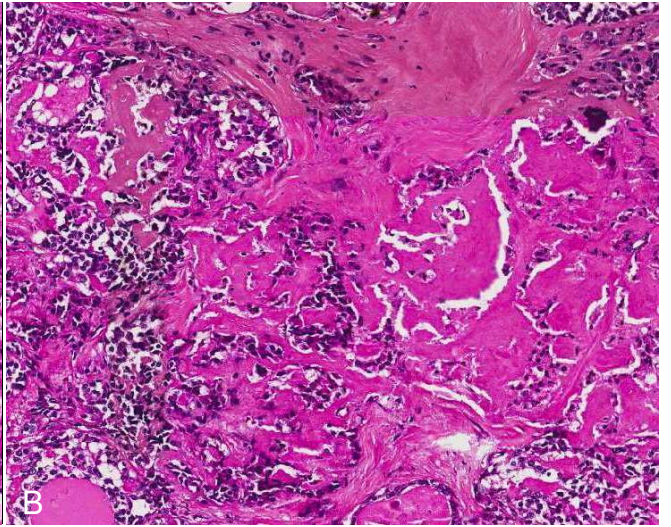
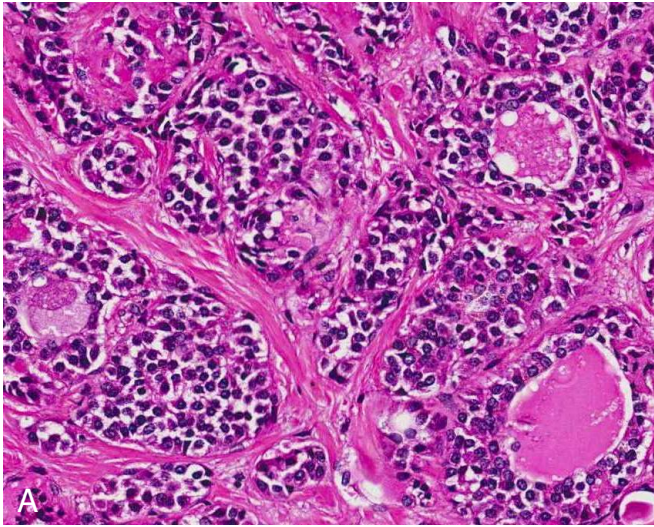


Figure 7. A, Medullary thyroid carcinoma with irregular sheets of polygonal cells and granular cytoplasm traversed by prominent fibrous septa (hematoxylin-eosin stain, original magnification $\times 200$). **B,** Note material compatible with amyloid deposition (hematoxylin-eosin stain, original magnification $\times 90$). **C, D** and **E,** Tumor cells showing immunopositivity for calcitonin, chromogranin A and carcinoembryonic antigen, respectively (immunohistochemical staining, original magnification $\times 50$).

TABLES

Table 1. Specificity, dilution, antigen retrieval and incubation of the antibody clones.

<i>Antibody</i>	<i>Clone[†]</i>	<i>Dilution</i>
CD45RO	UCHL	1:200
CD 20	L26(1,2)	1:1000
CD138	My15	1:50
Plasm cell	VS38c	1:400
CD3	CD3	1:400
CD79a	SCB117	1:1000
Cromogranina ^{AXR01}	Poli	1:20.000
Calcitonina ^{AMR03}	Poli	1:4000
CEA poli ^{AQR}	Poli	1:2000
CK19	B170	1:1000
HBME-1	HBME-1	1:400
Galectin-3	9c4	1:400

†Dako, Glostrup, Dinamarca

Table 2. Primer sequences and predicted product sizes

<i>Primers</i>	<i>Forward (5'-3')</i>	<i>Reverse (5'-3')</i>	<i>Predicted product size (bp)</i>
PCRG			
Outer primers	AGGCGTTGGTTCGCGAGGG	TGATGACGCCCTCGTTGCC	234
Inner primers	CCAACCCGCTCGGTCTCAA	CCGATGGACTGGTCACCC	142
FGFR2	CTGGCGGTGTTTTGAAATTAG	CCTTTCTTCTGGAACATTCTG	267

PCRG, polymerase chain reaction for Mycobacterium genus detection.

FGFR2, fibroblast growth factor receptor 2.

Table 3. Gender, age, CD4 counts, cause of death, autopsy and thyroid gland findings of AIDS patients.

Caso	Gender	Age (year)	CD4 count (cells/ μ l)	Causa of death	Major autopsy findings	Thyroid findings
1.	M	30	na	Disseminated mycobacteriosis	Disseminated mycobacteriosis; estrongiloidose tratada	Mycobacteriosis
2.	F	29	na	Tuberculose disseminada	Tuberculose disseminada; Septic shock	Mycobacteriosis
3.	M	29	77	Insuficiência respiratória	Bronchopneumonia; Mycobacteriosis disseminada; CMV	Mycobacteriosis
4.	M	34	na	Septic shock	Histoplasmose disseminada	Mycobacteriosis
5.	F	30	24	Bronchobronchopneumonia	Bronchopneumonia; arterioesclerose	Mycobacteriosis
6.	F	36	31	Pneumocystosis	Pneumocystosis; candidose esofageana	Mycobacteriosis
7.	M	46	12	Mycobacteriosis disseminada	Mycobacteriosis disseminada; histoplasmose disseminada	Mycobacteriosis
8.	M	30	67	Adult respiratory distress syndrome	Tuberculose pulmonar; neurotoxoplasmosis	Mycobacteriosis
9.	M	69	134	Disseminated mycobacteriosis	Disseminated mycobacteriosis	Mycobacteriosis
10.	M	51	na	Bronchobronchopneumonia	Bronchopneumonia; ARDS; Oral and esophageal candidiasis; Cryptosporidiosis	Mycobacteriosis + CMV
11.	M	24	na	Disseminated mycobacteriosis	Disseminated mycobacteriosis	Mycobacteriosis + Colloid goiter
12.	F	28	na	septic shock	Septic shock	Mycobacteriosis + Colloid goiter
13.	M	50	na	Septic shock	Disseminated mycobacteriosis; pulmonar CMV	Mycobacteriosis + Colloid goiter
14.	M	32	9	Disseminated mycobacteriosis	Mycobacteriosis disseminada; oral and esophageal candidiasis	Mycobacteriosis + Colloid goiter
15.	M	33	8	Disseminated cryptococosis	Disseminated cryptococosis	Cryptococosis
16.	M	50	18	septic shock	Bronchopneumonia; neurocryptococosis	Cryptococosis
17.	M	51	136	Acute respiratory insufficiency	CMV	CMV
18.	F	66	40	Neurocryptococosis	Disseminated cryptococosis	Papillary thyroid carcinoma
19.	M	26	15	Pneumocystosis	Pneumocystosis; CMV; mycobacteriosis	Papillary thyroid carcinoma
20.	F	25	10	Septic shock	Septic shock; pneumocystosis; poxoplasmosis; CMV	Papillary thyroid microcarcinoma
21.	M	31	na	bronchopneumonia	Pneumocystosis; acute respiratory insufficiency	Papillary thyroid microcarcinoma
22.	M	28	16	Cerebrovascular accident	AVCH; neurotoxoplasmosis	Medullary thyroid carcinoma + Colloid goiter
23.	M	22	236	Acute respiratory insufficiency	Disseminated B cells NHL	NHL
24.	F	47	13	Mycobacteriosis	Mycobacteriosis	Colloid goiter
25.	M	27	na	Disseminated cryptococosis	Cryptococosis	Colloid goiter
26.	F	30	5	Septic shock	Disseminated Herpes zoster; disseminated mycobacteriosis	Colloid goiter
27.	F	48	na	Cerebrovascular accident	Cerebrovascular accident; bronchopneumonia	Colloid goiter
28.	M	41	6	Septic shock	Cryptococosis; neurotoxoplasmosis; septic shock	Colloid goiter
29.	M	42	56	Acute pancreatitis	Pulmonary hemorrhage	Colloid goiter
30.	M	32	47	Septic shock	Septic shock; pneumonia	Colloid goiter
31.	M	27	10	Bronchobronchopneumonia	Bronchopneumonia; oral and esophageal candidiasis; CMV; septic shock	Colloid goiter
32.	M	35	na	Bronchobronchopneumonia	Bronchopneumonia; burkitt Lymphoma	Colloid goiter
33.	M	47	13	Acute respiratory insufficiency	Bronchopneumonia	Colloid goiter
34.	F	50	na	Septic shock	Septic shock	Colloid goiter
35.	F	38	35	Bronchopneumonia	Pulmonary tuberculosis; pneumonia	Chronic lymphocytic thyroiditis
36.	M	40	375	Septic shock	Bronchopneumonia; meningitis	Fat cells infiltration

REFERÊNCIAS

1. Abba AK, Lichtman AH, Pillai S. *Imunologia Celular e Molecular*. 6. ed. Rio de Janeiro: Elsevier; 2008.
2. Basílio-De-Oliveira CA. Infectious and neoplastic disorders of the thyroid in AIDS patients: an autopsy study. *Braz J Infect Dis*. 2000; 4(2): 67-75
3. Bonnyns M, Bourdoux P. Thyroid and AIDS. *Rev Med Brux*. 1995;16(5): 361-3.
4. Cayabyab M, Rohne D, Pollakis G, Messele T, Abebe A, Moghadam-Etmad B, Yang P, Henson S, Axthelm M, Goudsmit J, Letivin NL, Sodroski J. Rapid CD4+ T-lymphocyte depletion in rhesus monkeys infected with a simian-human immunodeficiency virus expressing the envelope glycoproteins of a primary dual-tropic ethiopian clade c HIV type 1 isolate. *AIDS Res Hum Retroviruses* 2004; 20(1): 27-40.
5. Frank TS, LiVolsi VA, Connor AM. Cytomegalovirus infection of the thyroid in immunocompromised adults. *Yale J Biol Med*. 1987;60:1-8
6. Jinno S, Chang S, Jacobs MR. Coccidioides thyroiditis in an HIV-infected patient. *J Clin Microbiol*. 2012; 50(7): 2535-7
7. Kiertiburanakul S, Sungkanuparph S, Malathum K, Prachartam R. Concomitant tuberculous and cryptococcal thyroid abscess in a human immunodeficiency virus-infected patient. *Scand J Infect Dis*. 2003; 35(1): 68-70.
8. Kumar V, Abbas AK, Fausto N, Mitchell RN. *Robbins – Patologia básica*. 8. ed. Rio de Janeiro: Elsevier; 2008.
9. do Lago RF, Costa NR. Policy dilemmas in providing antiretroviral treatment in Brazil. *Cien Saude Colet*. 2010;15(3):3529-40.
10. Lima MK, Freitas LL, Montandon C, Filho DC, Silva-Vergara ML. The Thyroid in Acquired Immunodeficiency Syndrome. *Endocr Pathol*. 1998; 9(3): 217-223.

11. Ministério da Saúde, Brasil. Boletim 1/2012 - Aids no Brasil. [Acesso 2012 Dez 5]. Disponível em: <http://portalsaude.saude.gov.br/portalsaude/>
12. Ramírez-Amador V, Anaya-Saavedra G, Martínez-Mata G. Oral Oncol. Kaposi's sarcoma of the head and neck: a review. 2010; 46(3): 135-45.
13. Unachukwu CN, Uchenna DI, Young EE Endocrine and metabolic disorders associated with human immune deficiency virus infection. West Afr J Med. 2009;28(1): 3-9.
14. Sasco AJ, Jaquet A, Boidin E et al. The challenge of AIDS-related malignancies in sub-Saharan Africa. PLoS One. 2010; ;5(1): e8621
15. UNAIDS. AIDSinfo. Epidemiological status. [Acesso 2012 Dez 3]. Disponível em: <http://www.unaids.org/en/dataanalysis/datatools/aidsinfo/>.
16. Vargas PA, Mauad T, Böhm GM, Saldiva PH, Almeida OP. Parotid gland involvement in advanced AIDS. Oral Dis. 2003; 9(2): 55-61.