



UNIVERSIDADE ESTADUAL DE CAMPINAS
Faculdade de Odontologia de Piracicaba

LIANA MATOS FERREIRA

**AVALIAÇÃO DOS SEIOS PARANASAIS POR
TOMOGRAFIA COMPUTADORIZADA DE FEIXE CÔNICO E
SEU USO PARA ANÁLISE DA RELAÇÃO ENTRE
ALTERAÇÕES DA MUCOSA DO SEIO MAXILAR E
MENSURAÇÕES DE ESTRUTURAS NASAIS**

**CONE BEAM CT EVALUATION OF PARANASAL SINUSES
AND ITS USE FOR ANALYSIS OF THE RELATION BETWEEN
SINUS MUCOSAL CHANGES AND NASAL STRUCTURES
MEASUREMENTS**

PIRACICABA

2018

LIANA MATOS FERREIRA

**AVALIAÇÃO DOS SEIOS PARANASAIS POR
TOMOGRÁFIA COMPUTADORIZADA DE FEIXE CÔNICO
E SEU USO PARA ANÁLISE DA RELAÇÃO ENTRE
ALTERAÇÕES DA MUCOSA DO SEIO MAXILAR E
MENSURAÇÕES DE ESTRUTURAS NASAIS**

**CONE BEAM CT EVALUATION OF PARANASAL SINUSES
AND ITS USE FOR ANALYSIS OF THE RELATION
BETWEEN SINUS MUCOSAL CHANGES AND NASAL
STRUCTURES MEASUREMENTS**

Tese apresentada à Faculdade de Odontologia de Piracicaba da Universidade Estadual de Campinas como parte dos requisitos exigidos para obtenção do título de Doutora em Radiologia Odontológica, área de Radiologia Odontológica.

Thesis presented to the Piracicaba Dental School of the University of Campinas in partial fulfillment of the requirements for the degree of Doctor in Oral Radiology, in Oral Radiology area.

Orientadora: Profa. Dra. Cinthia Pereira Machado Tabchoury

ESTE EXEMPLAR CORRESPONDE À
VERSÃO FINAL DA TESE DEFENDIDA
PELA ALUNA LIANA MATOS FERREIRA,
ORIENTADA PELA PROFA. DRA. CINTHIA
PEREIRA MACHADO TABCHOURY.

PIRACICABA

2018

Agência(s) de fomento e nº(s) de processo(s): CAPES, 33003033005P9

Ficha catalográfica
Universidade Estadual de Campinas
Biblioteca da Faculdade de Odontologia de Piracicaba
Marilene Girello - CRB 8/6159

F413a Ferreira, Liana Matos, 1987-
Avaliação dos seios paranasais por tomografia computadorizada de feixe cônico e seu uso para análise da relação entre alterações da mucosa do seio maxilar e mensurações de estruturas nasais / Liana Matos Ferreira. – Piracicaba, SP : [s.n.], 2018.

Orientador: Cinthia Pereira Machado Tabchoury.
Tese (doutorado) – Universidade Estadual de Campinas, Faculdade de Odontologia de Piracicaba.

1. Seio maxilar. 2. Sinusite maxilar. 3. Tomografia computadorizada de feixe cônico. I. Tabchoury, Cinthia Pereira Machado, 1969-. II. Universidade Estadual de Campinas. Faculdade de Odontologia de Piracicaba. III. Título.

Informações para Biblioteca Digital

Título em outro idioma: Cone beam CT evaluation of paranasal sinuses and its use for analysis of the relation between sinus mucosal changes and nasal structures measurements

Palavras-chave em inglês:

Maxillary sinus

Maxillary sinusitis

Cone-beam computed tomography

Área de concentração: Radiologia Odontológica

Titulação: Doutora em Radiologia Odontológica

Banca examinadora:

Cinthia Pereira Machado Tabchoury [Orientador]

Laura Ricardina Ramírez Sotelo

Milena Bortolotto Felipe Silva

Francisco Haiter Neto

Felippe Bevilacqua Prado

Data de defesa: 19-02-2018

Programa de Pós-Graduação: Radiologia Odontológica



UNIVERSIDADE ESTADUAL DE CAMPINAS
Faculdade de Odontologia de Piracicaba



A Comissão Julgadora dos trabalhos de Defesa de Tese de Doutorado, em sessão pública realizada em 19 de Fevereiro de 2018, considerou a candidata LIANA MATOS FERREIRA aprovada.

PROF^a. DR^a. CINTHIA PEREIRA MACHADO TABCHOURY

PROF^a. DR^a. LAURA RICARDINA RAMÍREZ SOTELO

PROF^a. DR^a. MILENA BORTOLOTTO FELIPPE SILVA

PROF. DR. FELIPPE BEVILACQUA PRADO

PROF. DR. FRANCISCO HAITER NETO

A Ata da defesa com as respectivas assinaturas dos membros encontra-se no processo de vida acadêmica do aluno.

Dedicatória

Aos meus pais **Nilza Matos da Silva** e **José Guilherme Rodrigues Ferreira** e meu irmão **José Guilherme Matos Ferreira**,

Vocês nunca mediram esforços para que eu pudesse alcançar os meus objetivos, principalmente os relacionados aos estudos, a base da minha educação. Nesta família, o esforço árduo de vocês sempre foi meu exemplo. Além de mostrar o melhor caminho, de me oferecer até o que não tinham pra me fazer sorrir, de por muitas vezes eu chegar cansada e me oferecerem o melhor conforto que um lar poderia ter. Muito obrigada pela dedicação, amor, renúncias, doação e carinho. Nunca será MINHA vitória, sempre será a NOSSA.

Agradecimentos

À **Faculdade de Odontologia de Piracicaba da Universidade Estadual de Campinas (FOP/UNICAMP)**,

Nas pessoas do diretor Prof. Dr. Guilherme Elias Pessanha Henriques e do diretor associado Prof. Dr. Francisco Haiter Neto. Da Prof^a. Dr^a. Cinthia Pereira Machado Tabchoury, coordenadora geral dos cursos de Pós-Graduação e do Prof. Dr. Matheus Lima de Oliveira, coordenador do curso de Radiologia Odontológica.

À **Coordenação de Aperfeiçoamento de Pessoal de Nível Superior (CAPES)**,

Na pessoa do diretor Prof. Dr. Carlos Lenuzza

À minha querida orientadora **Prof^a. Dr^a. Cinthia Pereira Machado Tabchoury**,

Pelo carinho, atenção, apoio e confiança. Tenho profunda admiração pela pessoa que és e um grande exemplo de dedicação ao trabalho. Sempre muito presente, nunca mediu esforços para me ajudar. Tenho certeza que sua atenção, profissionalismo, dinamismo e ensinamentos são de grande valia para todos os seus alunos. Foi uma honra ter sido sua orientada!

Aos professores de **Radiologia da FOP/UNICAMP**,

Prof^a. Dr^a. Deborah Queiroz de Freitas França, Prof. Dr. Frab Norberto Boscolo, Prof. Dr. Francisco Haiter Neto, Prof. Dr. Matheus Lima de Oliveira e Prof^a. Dr^a. Solange Maria de Almeida Boscolo. A nossa convivência, me proporcionou momentos de amadurecimento pessoal e profissional. Obrigada!

Aos professores examinadores da **banca de qualificação**,

Prof^a. Dr^a. Anne Caroline Costa Oenning, Prof. Dr. Luiz Franceschini Júnior, Prof. Dr. Paulo Henrique Ferreira Caria. Agradeço por aceitarem prontamente para participar da banca e pelas modificações sugeridas para este trabalho.

Aos professores examinadores da **banca de defesa**,

Prof^a. Dr^a. Cinthia Pereira Machado Tabchoury, Prof. Dr. Felipe Bevilacqua Prado, Prof. Dr. Francisco Haiter Neto, Prof^a. Dr^a. Laura Ricardina Ramírez Sotelo, Prof^a. Dr^a.

Milena Bortolotto Felipe e aos suplentes Prof Dr. Guilherme Monteiro Tosoni, Prof Dr. Luiz Roberto Coutinho Manhães Júnior e Prof. Dr. Matheus Lima de Oliveira. Agradeço por aceitarem prontamente para participar da banca e por suas colaborações para este trabalho.

Aos técnicos e funcionários da **Clínica de Radiologia da FOP/UNICAMP**, Sarah, Waldeck e Fernando, por facilitarem nosso trabalho e a nossa secretária, Lú, por resolver os problemas antes mesmo deles aparecerem.

Aos professores **da Anatomia da FOP/UNICAMP**, Prof. Dr. Alexandre Rodrigues Freire e Prof^a. Dr^a. Ana Cláudia Rossi, por estarem sempre disponíveis quando eu precisava sanar alguma dúvida.

Ao professor do **Departamento de Ciências Fisiológicas da FOP/UNICAMP**, Prof. Dr. Francisco Carlos Groppo, por ter realizado a estatística deste trabalho, pela paciência nas explicações e pela sempre disponibilidade quando solicitado (Não foram poucas as vezes).

Aos **amigos da FOP/UNICAMP**, Danieli Moura Brasil e Yuri Nejaim, que desde o início me ajudaram para que esse trabalho acontecesse e se desenvolvesse. Obrigada pelo companheirismo!

Aos **colegas e amigos da FOP/UNICAMP**, Amanda Candemil, Amanda Falcão, Amanda Farias, Amaro Vespasiano, Ana Pimentel, Aniele Lacerda, Anne Oenning, Carol Veloso, Cláudia Suzuki, Daniel Herrera, Débora Duarte Moreira, Débora Távora, Eliana Costa, Emmanuel Silva, Felipe Nogueira Anacleto, Fred Sampaio, Gabriella Rezende, Giancarlo De la Torre, Gustavo Santaella, Gustavo Souza, Henrique Maia, Hugo Gaetta Araujo, João Gabriel, Jonny Burga Sanchez, Jorge Valerio, Karla Faria Vasconcelos, Karla Rovaris, Larissa Lagos, Manuella Belém, Maria Beatriz Carrazone Cal Alonso, Mariana Nadaes, Marília Zeczkowski, Marlos Ribeiro, Mayra Yamasaki, Monikelly Nascimento, Neiandro Galvão, Phillipe Nogueira, Priscila Lopes, Rafaela Argento, Renato Ribeiro, Roberto Juns, Saulo Sousa Melo, Taruska Vasconcelos, Thaisa Cooper, Thiago de Oliveira Gamba, Tiago Barros Nascimento, Veber Bomfim, Victor de Aquino, Victor

Muñoz, entre outros, por compartilhar de sua alegria, companheirismo, amizade e experiências.

E ainda....

Bernardo Freire, Carol Valadares, Eduarda Helena Nascimento, Flávia Saavedra, Gina Roque Torres, Leonardo Vieira Peroni, Luciana Jácome, Polyane Mazuccato Queiroz, Raquel Werczler Thiago Oliveira Sousa, pelo convívio mais próximo, pelo abrigo quando ia pra Pira, pelo cuidado.

Às minhas chatinhas mais legais desse universo,

Ana Caroline Brito, Francielle Verner, Helena Aguiar, Ilana Sanamaika, Maria Augusta Visconti, Priscila Peyneau, um dos maiores tesouros que a FOP me deu. Ainda bem que temos o whatsapp para encurtar nossas distâncias. Vocês são maravilhosas!

Aos amigos de longa data,

Ana Lúcia Campos, Bruno Ricardo, Camila Martinho, Denise Freitas, Giovanna Monteiro, Jéssica Freitas, João Luis, Laila Rejane, Livia Lima de Moraes, Luana Carrijo, Marcos Morgado, Marjorie Louzada, Monique Ribeiro, Sarah Aquino, Victor Schuina, posso passar anos sem vê-los, mas o carinho continua o mesmo.

Aos membros da Brasil Soka Gakkai de Piracicaba/SP e Vila Velha/ES,

Profunda gratidão por nunca desistirem de mim. Diferentes em corpo, unos em mente.

Aos colegas e professores do curso de especialização em Radiologia Odontológica INCO25,

Prof^a. Dr^a. Andrea Domingues, Chris Santos, Luana Vasconcelos, Maria Lira Alves, Prof^a. Dr^a. Maria Lúcia Barbosa, Suelen Santos, Taiana Mattos, Vivian França, Prof^a. Claudia Coscarelli, Dalton Costa, pela amizade, conhecimento passado e adquirido. Contem sempre comigo.

À todos os meus alunos do Instituto de Odontologia da UFES/Vitória-ES,

Neste 1 ano e meio vocês foram responsáveis pelo meu enorme desenvolvimento como pessoa. Ofereci o melhor de mim e poder ver o amadurecimento de vocês com o passar do tempo foi gratificante. Obrigada por todo carinho dedicado à mim.

Aos amigos e professores do ambulatório 4, Instituto de Odontologia da UFES/Vitória-ES,

Profª. Drª. Danielle Camisasca, Profª. Drª. Daniella Nascimento, Profª. Drª. Liliana Barros, Profª. Drª. Martha Salim, Profª. Drª. Rosa Maia, Profª. Drª. Rossiene Bertollo, Profª. Drª. Tânia Velloso, Profª. Drª. Teresa Cristina e principalmente para o meu amigo de convívio direto, Prof. Dr. Sérgio Lins de Azevedo Vaz, obrigada por terem me recebido maravilhosamente bem, pela oportunidade de aprendizado e crescimento, por entenderem minha ausência em muitos momentos.

Aos meus familiares,

Meus avós (in memoriam), tios e primos (que são muitos!),

Meus pais Nilza e José Guilherme,

Meu irmão Guilherme, minha cunhada Andrea, meus sobrinhos Guilherme e Luiza

Amo todos, vocês são tudo pra mim! Saudades sempre!

Ao meu namorado/noivo/marido Tiago Rosa,

Obrigada pelo companheiro maravilhoso que é, por segurar minha barra nos piores momentos e dividir comigo os melhores momentos. Muitas vezes você me faz ver o mundo de outra forma, me tornando uma pessoa melhor. Estar com você, é o meu presente diário. Amo você!

Agradeço também pelo carinho que recebo da sua família: Dona Arlete e Seu Pedro; Maurício, Tati e Luiza; Daniel, Mariana e Dante. Além de toda a enorme família!

Àqueles que esqueci de citar e todas as pessoas responsáveis pelo meu engrandecimento pessoal e profissional, MUITO OBRIGADA!

*Para ser grande, sê inteiro: nada
Teu exagera ou exclui.
Sê todo em cada coisa. Põe quanto és
No mínimo que fazes.
Assim em cada lago a lua toda
Brilha, porque alta vive.*

Fernando Pessoa

RESUMO

Os objetivos neste estudo foram apresentar uma revisão de literatura para discutir o uso da Tomografia Computadorizada de Feixe Cônico (TCFC) para avaliação dos seios paranasais e, por meio de um estudo observacional, relacionar mensurações lineares, angulares e volumétricas de estruturas nasais com alterações muco sinusais dos seios maxilares e avaliar a influência do sexo nas variáveis. Para isso, foram utilizadas 240 imagens de TCFC, divididas em dois grupos: sem alterações sinusais (60 homens e 60 mulheres) e com alterações sinusais (60 homens e 60 mulheres). As imagens foram selecionadas a partir da base de dados do Departamento de Diagnóstico Oral/Área de Radiologia Odontológica da FOP/UNICAMP. Dois avaliadores radiologistas analisaram a angulação do septo, o diâmetro dos óstios dos seios maxilares, o volume do infundíbulo etmoidal e a condição da mucosa sinusal. Mensurações lineares e volumétricas foram realizadas nos softwares OnDemand3D™ (Cybermed, Tustin, CA) e ITK – SNAP (Penn Image Computing and Science Laboratory, Philadelphia, PA), respectivamente. Os resultados foram submetidos à análise estatística; teste Mann–Whitney foi utilizado para analisar a influência do sexo nas variáveis do estudo e teste de Kruskal-Wallis foi aplicado para verificar a existência de relação entre ausência/presença de alterações sinusais e as variáveis. Os resultados mostraram que o desvio de septo não apresentou relação com a presença de alterações sinusais; os diâmetros ântero-posteriores dos óstios dos seios maxilares não foram relacionados com a presença ou ausência de sinusopatias, porém os diâmetros látero-laterais se apresentaram menores na presença de espessamento mucoso e pólipos; as mulheres sem alteração sinusal apresentaram diâmetros látero-laterais dos óstios dos seios maxilares maiores do que os homens com e sem alteração; os volumes dos infundíbulos etmoidais não apresentaram diferenças na presença/ausência de alterações sinusais. Concluiu-se que pacientes com espessamento mucoso e pólipos nos seios maxilares possuem diâmetros dos óstios reduzidos. As alterações sinusais não possuem relação com a presença do desvio de septo e não afetam o volume do infundíbulo etmoidal. Não houve influência do sexo nas variáveis. A TCFC fornece imagens com grandes detalhes anatômicos e pode ser um método de escolha para a análise do complexo óstio-meatal.

Palavras-chave: Seio maxilar. Sinusite maxilar. Tomografia Computadorizada de Feixe Cônico.

ABSTRACT

The aim of this study was to expose the literature review in order to discuss the use of Cone Beam Computed Tomography (CBCT) for evaluation the paranasal sinus; correlate the linear, angular and volumetric measurements of nasal structures with maxillary sinus mucosal changes and evaluate the influence of sex on study variables, by an observacional study. For this, 240 CBCT images were used and divided into two groups: without sinus change (60 men and 60 women) and with sinus change (60 men and 60 women). The images were selected from the database of the Department of Oral Diagnosis/Division of Oral Radiology of FOP/UNICAMP. Two radiologists observers evaluated septum deviation, maxillary sinus ostium diameters, ethmoidal infundibulum volume and mucosa conditions. The linear and volumetric measurements were done using the software OnDemand3D™ (Cybermed, Tustin, CA) and ITK-SNAP (Cognitica, Philadelphia, Pa, EUA), respectively. The data was subjected to statistical analysis; the Kruskal-Wallis test was used to verify the existence of a relationship between the absence / presence of sinus changes and other variables analyzed in the study. The Mann-Whitney test was used to analyze the influence of sex and the variables. The results showed that the presence of septal deviation was not related to the presence of sinus change; the presence or absence of sinus change did not influence the anteroposterior ostium diameter, but latero-lateral ostium diameter were smaller in the presence of thickening and polyp; women without sinus change showed latero-lateral ostium diameters greater than men with and without sinus change; ethmoidal infundibulum volume did not show differences in the presence/absence of sinus change. It was concluded that patients with mucosal thickening and polyp in maxillary sinuses have reduced ostium diameters. Maxillary sinus changes do not affect the volume of the infundibulum and are not related with septal deviation. There was no influence of sex on variables. CBCT generates images with great anatomical details and may be an interesting option on the analysis of ostiomeatal complex.

Keywords: Maxillary Sinus. Maxillary Sinusitis. Cone-Beam Computed Tomography.

SUMÁRIO

1 INTRODUÇÃO	15
2 ARTIGOS	19
2.1 ARTIGO - The Fundaments of CBCT and its use for evaluation of Paranasal Sinuses: Review of Literature.....	19
2.2 ARTIGO – Relation of linear and volumetric measurements of nasal structures with sinus mucosal changes.....	34
3 DISCUSSÃO	51
4 CONCLUSÃO	56
REFERÊNCIAS*	57
APÊNDICE 1 – Detalhamento da metodologia	64
ANEXO 1 – Documentos para fins de comprovação de submissão do artigo	71
ANEXO 2 – Certificado do Comitê de Ética em Pesquisa.....	72

1 INTRODUÇÃO

Os seios da face ou paranasais são cavidades pneumáticas, que se distribuem em número de quatro, e seus nomes derivam dos ossos em que estão localizados: maxilar, frontal, etmoidal e esfenoidal (Karataş et al., 2015). Dentre eles, o seio maxilar é o maior e o primeiro a se desenvolver, com início no 3º e 4º mês de vida fetal. No período pós-natal, o crescimento dos seios maxilares aumenta nos primeiros 3 anos e continua até os 12 anos de idade (Parks, 2014; Okşayan et al., 2017). O tamanho varia de indivíduo para indivíduo e até na mesma pessoa, mas possui como média para um ser humano adulto as medidas de 37 mm de altura, 27 mm de largura, 35 mm de extensão ântero-posterior e 15 ml de volume (Kretzschmar e Kretzschmar, 2003). Apresenta-se como uma cavidade bilateral, revestida por epitélio colunar ciliado pseudoestratificado, preenchida por ar, localizada no corpo da maxila, com formato piramidal e, juntamente com os outros seios paranasais, apresenta funções de reduzir o peso do crânio, contribuir na ressonância vocal, equilibrar a pressão na cavidade nasal durante as variações barométricas e auxiliar na secreção de muco (Masri et al., 2013; Oz et al., 2017). Para o adequado desempenho desta última função, deverá existir o equilíbrio entre a produção de muco e o movimento das células mucociliares em conduzi-lo para fora dos seios paranasais (Toskala e Rautiainen, 2005; Bandyopadhyay et al., 2015).

Existem dois canais principais de drenagem dos seios paranasais: (1) A unidade óstio-meatal, sistema que drena os seios frontal, maxilar e etmoidal anterior e médio, e que inclui o óstio do seio frontal, o recesso frontal, o óstio do seio maxilar, o infundíbulo etmoidal, o processo uncinado, a bulla etmoidal, o hiato semilunar, a concha nasal média e o meato médio (Tomomatsu et al., 2014); (2) O recesso esfenoetmoidal, que drena apenas as células etmoidais posteriores e os seios esfenoidais (Parks, 2014). Nos seios maxilares, o muco secretado pelas células mucociliares é constantemente transferido para o óstio, passando pelo infundíbulo etmoidal até chegar a cavidade nasal. Os óstios são revestidos por mucosa, possuem aproximadamente 4 mm de diâmetro e estão localizados superiormente na parede medial dos seios maxilares (Kretzschmar e Kretzschmar, 2003). O infundíbulo etmoidal é uma cavidade em forma de funil, que liga o seio maxilar/óstio à cavidade nasal (Rao e el-Noueam, 1998). O bloqueio da unidade óstio-infundíbulo e/ou dano à

função das células mucociliares podem levar à retenção de muco nos seios e consequentemente a sinusites (Carmeli et al., 2011; Capelli e Gatti, 2016).

Alguns autores (Bandyopadhyay et al., 2015; Lee et al., 2016) sustentaram a hipótese que variações anatômicas presentes na cavidade nasal podem constituir fatores obstrutivos ao complexo óstio-meatal, como: desvio ou esporão do septo nasal, hiato semilunar, células de *Haller*, células de *agger nasi* e concha bolhosa (Pérez-Piñas et al., 2000; Aramani et al., 2014; Bandyopadhyay et al., 2015). Dentre elas, se destaca o desvio de septo, que de acordo com estudos (Pérez-Piñas et al., 2000; Aramani et al., 2014; Kucybała et al., 2017) é a alteração mais prevalente entre os indivíduos. Apresenta-se como uma curva assimétrica do septo nasal que pode comprimir a concha nasal média ipsilateralmente, estreitando o meato médio e infundíbulo etmoidal (Codari et al., 2015; Serifoglu et al., 2017). Tal situação pode levar ao desenvolvimento de sinusites, que no seio maxilar é definida como um espessamento mucoso maior que 3 mm (Kapusuz Gencer et al., 2013; Karataş et al., 2015; Kucybała et al., 2017). A sinusite pode ser classificada de quatro formas, baseadas nos sinais, sintomas e no curso da doença: 1) Sinusite aguda – Aparecimento súbito dos sintomas com resolução completa dentro de 4 semanas, 2) Sinusite subaguda – Continuação da sinusite aguda além de 4 semanas, mas por menos de 12 semanas, 3) Sinusite aguda recorrente – Quatro ou mais episódios de sinusite aguda dentro de 1 ano, 4) Sinusite crônica – Sinais e sintomas persistentes por mais de 12 semanas (Kretzschmar e Kretzschmar, 2003; Pilan et al., 2012). Os sintomas iniciais são dores na face e nas porções infra-orbitais, que geralmente se inicia com uma infecção viral. A remissão das manifestações é feita com terapia de suporte sintomático e, caso o processo da doença progrida para uma infecção bacteriana, há a necessidade de antibioticoterapia (Kretzschmar e Kretzschmar, 2003). Se ainda assim os tratamentos convencionais falharem, a intervenção cirúrgica é indicada (Carmeli et al., 2011).

A sinusite é uma das doenças mais frequentes em todo o mundo, com prevalência e incidência em constante aumento. Dados estatísticos estadunidenses indicam que a sinusite é mais prevalente do que diabetes mellitus, artrite, doenças cardíacas e dores de cabeça (Gündoğdu et al., 2014). Neste mesmo país, há um gasto anual de 8,6 bilhões de dólares por ano para o diagnóstico desta condição patológica, sendo 150 milhões de dólares despendidos com antibióticos, com um em cada 7 indivíduos americanos (cerca de 12,5%) afetados (Pilan et al., 2012; Zojaji et al.,

2015). Na população europeia, esta taxa varia de 6,9 a 27,1% da população atingida (Kucybała et al., 2017). Um estudo epidemiológico realizado no Brasil em 2002 (Pilan et al., 2012) revelou que a cidade de São Paulo possui uma taxa de 5,51% de pessoas afetadas por essa condição.

O diagnóstico de certas condições sinusais unicamente por exame clínico não é possível em todos os casos, havendo a necessidade do profissional lançar mão de ferramentas auxiliares. Os recursos mais utilizados para este fim são os exames imaginológicos (Cagici et al., 2005), que permitem avaliar com precisão a anatomia e patologia dos seios paranasais, mudanças ou variações ósseas e a aparência da mucosa sinusal (Fatterpekar et al., 2008; Ritter et al., 2011). As técnicas de imagem disponíveis que podem ser utilizadas nessas situações incluem: Endoscopia Sinusal (ES), Radiografia Bidimensional (RB), Imagem por Ressonância Magnética (IRM), Tomografia Computadorizada (TC) e Tomografia Computadorizada de Feixe Cônico (TCFC) (Eggesbø, 2006; Campbell et al., 2009; Vallo et al., 2010; Demeslay et al., 2015). A ES é realizada pela introdução de um cabo de fibra ótica flexível de 4 mm na cavidade nasal. É um método invasivo e dispendioso que necessita de anestesia local ou geral, com limitação de uso em alguns pacientes (Hosemann e Draf, 2013; Zojaji et al., 2015). Por muitos anos, a RB foi utilizada para a avaliação das estruturas nasais e paranasais (Cagici et al., 2005), porém ela exhibe estruturas tridimensionais em planos bidimensionais, fornecendo detalhes insuficientes para um planejamento cirúrgico, por exemplo. Na melhor das hipóteses, ela propicia uma visão geral da patologia e anatomia subjacente (Cakli et al., 2012). A IRM é ideal para avaliar tecido mole, mucosa e extensão de doenças infecciosas/malignas para além dos seios paranasais. Apesar do uso da radiação não ionizante e excelente definição de tecido mole serem vantagens desta técnica (Fatterpekar et al., 2008; Güldner et al., 2011), ela não proporciona uma boa definição de tecido ósseo, um ponto crítico para a análise da região anterior do crânio, onde está localizado o seio maxilar (Rafferty et al., 2005). Por outro lado, a TC e a TCFC possibilitam representações adequadas das paredes ósseas e óstios dos seios paranasais, permitindo visualizações em reconstruções tridimensionais (axial, sagital e coronal), mapeando com precisão a anatomia e patologia dos tecidos sinusais (Güldner et al., 2011; Shahbazian e Jacobs, 2012). Apesar de ambas as modalidades apresentarem eficácia similar para a análise dos seios paranasais, a TCFC vem ganhando notoriedade para o diagnóstico imaginológico da região de cabeça e pescoço, ouvido, nariz e garganta, espessura de

mucosa, desvio de septo nasal, hipertrofia de concha nasal, concha bolhosa e retenção de cistos (Ritter et al., 2011; Zojaji et al., 2015; Nascimento et al., 2016), principalmente por apresentar alta resolução de imagem, baixa dose de radiação e baixo custo, quando comparada a TC (Shahbazian e Jacobs, 2012; Aramani et al., 2014). Em acréscimo, a TCFC tem sido utilizada como ferramenta auxiliar em cirurgias endoscópicas, por exibir imagens em tempo real (Campbell et al., 2009), em que o aparelho é modificado para possuir um braço em forma de “C”, o que permite maior flexibilidade e mobilidade dentro de centros cirúrgicos (Linsenmaier et al., 2002; Rafferty et al., 2005).

Em vista disso, o presente estudo é dividido em dois capítulos com os seguintes objetivos: Capítulo 1 – apresentar uma revisão de literatura, discutindo o uso da TCFC para a avaliação dos seios paranasais; Capítulo 2 - Por meio de um estudo experimental, avaliar o complexo óstio-meatal dos seios maxilares em imagens de TCFC; mensurar os diâmetros ântero-posterior e látero-lateral dos óstios dos seios maxilares, o volume do infundíbulo etmoidal, o grau de desvio de septo, avaliar a influência do sexo nas variáveis e as possíveis correlações com as alterações sinusais nos seios maxilares.

2 ARTIGOS

2.1 ARTIGO - The Fundaments of CBCT and its use for evaluation of Paranasal Sinuses: Review of Literature

*Este artigo foi submetido ao periódico Brazilian Journal of Oral Sciences (Anexo 1)

Abstract

Image methods such as Magnetic Resonance Imaging (MRI), Computed Tomography (CT) and Cone Beam Computed Tomography (CBCT) are powerful tools to help clinicians on diagnosis and preoperative planning. They provide an accurate view of regional anatomy, anatomical variations and the presence of diseases. Compared to CT, CBCT produces images with adequate spatial resolution with smaller fields of view at lower radiation doses. It has emerged as a potential alternative for obtaining 3D evaluation of the paranasal sinus at relatively modest costs. The aim of this review was to verify whether CBCT images offer an additional value to the evaluation of paranasal sinus.

Keywords: Paranasal Sinuses. Diagnostic Imaging. Cone Beam Computed Tomography.

Introduction

The purpose of radiological evaluation of the paranasal sinuses and related structures is to provide an accurate description of the regional anatomy, any osseous changes or variations, sinus mucosa, fluid levels and to establish the presence and extent of diseases ^{1,2}. Available imaging techniques that might be used in this situation include two-dimensional X-rays, like Waters' and panoramic, Computed Tomography (CT), Magnetic Resonance Imaging (MRI), and more recently Cone-beam computed tomography (CBCT) ^{1,3}. Plain films are widely available; however, provide insufficient detail to allow surgical planning. At best, they give only an overview of the anatomy and underlying pathology, as they are limited to displaying three-dimensional structures in a two-dimensional plane. The technological advances in radiological imaging from 2D projection radiography towards 3D and interactive imaging applications have made an enormous impact in head imaging and have increased surgeon's ability to depict accurately the status of structures within the paranasal sinus region and to delineate the location and extent of pathology ^{4,5}. Multidetector CT (MDCT) and MRI have the advantage of being able to show fine anatomic detail in serial tomographic sections ¹. MRI allows excellent visualization of soft tissues, but does not adequately represent the bone walls and paranasal sinuses ostia; on the other hand, MDCT provides a lot of information, both about the bony part as soft tissue, remaining as technique of choice for assessing the presence and extent of disease in the paranasal sinuses. Additionally, the coronal sections perpendicular to the hard palate allow optimal viewing ostiomeatal complex ¹.

Introduced in 1998, CBCT is increasingly used for 3-dimensional imaging in maxillofacial radiology, generates high-resolution isotropic volume data and could, therefore, show benefits for evaluating the bony aspects of the maxillary sinus by using a lower dose of radiation ². Although CT is considered as the "gold standard" in imaging for visualization of the paranasal sinus, CBCT is gaining increasing popularity in this respect ⁴. Even though, a large dose of ionizing radiation is generally delivered by medical computed tomography; in this way, CBCT technology has achieved considerable reduction of absorbed radiation doses, with equal image qualities and less artifacts for visualizing the maxillofacial bone structures compared to MDCT imaging ⁶.

Paranasal sinus 3D images are relevant for the planning of procedures, since it allows the direct visualization of anatomical variations and pathological

conditions, which when combined with the clinical examination, can provide to the patient treatment options or referral to specialists, in cases that are not directly linked to dentistry. Therefore, this review of literature aims to present the fundamentals of CBCT as well its application on evaluation of paranasal sinuses.

Paranasal Sinus Image Techniques – Comparative Aspects

For many years, conventional X-rays, like panoramic and Water's radiography, have been used to investigate the paranasal sinuses³. However, 2D radiographic images are difficult to interpret because of the overlapping of ostiomeatal complex and osseous structure⁷. Generally, they are efficient to display the regional morphology, characterize the extent and localization of disease and describe anatomical variants of paranasal sinuses⁸; however, radiographic images allows limited value in the diagnosis of maxillary sinusitis and is less sensitive for detecting abnormalities in other sinuses³.

MRI is ideal for assessing soft-tissue masses, mucosa and extension of infectious/malignant disease processes beyond the paranasal sinuses. Imaging of the paranasal sinuses must include high-resolution (3 mm) T1-weighted and T2-weighted images, not only of the sinonasal cavity but also of the orbit, skull base, and the adjacent intracranial compartment¹, which is provided by MRI. The use of non-ionising radiation is an advantage of this technique^{1,8}. While offering excellent soft tissue definition, MRI provides poor bony definition, which is so critical in the frontal sinus and anterior skull base⁹.

MDCT is a valuable tool⁸ for confirmation the clinical diagnosis of the paranasal sinuses, provides detailed images of the sinuses and gives the examiner a clear view of the areas that are key in the pathogenesis of rhinosinusitis. MDCT also reveals the anatomical details of the nose and paranasal sinuses in relation to vital adjacent structures³ and allows 3D observation and clear visualization of the inflammatory changes and pathologic status in the nasal and paranasal sinus mucosa¹⁰. The treatment of choice of chronically infected sinuses is the surgical clearance that maintains the ventilation and drainage. To achieve this goal, there should be some diagnostic modalities, which guide towards exact diagnosis and safe intervention. Over the past few decades, both MDCT and nasal endoscopy have been used successfully as diagnostic modalities in sinus disease^{5,11}. Moreover, MDCT imaging of sinonasal region has become the gold standard in the evaluation of patients with chronic sinusitis.

Its ability to accurately map out the bony and soft tissue anatomy of the paranasal sinuses has proven invaluable to the endoscopic surgeon ability to depict accurately the status of structures within the paranasal sinus region and to delineate the location and extent of pathology ⁵.

Despite the fact that MDCT scan of the paranasal sinuses can be recommended in case of normality and abnormality of the paranasal sinuses or in patients with chronic sinusitis, the high radiation dose and costs do not allow its usage routinely ^{7,10,12}. After all, the MDCT cannot stand alone as a gold standard for the diagnosis of rhinosinusitis because it may be positive in the absence of clinical disease. History and physical examination should be taken into consideration when evaluating the MDCT scan. If MDCT findings are not interpreted in light of signs and symptoms, a person with incidental abnormal findings may be labeled as having a sinus condition. In such cases, the diagnosis is incorrect, and inappropriate treatment is often initiated ³.

Nevertheless, in the last two decades, CBCT has been emerging, and now, it is widely used in dentistry, due to its high image resolution, low radiation dose and low costs, compared to MDCT. Moreover, the boundaries between empty spaces and soft tissues or bones are well defined ^{10,11}. Because of these advantages, CBCT currently has become a valuable method for the evaluation paranasal sinus. Further prospective studies are required to confirm that.

CBCT

CBCT is a 3-dimensional (3D) X-ray-based volume acquisition imaging modality, first introduced in 1998 ¹². Offering the advantage of lower radiation dose ^{4,8,12-14}, CBCT has been widely used in dental practice for various purposes such as maxillary sinus evaluation, oral surgery, evaluation of temporomandibular joint, orthodontic evaluation, implant planning, and craniofacial trauma evaluation and treatment ^{2,7,12}. After these primary applications, CBCT has gained popularity and is now increasingly being used for the diagnostic imaging of the head and neck region and the ear, nose, and throat area, mucosal thickness, nasal septum deviation, conchal hypertrophy, bullous concha, and retention cysts in these areas ^{2,12,14}. In CBCT systems, the X-ray beam forms a conical geometry between the source and the detectors; in addition, digital flat-panel detectors replace the row(s) of detectors in MDCT. As result, a major difference is the isotropic nature of acquisition and

reconstruction that is used in CBCT systems (i.e., cubic voxels). The fact that each voxel is isotropic explains the high fidelity of the reconstructions in any plane used in CBCT imaging ^{4,14}. The main advantages of CBCT over MDCT scanning are lower radiation dose (around 10 times lower), lower costs, shorter scanning time, providing very thin slices in any plane, automatic generation of surface and volume reconstructions, easy access, and higher spatial resolution ^{4,7,8,10,12,14–16}.

Technical aspects of CBCT

The cone-beam technique involves a single scan of 360° for the majority of machines, in which the x-ray source and a reciprocating area detector synchronously move around the patient's head, which is stabilized with a head holder ¹⁷. During the rotation, multiple (from 150 to more than 1000) sequential planar projection images of the field of view (FOV) are acquired. The dimensions of the FOV or scan volume able to be covered depend primarily on the detector size and shape, the beam projection geometry, and the ability to collimate the beam. The shape of the scan volume can be either cylindrical or spherical (eg, NewTom 3G). Collimation of the primary x-ray beam limits x-radiation exposure to the region of interest selected by the professional. Field size limitation, therefore, ensures that an optimal FOV can be selected for each patient, based on disease presentation and the region designated to be imaged. CBCT systems can be categorized according to the available FOV or selected scan volume height as follows: **Localized region:** approximately 5 cm or less (eg, dentoalveolar, temporomandibular joint); **Single arch:** 5 to 7 cm (eg, maxilla or mandible); **Interarch:** 7 to 10 cm (eg, mandible and superiorly to include the inferior concha); **Maxillofacial:** 10 to 15 cm (eg, mandible and extending to Nasion); **Craniofacial:** greater than 15 cm (eg, from the lower border of the mandible to the vertex of the head) ¹⁷. In general, small FOV and high-resolution scans are optimal for detailed diagnostic tasks (e.g. endodontics), while large volume scans will be able to deliver better 3D models and a comprehensive radiologic view of the maxillofacial skeleton and partly of the soft tissue therein ^{2,7}.

Effective dose of CBCT

The effective dose takes into account the radiation dose produced by the imaging system and the radiation sensitivity of the tissues that the X-ray beam is passing through during the exposure sequence. Effective dose is measured in Sieverts

(Sv) and is often expressed in microsieverts (μSv)¹⁸. The radiation dose produced by a CBCT system is dependent on a number of factors: the nature of the X-ray beam i.e. whether it is continuous or pulsatile, the degree of rotation of the X-ray source and detector and the size of the FOV. Moreover, the amount and type of beam filtration and the kV, mA and voxel size settings may also influence¹⁹. Although MDCT is the gold standard for radiologic examination of the paranasal sinuses⁸, CBCT in dental and sinus applications is generally considered as a low-dose alternative to MDCT scanners^{2,4}. This dose reduction is significant because radiosensitive organs are present in the field explored during sinus imaging, particularly of pediatric patients¹⁴.

Advantages of CBCT

As exposed previously, CBCT technology has emerged as a potential alternative for obtaining 3D evaluation of the paranasal sinus at relatively modest costs, with easy access and a short scanning time compared with MDCT and MRI^{4,7,8,12,20,21}. CBCT exposes the patient to substantially lower radiation compared with standard MDCT and, although MRI is still superior in soft tissue rendering, its use is limited by its cost and restricted accessibility¹³. CBCT has become a diagnostic method to analyze airways characteristics, craniofacial growth, dentomaxillofacial pathology and obstructive sleep apnea¹³, considering its capacity to define the boundaries between soft tissue and empty spaces (air) accurately.

The advantage of reduced CBCT exposure over MDCT can be explained due to the conical geometry of the X-ray beam and to the pulsed rather than continuous emission in majority of the machines²⁰, which means that actual exposure time is markedly less than scanning time. This technique considerably reduces patient radiation dose¹⁷. With correct patient positioning, a selected volume of 10 x 10 cm is sufficient to display the nasal cavity, lateral nasal wall, paranasal sinuses and adjacent vital structures²². CBCT generally acquires all basis projection images in a single rotation, so scan time can be minimized. An entire head sometimes can be scanned in 10 s or less⁴, with realistic representation. Added to this, CBCT imaging of the sinuses provides excellent contrast between air and mucosa.¹⁴ These advantages make the system attractive for scanning paranasal sinus.

Limitations of CBCT

The main drawback of CBCT is its dynamic range, which is insufficient for displaying contrast within soft tissue and the presence of metal artefact^{8,10,23}. The contrast resolution is limited by scattered radiation and the divergence of the x-ray beam over the area detector that produces a large variation in, or no uniformity of, the incident x-ray beam on the patient. These factors contribute to increased image noise. With regard to metal, an artifact is any distortion or error in the image, unrelated to the subject being studied, that can impair the diagnostic¹⁷. It happens when the CBCT X-ray beam encounters an object of very high density (eg, metallic restorations, dental implants), with absorption of lower energy photons in the beam by the structure rather than higher energy photons; then, the mean energy of the X-ray beam increases. This is called 'beam hardening' and the phenomenon produces two types of artifact: distortion of metallic structures and the emergence of streaks and dark bands between two dense structures^{19,24}.

Applications of CBCT in paranasal sinus

A. Intraoperative guidance

CBCT generates images in the coronal, axial, sagittal, parasagittal (Figure 1) and any other planes that the professional needs. These three dimensional information can be used to assist the surgeon in the preoperative planning endoscopic sinus surgery and allow the surgeon to correlate positional information regarding the patient's anatomy as it is observed intraoperatively with a radiological image obtained preoperatively, reducing the risk of serious complication^{9,22,25}. Endoscopy of the paranasal sinuses allows the observation of anatomical areas and the evaluation of sinonasal lesions and their relationship with endonasal structures. However, endoscopy is an invasive and costly method, needs local or general anesthesia, cannot be applied to all patients and may be associated with severe complications. Regarding these limitations, finding an alternative diagnostic modality is beneficial. CBCT may be an alternative modality for diagnostic sinus endoscopy¹².

Intraoperative imaging offers the potential to improve surgical performance in existing procedures, extend the applicability of surgery to cases that would be otherwise inoperable, and has great potential utility in training surgeons, facilitating advancing the novice surgeon from a 2D to a more complete 3D^{9,15,25}. Besides that, it

is especially desirable in areas that are close to vital anatomical structures, distorted anatomy, extensive sino-nasal polyposis and increased risk of intraoperative bleeding¹⁵.

B. Inflammatory pathology

Periapical inflammation was shown to be capable of affecting the maxillary sinus mucosa with and without perforation of the cortical bone of the sinus floor²⁶ (Figure 2). Untreated dental condition can cause odontogenic sinusitis that can be presented in various ways, and they are particularly characterized by inflammation and localized mucosal thickening^{21,26}. The accurate identification of changes in the maxillary sinus with CBCT could provide the size and location of the periapical lesion, and also would help deciding if the teeth need to be treated, retreated or surgical procedure yet²⁶.

Regarding the frontal sinus, some cells can block it at the level of frontal recess, causing frontal sinusitis, mainly because of inadequate removal of agger nasi and frontal recess cells during endoscopic sinus surgery. CBCT multiplanar reconstruction could be used to identify potential causes of frontal recess stenosis and evaluates all of the cell anatomical variable with a lower use of radiating energy⁹.

Data gained from the CBCT scans, in addition to clinical impression and endoscopy, suggest that such images provide useful radiologic documentation for the diagnosis of chronic rhinosinusitis⁴, effusion, mucosal thickening and ostial obstruction are perfectly visible, with precision equal to or greater than that of MDCT. Any inflammatory or infectious sinus pathology is accessible to CBCT examination, with complete topographic exploration²¹.

C. Implant placement

For dental implant site assessment in the maxilla, the configuration and status of the maxillary sinus is important to assess the available amount of bone (Figure 3), principally if a sinus lift is indicated^{2,27}. Incidental findings such as mucosal thickening can be associated with a sinus outflow obstruction which can impact on the clinician's treatment decisions²³. Maxillary sinus septa are barriers of cortical bone that divide the maxillary sinus floor into multiple compartments, known as recesses²⁸. It seems that an antral septa, detected in almost half of the CBCT exams, might increase

the risk of sinus membrane perforation during the maxillary sinus floor elevation surgery²⁸. MDCT and CBCT are definitely the preferred imaging techniques for the assessment of this anatomic variation²⁷.

D. Anatomical variations

The imaging investigation of anatomical variations (Figure 4) of the paranasal sinuses is important in assessing the predisposing factors for inflammatory changes of the paranasal sinuses. These changes in the sinuses are a common problem encountered in clinical practice. The most encountered variations are the concha bullosa, Haller cell presence and the modifications of the uncinate process morphology and positions. The Haller cell is an asymptomatic maxilla ethmoidal cell and, in some situations, may narrow the osteo-meatal complex, inhibiting the ciliary function and leading to obstruction of the ostium. The uncinate process allows air flow and mucus drainage. Morphological variations of this hook-like process might be a factor of narrowing the unit and, thus, blocking the drainage and consequently producing inflammation¹¹. Concha bullosa may be implicated as a possible etiological factor in the causation of recurrent chronic sinusitis, due to its negative influence on paranasal sinus ventilation and mucociliary clearance in the middle meatus region¹¹.

The nasal septum deviation is also among the most observed anatomical variations¹¹. This condition may cause compression of the nasal concha laterally, with consequent obstruction of the infundibulum, presenting clinical importance in the approach of recurrent sinusopathy⁵.

E. Volumetric evaluation

CBCT has become a widely used imaging modality for evaluating maxillary sinus volume. It is used to investigate changes before and after rapid maxillary expansion²⁹, gender assessment¹³ and the effects of long-term oral breathing⁶. Additionally, a simulated system for medical training in upper air way related surgery can be built from the surface model. A CBCT air way segmentation scheme will provide extra information in the case of patients who have already undergone CBCT scans for other treatments such as orthodontics without the need of a high radiation dose of MDCT¹⁶. Furthermore, the frontal sinus cavity can be segmented and reconstructed for determining sex and person identification³⁰.

Final Considerations

This review paper highlights the potential uses of CBCT in the assessment of paranasal sinuses and confirms that it is an accurate and reliable tool. Plain films offer limited information about the paranasal sinuses, with the inherent errors of a 2D representation of a 3D structure and the lack of information about cross-sectional area and volume. CBCT will eventually become the gold standard in routine sinus exploration, because it combines good image quality, even at low radiation exposure, short examination time, easy use and low cost in relation to MDCT and MRI. Besides, nowadays the volumetric evaluation of the paranasal sinus has been easily achieved by several open-access softwares. The technique's limitations, however, need to be borne in mind. It is remarkably good for bone evaluation, with excellent bone/mucosa/air contrast, but its poor density resolution is a drawback for soft-tissue contrast studies. In case of tumoral, septic or hematic soft-tissue infiltration, MDCT or MRI is mandatory. In addition, although the imaging techniques play a fundamental role in the diagnosis of sinus anatomical variations and sinus pathology, clinical examination still represent a fundamental tool for the patient's diagnostic process.

Acknowledgements

The authors would like to thank the Coordination for the improvement of Higher Education Personnel (CAPES) by financial support. The authors deny any conflicts of interest related to this study.

REFERENCES

1. Fatterpekar GM, Delman BN, Som PM. Imaging the paranasal sinuses: Where we are and where we are going. *Anat Rec*. 2008;291(11):1564–72.
2. Ritter L, Lutz J, Neugebauer J, Scheer M, Dreiseidler T, Zinser MJ, et al. Prevalence of pathologic findings in the maxillary sinus in cone-beam computerized tomography. *Oral Surg Oral Med Oral Pathol Oral Radiol Endod*. 2011;111(5):634–40.
3. Cagici CA, Cakmak O, Hurcan C, Tercan F. Three-slice computerized tomography for the diagnosis and follow-up of rhinosinusitis. *Eur Arch Otorhinolaryngol*. 2005;262(9):744–50.
4. Cakli H, Cingi C, Ay Y, Oghan F, Ozer T, Kaya E. Use of cone beam computed tomography in otolaryngologic treatments. *Eur Arch Otorhinolaryngol*. 2012;269(3):711–20.
5. Poorey VK, Gupta N. Endoscopic and computed tomographic evaluation of influence of nasal septal deviation on lateral wall of nose and its relation to sinus diseases. *Indian J Otolaryngol Head Neck Surg*. 2014;66(3):330–5.
6. Agacayak KS, Gulsun B, Koparal M, Atalay Y, Aksoy O, Adiguzel O. Alterations in maxillary sinus volume among oral and nasal breathers. *Med Sci Monit*. 2015 Jan 2;21:18–26.
7. Liang X, Jacobs R, Hassan B, Li L, Pauwels R, Corpas L, et al. A comparative evaluation of cone beam computed tomography (CBCT) and multi-slice CT (MSCT) Part I. On subjective image quality. *Eur J Radiol*. 2010;75(2):265–9.
8. Güldner C, Diogo I, Windfuhr J, Bien S, Teymoortash A, Werner J a, et al. Analysis of the fossa olfactoria using cone beam tomography (CBT). *Acta Otolaryngol*. 2011;131(1):72–8.
9. Rafferty MA, Siewerdsen JH, Chan Y, Moseley DJ, Daly MJ, Jaffray DA, et al. Investigation of C-arm cone-beam CT-guided surgery of the frontal recess. *Laryngoscope*. 2005;115(12):2138–43.
10. Shahbazian M, Jacobs R. Diagnostic value of 2D and 3D imaging in odontogenic maxillary sinusitis: A review of literature. *J Oral Rehabil*. 2012;39(4):294–300.
11. Aramani A, Karadi RN, Kumar S. A study of anatomical variations of osteomeatal complex in chronic rhinosinusitis patients-CT findings. *J Clin Diagnostic Res*. 2014;8(10):KC01-KC04.

12. Zojaji R, Naghibzadeh M, Mazloun Farsi Baf M, Nekooei S, Bataghva B, Noorbakhsh S. Diagnostic accuracy of cone-beam computed tomography in the evaluation of chronic rhinosinusitis. *Orl J Otorhinolaryngol Relat Spec.* 2015;77(1):55–60.
13. Saccucci M, Carderi S, Carlo GDI, Polimeni A, Rodolfino D. Gender assessment through three-dimensional analysis of maxillary sinuses by means of Cone Beam Computed Tomography. *Eur Rev Med Pharmacol Sci.* 2015;185–93.
14. Demeslay J, Vergez S, Serrano E, Chaynes P, Cantet P, Chaput B, et al. Morphological concordance between CBCT and MDCT: a paranasal sinus-imaging anatomical study. *Surg Radiol Anat.* 2015;38(1):71-8.
15. Prisman E, Daly MJ, Chan H, Siewerdsen JH, Vescan A, Irish JC. Real-time tracking and virtual endoscopy in cone-beam CT-guided surgery of the sinuses and skull base in a cadaver model. *Int Forum Allergy Rhinol.* 2011;1(1):70–7.
16. Bui NL, Ong SH, Foong KWC. Automatic segmentation of the nasal cavity and paranasal sinuses from cone-beam CT images. *Int J Comput Assist Radiol Surg [Internet].* 2014;10(8):1269–77.
17. Scarfe WC, Farman AG. What is Cone-Beam CT and How Does it Work? *Dent Clin North Am.* 2008;52(4):707–30.
18. The 2007 Recommendations of the International Commission on Radiological Protection. ICRP publication 103. *Ann ICRP* 2007;37(2–4):1–332.
19. Durack C, Patel S. Cone beam computed tomography in endodontics. *Braz Dent J.* 2012;23(3):179–91.
20. Dahmani-Causse M, Marx M, Deguine O, Fraysse B, Lepage B, Escudé B. Morphologic examination of the temporal bone by cone beam computed tomography: Comparison with multislice helical computed tomography. *Eur Ann Otorhinolaryngol Head Neck Dis.* 2011;128(5):230–5.
21. Hodez C, Griffaton-Taillandier C, Bensimon I. Cone-beam imaging: Applications in ENT. *Eur Ann Otorhinolaryngol Head Neck Dis.* 2011;128(2):65–78.
22. Bremke M, Sesterhenn AM, Murthum T, Al Hail A, Bien S, Werner JA. Digital volume tomography (DVT) as a diagnostic modality of the anterior skull base. *Acta Otolaryngol.* 2009 Oct;129(10):1106–14.
23. Rege IC, Sousa T, Leles C, Mendonça E. Occurrence of maxillary sinus abnormalities detected by cone beam CT in asymptomatic patients. *BMC Oral Health.* 2012;12(1):30.

24. Queiroz PM, Oliveira ML, Groppo FC, Haiter-Neto F, Freitas DQ. Evaluation of metal artefact reduction in cone-beam computed tomography images of different dental materials. *Clin Oral Investig*. 2017 May 23; doi: 10.1007/s00784-017-2128-9. [Epub ahead of print]
25. Daly MJ, Siewerdsen JH, Moseley DJ, Jaffray DA, Irish JC. Intraoperative cone-beam CT for guidance of head and neck surgery: Assessment of dose and image quality using a C-arm prototype. *Med Phys*. 2006 Oct;33(10):3767–80.
26. Maillet M, Bowles WR, McClanahan SL, John MT, Ahmad M. Cone-beam computed tomography evaluation of maxillary sinusitis. *J Endod*. 2011;37(6):753–7.
27. Shahidi S, Zamiri B, Momeni Danaei S, Salehi S, Hamedani S. Evaluation of Anatomic Variations in Maxillary Sinus with the Aid of Cone Beam Computed Tomography (CBCT) in a Population in South of Iran. *J Dent (Shiraz, Iran)*. 2016 Mar;17(1):7–15.
28. Orhan K, Kusakci Seker B, Aksoy S, Bayindir H, Berberoğlu A, Seker E. Cone beam CT evaluation of maxillary sinus septa prevalence, height, location and morphology in children and an adult population. *Med Princ Pract*. 2013;22(1):47–53.
29. Oz AZ, Oz AA, El H, Palomo JM. Maxillary sinus volume in patients with impacted canines. *Angle Orthod*. 2017 Jan;87(1):25–32.
30. Choi IGG, Duailibi-Neto EF, Beaini TL, da Silva RLB, Chilvarquer I. The Frontal Sinus Cavity Exhibits Sexual Dimorphism in 3D Cone-beam CT Images and can be Used for Sex Determination. *J Forensic Sci*. 2017;(11):1–7.

FIGURES

Figure 1 - (A) Coronal, (B) Axial, (C) Sagittal and (D) Parasagittal planes

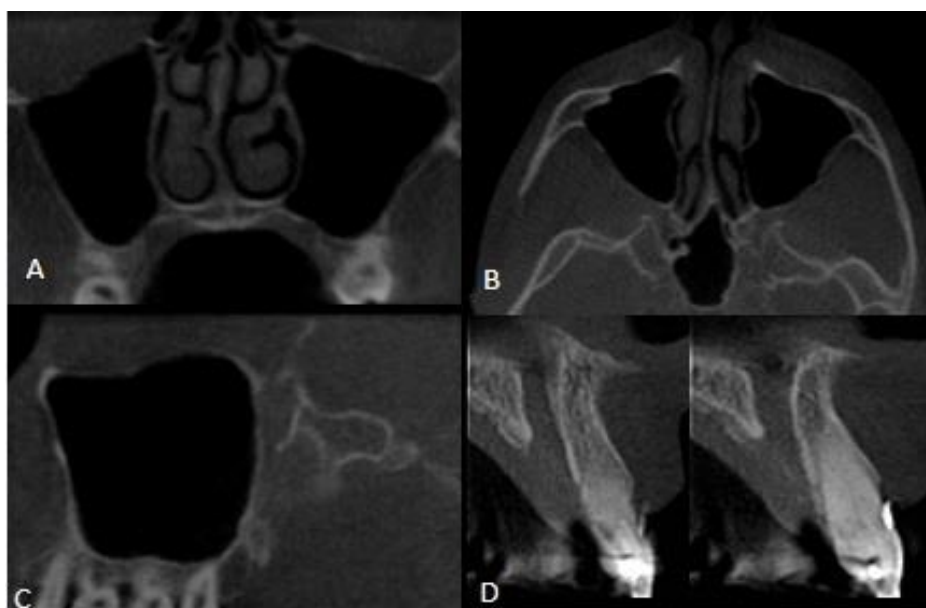


Figure 2 - Periapical inflammation

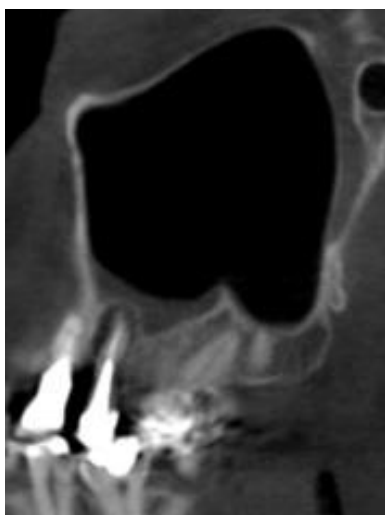


Figure 3 – Relationship between dental implant and sinus floor.

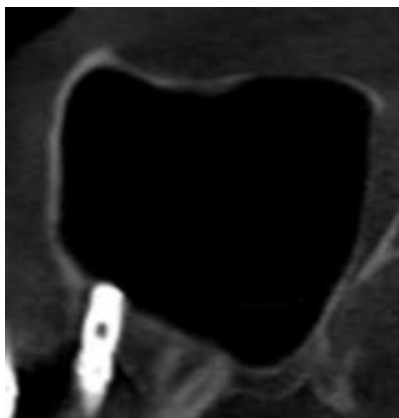
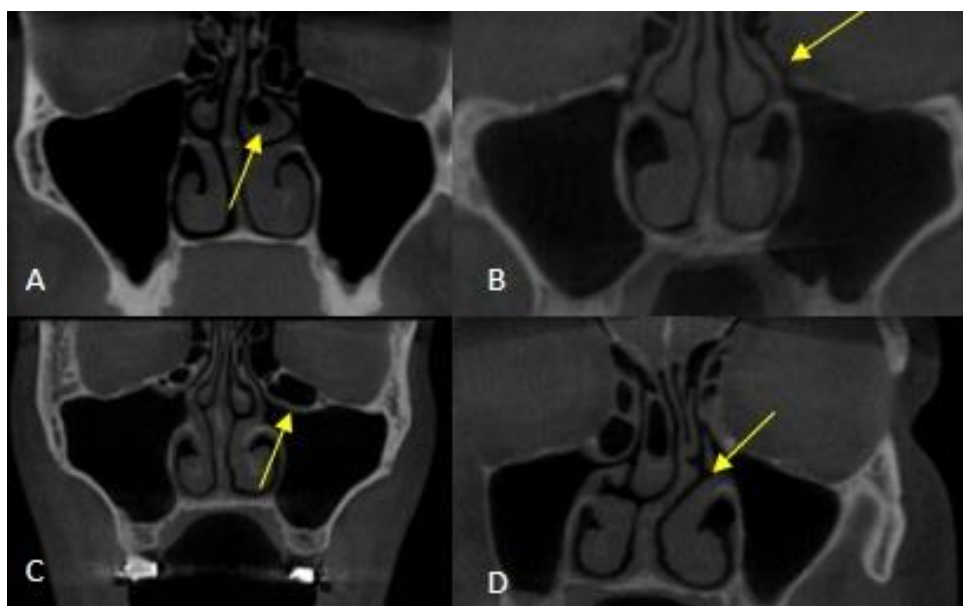

Figure 4 - (A) Concha bullosa, (B) Hipertrophy of the uncinate process, (C) Haller Cell, (D) Nasal septum deviation



2.2 ARTIGO – Relation of linear and volumetric measurements of nasal structures with and without sinus mucosal changes

*Este artigo foi submetido ao periódico Dentomaxillofacial Radiology (Anexo 1)

Abstract

Objective: Correlate the linear, angular and volumetric measurements of nasal structures with sinus maxillary mucosal changes and evaluate the influence of sex on study variables.

Methods: 240 cone beam computed tomography (CBCT) images were used and divided into two groups: without sinus change (60 men and 60 women) and with sinus change (60 men and 60 women). The images were selected from a dental database. Two radiologist observers evaluated septum deviation, ostium diameters, ethmoidal infundibulum volume and mucosa conditions. The linear and volumetric measurements were done using the software OnDemand3D™ (Cybermed, Tustin, CA) and ITK-SNAP (Cognitica, Philadelphia, Pa, EUA), respectively. The data was statistically analyzed; Kruskal-Wallis test was used to verify the existence of a relationship between the absence/presence of sinus changes and other variables analyzed in the study. Mann-Whitney test was used to analyze the influence of sex on the variables.

Results: The presence of septal deviation was not a contributing factor for the presence of sinus change. The presence or absence of sinus change did not influence the anteroposterior ostium diameter, but latero-lateral ostium diameter was smaller in the presence of thickening and polyp. The ethmoidal infundibulum volume did not show differences in the presence/absence of sinus change.

Conclusions: We can conclude that patients with mucosal thickening and polyp in maxillary sinuses can present reduced latero-lateral ostium diameters. Maxillary sinus changes do not affect the volume of the infundibulum and are not related with septal deviation. There were no statistically significant differences for the variables between sexes. CBCT generates images with great anatomical details and may be an interesting option on the analysis of ostiomeatal complex.

Keywords: Maxillary Sinus, Maxillary Sinusitis, Cone-Beam Computed Tomography.

Introduction

The maxillary sinuses are the largest paranasal sinuses in the facial skeleton, which are located in the main part of the maxilla. They are the first to develop, beginning their formation at the third week of gestation and continuing through puberty.^{1,2} The maxillary sinuses consist of two spaces occupied with air and lined with pseudostratified ciliated columnar epithelium.^{3,4} They show many functions, such as the decrease of the skull's weight, increase in voice resonance, protection against trauma, contribution to the heating and humidification of inhaled air^{5,6} and support in the secretion of mucus. For the appropriate execution of this last function, there should be a balance between mucus production and the movement of mucociliary cells in conducting it out of the paranasal sinuses.^{7,8}

One of the main channels of drainage of the maxillary sinus is the ostiomeatal unit, which is formed by the ostium that is located in the medial wall of the maxillary sinus and drains the mucus secreted by mucociliary cells into the ethmoid infundibulum.⁹ The ostium/infundibulum obstruction or damage to the function of the mucociliary cells could lead to mucous retention and the development of sinusitis^{10,11} which in the maxillary sinus is defined as mucosal thickening greater than 3 mm.^{2,5,12} Anatomical variations present in the nasal cavity may constitute obstructive factors to the ostiomeatal complex, such as deviated nasal septum.¹³ That occurs when the nasal septum is displaced toward one side of the nasal cavity, which may cause the compression of the ipsilateral middle nasal concha and ethmoid infundibulum.^{9,14}

Image methods, such as Virtual Endoscopy (VE), Bidimensional Radiographs (BR), Magnetic Resonance Imaging (MRI), Computed Tomography (CT) and Cone Beam Computed Tomography (CBCT) are powerful tools to help clinicians on diagnosis of certain sinus conditions.¹⁵⁻¹⁸ They provide an accurate view of regional anatomy, anatomical variations, presence of diseases and appearance of sinus mucosa.^{19,20} Offering the advantage of lower radiation dose over CT, CBCT has been used for the diagnostic imaging of the head and neck region and the ear, nose, and throat area, mucosal thickness, nasal septum deviation, conchal hypertrophy, bullous concha, and retention cysts in these areas.^{18,21,22} Moreover, CBCT technology allows the segmentation and visualization 3D models of hollow structures.^{23,24} It allows clinicians to assess surrounding structures and morphological features of anatomical regions.

Thus, the aim of this study was to correlate the linear, angular and volumetric measurements of nasal structures with sinus maxillary mucosal changes and evaluate the influence of sex on study variables.

Methods and Materials

The local Research Ethics Committee approved this study and a retrospective analysis was performed from a dental database from patient's images performed from 2009 to 2015. Subjects were excluded if they were younger than 18 years, had nasal septum destruction, maxillary sinus with severe pathology (tumor) or trauma, or the images did not allow full visualization of the corresponding maxillary sinus, ostium and ethmoidal infundibulum.

The principal researcher included 240 CBCT images into the following groups: group without sinus change (60 male and 60 female) and group with sinus change (60 male and 60 female). Their ages ranged from 18 to 82 years (34.7 ± 15.7). No information about race was available. The sinus change was considered when the patient image showed a mucosal thickening greater than 5 mm.^{11,25,26} All CBCT scans were acquired by i-CAT® 3D Imaging System (Imaging Sciences International, Hatfield, PA, USA). The device was operated at 7 mA; 120 kVp; 200 μ m voxel size; 40 s of acquisition time and 23 x 17 cm field of view (FOV). The CBCT scans were done for reasons not related to the present study.

Evaluation of CBCT images

Two observers experienced in oral radiology, previously trained and experienced in tomographic images, evaluated, in a quiet, windowless room with dimmed lighting in a 24.1inch LCD monitor (MDRC-2124, Barco N.V., Courtray, Belgium) with resolution of 1920 x 1200 pixels, the following: septum deviation, maxillary ostium diameters, ethmoidal infundibulum volume and mucosa conditions. The septal deviation was determined by measuring the septal deviation angles in coronal reconstructions, which was obtained with a line drawn from the crista galli to the maxillary spine and another line from the crista galli to the apex of the septal deviation (Figure 1). The angulation should be classified as without deviation (0°), mild ($<9^\circ$), moderate ($9^\circ \leq 15^\circ$), or severe ($>15^\circ$).^{5,12,27} To measure the diameter of the ostium, first the ostium was localized using lines of orientation: in the coronal reconstruction, a line was drawn along the axis of the ethmoidal infundibulum and

another perpendicular to the ostium. Thus, it was possible to locate, delimit and measure the maximum and minimum ostium diameters at axial reconstruction, corrected according to the long axis of the infundibulum. The sinus condition was classified as mucosal thickening, polypoidal mucosal thickening, partial opacification and total opacification (Figure 2). The measurements of the septal deviation, ostium diameters and sinus mucosa conditions were done using the software OnDemand3D™ (Cybermed, Tustin, CA).

Volume segmentation of the ethmoidal infundibulum was performed using the software ITK-SNAP (Cognitica, Philadelphia, Pa, EUA). The reconstruction of the 3D model was performed using the manual segmentation following the contour of the ethmoidal infundibulum from the point of greatest constriction at the infundibulum entrance to the visible limits of the structure, when it communicates with the ostiomeatal complex (Figure 3). After segmentation, the volume image of the ethmoidal infundibulum was reconstructed in the 3D window of the software and measured in mm³ (Figure 4).

Statistical Analysis

Kappa test was used for evaluation the inter - rater agreement regarding to: septal deviation classification and sinus mucosa condition. Intraclass Correlation Coefficient (ICC) was used to analysis the ostium diameters, septal deviation and ethmoidal infundibulum volume. The data were also submitted to statistical analysis in which Mann – Whitney test was used to analyze the influence of sex on the variables. The Kruskal – Wallis test was applied to verify the existence of a relation between absence/presence of sinus mucosal changes and variables. The significance level considered was 5% for all tests and the software used was BioEstat 5.0 and GraphPad Prism 7.0.

Results

The inter-rater agreement analyzed by Kappa test was greater than 0.8. The kappa coefficient for septal deviation classification and sinus mucosa condition were 0.94 and 0.90, respectively. The anteroposterior and latero-lateral ostium diameters and ethmoidal infundibulum volume were evaluated by the Intraclass Correlation Coefficient (ICC), whose values were 0.99, 0.95 and 0.99, respectively.

There were no statistically significant differences between sexes or groups

within the septal deviation ($p=0.43$), anteroposterior ostium diameter ($p=0.27$) and ethmoidal infundibulum volume ($p=0.89$). However, in group without sinus change, there were statistically significant differences between sexes and groups ($p=0.038$); the latero-lateral diameter were larger in women without sinus change than in woman with sinus change and men with or without sinus change (Figure 5).

The median nasal septal deviation angles were 6.7° (5.1° to 8.3° interquartile range) in the group without sinus change and median of 6.6° (5.3° and 9.3° interquartile range) in the group with sinus change. Within the 240 analyzed CBCT images, 28 (11.7%) presented “no deviation” (0°), 156 (65%) presented “mild” deviation ($<9^\circ$), 50 (20.8%) “moderate” deviation ($9^\circ \leq 15^\circ$) and 6 (2.5%) showed a “severe” septal deviation ($>15^\circ$).

The measurements of septal deviation, ostium diameters (anteroposterior and latero-lateral) and ethmoidal infundibulum volume, considering the sinus mucosa condition, are presented in Table 1. The “thickening” of the sinus mucosa was the most common change (93 patients). “Polypoidal” and “opacification” were present in 28 and 26 images, respectively. The latero-lateral ostium diameters were significantly smaller in patients presenting a maxillary sinus with “thickening” and/or “polypoidal” ($p=0.0136$).

Discussion

In the present study, CBCT revealed anatomic details of the ostiomeatal complex and may be applied as an alternative method on the analysis of these structures. Moreover, mucosal thickening and polyp in maxillary sinus are related to reduced ostium sizes.

In agreement with other studies,^{10,28,29} the presence of septal deviation was not related to the sex of individuals. Only a few studies in the literature have found this correlation.^{30,31} Differences in the applied method may explain these findings. Ahn et al. (2016) evaluated the presence or absence of septal deviation by nasal endoscopy and observed higher prevalence in men. Mladina et al. (2008) evaluated the morphology of deviated septa and noticed that some types of deviation are more frequent in men and others in women. In the present study, the morphological type of deviation was not taken into consideration, CBCT was used to measure the angulation of deviated septa. Women presented larger latero-lateral ostium diameter in the absence of disease, however, no difference was observed in the presence sinus

mucosal changes. Although no other study have correlated the sex with the diameter of maxillary sinus ostium, no differences were found in the diameter of ostiums from other paranasal sinus, such as the sphenoidal sinus ostium³² and the frontal sinus ostium.³³

The radiological definition of sinusitis is still controversial. According to Smith et al. (2010), the sinus mucosa, under normal conditions, should not be evident in image exams and any sign of thickening should be considered pathological. On the other hand, some authors believe that certain mucosal thicknesses are considered normal.^{2,5,11,26,34} Rak et al. (1990) reported that the thickness of sinus mucosa in asymptomatic patients may present up to 3 mm. Despite all the divergent opinions regarding the radiological definition of sinusitis, we believe that a profuse knowledge of the sinus changes and their image presentation are essential requirements to achieve an accurate diagnosis and to plan an appropriate treatment. In the present study, sinus changes were considered when mucosal thickness was greater than 5 mm. The followed criteria was established by Carmelli et al. (2011) and Shanbhag et al. (2013), who claimed that patients with mucosal thickness greater than 5 mm are more likely to develop sinusitis.

In symptomatic patients, the presence of mucosal changes is imperative, but it may not cause any morbidity in asymptomatic patients.³⁵ Similar to other studies,^{17,20,26} the majority of patients presented mucosal thickening. Polypoid can be categorized as antral pseudocysts (the accumulation of exudate at the sinus floor between bone and periosteum), mucosal retention pseudocyst (the accumulation of mucin in a blocked duct around the ostium), mucocele (the accumulation of mucus that causes expansion and resorption of bone walls; rare).³⁶ In the present study, all mucosal polyp types were categorized as a single pathological entity and was the second most frequent mucosal sinus change. Opacification was the less frequent sinus change found. Although its presence may be associated to sinusitis,¹¹ it also can be related to other conditions, such as mechanical trauma, barotruma and hemorrhage.³⁷

It is still unclear if maxillary chronic sinusitis is a primary condition or the result of a process in which the narrowing of the ostia is involved. Differently from some studies,^{38,39} that evaluated the diameter of ostium and did not find any correlation with maxillary sinusitis, the latero-lateral ostium diameter was significantly smaller in the presence of mucosa thickening and polyp. This difference might be explained by the measurement method. In the studies of Mathew et al. (2013) and Khojastepour et al.

(2016), to find the ostium diameters, the authors used a coronal reconstruction, wherein the distance of the Haller cell, in its most medial portion to the uncinated process, was measured. However, in order to measure the ostium diameters it is necessary to visualize it completely. Thus, in the present study, to measure the diameter of the ostium, first the ostium was localized using lines of orientation: still in the coronal reconstruction, a line was drawn along the axis of the ethmoidal infundibulum and another perpendicular to the ostium. Therefore, it was possible to locate, delimit and measure the maximum and minimum ostium diameters at axial reconstruction.

Septal deviation showed no relation with sinus change. This corroborates with the results presented by Smith et al. (2010). However, other studies, evaluating the angle of the septal deviation, affirm that patients with moderate to severe septum deviation are more likely to develop sinus changes.^{5,12,40-42} It is possible that this relationship could not be observed in the present study due to characteristic of the sample, composed, in its majority, by patients with mild deviation (65%).

Chronic sinusitis is a significant health problem that affects thousands of people worldwide.^{43,44} The assessment of paranasal sinuses by endoscopy allows the observation of anatomical areas and the evaluation of sinus lesions and their relationship with endonasal structures. However, diagnostic sinus endoscopy is an invasive and costly method that needs local or general anesthesia.^{21,45} CBCT exposes the patient to substantially lower radiation compared with standard CT and, although MRI is still superior in soft tissue rendering, its use is limited by its cost and restricted accessibility.^{22,46} CBCT is useful to assess the diagnosis of mucosal thickness, nasal septum deviation, conchal hypertrophy, bullous concha, and retention cysts in these areas,^{18,21,47} presenting high agreement with sinus endoscopy.^{21,48} In the present study, it was possible to measure maxillary ostia diameters in CBCT images, supporting its use as an evaluation method before surgery.

The software ITK-SNAP⁴⁹ allows the semi-automatic and manual segmentation of structures, the analysis of shape, size and volume. In the present study, the manual segmentation was used to follow the contour of the ethmoidal infundibulum and to assess its volume. However, we did not find any statistical difference between the presence and absence of sinus change regarding the ethmoidal infundibulum volume. This was the first study to use segmentation to assess these measurements.

The present study highlights the potential use of CBCT for the assessment of nasal/paranasal structures and provides evidence that CBCT is an accurate and reliable imaging method for this purpose. The combination of image quality, low exposure dose, short scanning time, easy application and reduced costs when compared to CT and MRI can make CBCT the method of choice among professionals in the routine evaluation of maxillary sinuses. However, it is important to bear in mind that the interpretation of CBCT images requires familiarity with the anatomy of the investigated area, spatial relations of 3D images, knowledge of anatomical variations and maxillofacial pathologies as well as competence in the formulation of a differential diagnosis.

In conclusion, according to the population studied in the present study, patients with mucosal thickening and polyp in maxillary sinuses can present reduced latero-lateral ostium diameters. Maxillary sinus changes do not affect the volume of the infundibulum and are not related with septal deviation. There were no statistically significant differences for the variables between sexes. CBCT generates images with great anatomical details and may be an interesting option on the analysis of ostiomeatal complex.

References

1. Göçmen G, Borahan MO, Aktop S, Dumlu A, Pekiner FN, Göker K. Effect of Septal Deviation, Concha Bullosa and Haller's Cell on Maxillary Sinus's Inferior Pneumatization; a Retrospective Study. *Open Dent J.* 2015;9:282–6.
2. Kucybała I, Janik KA, Ciuk S, Storman D, Urbanik A. Nasal septal deviation and concha bullosa - Do they have an impact on maxillary sinus volumes and prevalence of maxillary sinusitis? *Polish J Radiol.* 2017;82:126–33.
3. Masri AA, Yusof A, Hassan R. A Three Dimensional Computed Tomography (3D-CT): A Study of Maxillary Sinus in Malays. *Can J Basic Appl Sci.* 2013;1(2):125–34.
4. Kiruba L, Gupta C, Sandeep K, D'Souza AS. A study of morphometric evaluation of the maxillary sinuses in normal subjects using computer tomography images. *Arch Med Heal Sci.* 2014;2(1):12.
5. Karataş D, Koç A, Yüksel F, Doğan M, Bayram A, Cihan MC. The Effect of Nasal Septal Deviation on Frontal and Maxillary Sinus Volumes and Development of Sinusitis. *J Craniofac Surg.* 2015;26(5):1508–12.
6. Rani SU, Rao GV, Kumar DR, Sravya T, Sivaranjani Y, Kumar MP. Age and gender assessment through three-dimensional morphometric analysis of maxillary sinus using magnetic resonance imaging. *J Forensic Dent Sci.* 2017;9(1):46.
7. Toskala E, Rautiainen M. Effects of surgery on the function of maxillary sinus mucosa. *Eur Arch Oto-Rhino-Laryngology.* 2005;262(3):236–40.
8. Bandyopadhyay R, Biswas R, Bhattacharjee S, Pandit N, Ghosh S. Osteomeatal Complex: A Study of Its Anatomical Variation Among Patients Attending North Bengal Medical College and Hospital. *Indian J Otolaryngol Head Neck Surg.* 2015;67(3):281–6.
9. Parks ET. Cone beam computed tomography for the nasal cavity and paranasal sinuses. *Dent Clin North Am.* 2014;58(3):627–51.
10. Smith KD, Edwards PC, Saini TS, Norton NS. The prevalence of concha bullosa and nasal septal deviation and their relationship to maxillary sinusitis by volumetric tomography. *Int J Dent.* 2010;2010:0–4.
11. Carmeli G, Artzi Z, Kozlovsky A, Segev Y, Landsberg R. Antral computerized tomography pre-operative evaluation: Relationship between mucosal thickening

- and maxillary sinus function. *Clin Oral Implants Res.* 2011;22(1):78–82.
12. Kapusuz Gencer Z, Ozkırış M, Okur A, Karaçavuş S, Saydam L. The effect of nasal septal deviation on maxillary sinus volumes and development of maxillary sinusitis. *Eur Arch Otorhinolaryngol.* 2013;270(12):3069–73.
 13. Lee JW, Yoo JY, Paek SJ, Park W-J, Choi EJ, Choi M-G, et al. Correlations between anatomic variations of maxillary sinus ostium and postoperative complication after sinus lifting. *J Korean Assoc Oral Maxillofac Surg.* 2016;42(5):278–83.
 14. Rao VM, el-Noueam KI. Sinonasal imaging: Anatomy and pathology. *Radiol Clin North Am.* 1998;36(5):921–39.
 15. Eggesbø HB. Radiological imaging of inflammatory lesions in the nasal cavity and paranasal sinuses. *Eur Radiol.* 2006;16(4):872–88.
 16. Campbell PD, Zinreich SJ, Aygun N. Imaging of the paranasal sinuses and in-office CT. *Otolaryngol Clin North Am [Internet].* 2009;42(5):753–64.
 17. Vallo J, Suominen-Taipale L, Huuonen S, Soikkonen K, Norblad A. Prevalence of mucosal abnormalities of the maxillary sinus and their relationship to dental disease in panoramic radiography: results from the Health 2000 Health Examination Survey. *Oral Surg, Oral Med Oral Pathol Oral Radiol Endod.* 2010;109(3):e80–7.
 18. Demeslay J, Vergez S, Serrano E, Chaynes P, Cantet P, Chaput B, et al. Morphological concordance between CBCT and MDCT: a paranasal sinus-imaging anatomical study. *Surg Radiol Anat.* 2015;38(1).
 19. Fatterpekar GM, Delman BN, Som PM. Imaging the paranasal sinuses: Where we are and where we are going. *Anat Rec.* 2008;291(11):1564–72.
 20. Ritter L, Lutz J, Neugebauer J, Scheer M, Dreiseidler T, Zinser MJ, et al. Prevalence of pathologic findings in the maxillary sinus in cone-beam computerized tomography. *Oral Surg Oral Med Oral Pathol Oral Radiol Endod.* 2011;111(5):634–40.
 21. Zojaji R, Naghibzadeh M, Mazloun Farsi Baf M, Nekoei S, Bataghva B, Noorbakhsh S. Diagnostic accuracy of cone-beam computed tomography in the evaluation of chronic rhinosinusitis. *Orl J Otorhinolaryngol Relat Spec.* 2015;77(1):55–60.
 22. Saccucci M, Carderi S, Carlo GDI, Polimeni A, Rodolfo D. Gender assessment through three-dimensional analysis of maxillary sinuses by means of Cone Beam

- Computed Tomography. *Eur Rev Med Pharmacol Sci.* 2015;185–93.
23. Bui NL, Ong SH, Foong KWC. Automatic segmentation of the nasal cavity and paranasal sinuses from cone-beam CT images. *Int J Comput Assist Radiol Surg.* 2014;10(8):1269–77.
 24. Codari M, Zago M, Guidugli GA, Pucciarelli V, Tartaglia GM, Ottaviani F, et al. The nasal septum deviation index (NSDI) based on CBCT data. *Dentomaxillofacial Radiol.* 2016;45: 20150327.
 25. Maillet M, Bowles WR, McClanahan SL, John MT, Ahmad M. Cone-beam computed tomography evaluation of maxillary sinusitis. *J Endod.* 2011;37(6):753–7.
 26. Shanbhag S, Karnik P, Shirke P, Shanbhag V. Cone-beam computed tomographic analysis of sinus membrane thickness, ostium patency, and residual ridge heights in the posterior maxilla: Implications for sinus floor elevation. *Clin Oral Implants Res.* 2014;25(6):755–60.
 27. Orhan I, Ormeci T, Aydin S, Altin G, Urger E, Soylyu E, et al. Morphometric analysis of the maxillary sinus in patients with nasal septum deviation. *Eur Arch Oto-Rhino-Laryngology.* 2014;271(4):727–32.
 28. Serifoglu I, Oz İl, Damar M, Buyukuysal MC, Tosun A, Tokgöz Ö. Relationship between the degree and direction of nasal septum deviation and nasal bone morphology. *Head Face Med.* 2017 28;13(1):3.
 29. Šubarić M, Mladina R. Nasal septum deformities in children and adolescents: A cross sectional study of children from Zagreb, Croatia. *Int J Pediatr Otorhinolaryngol.* 2002;63(1):41–8.
 30. Mladina R, Čujčić E, Šubarić M, Vuković K. Nasal septal deformities in ear, nose, and throat patients. An international study. *Am J Otolaryngol - Head Neck Med Surg.* 2008;29(2):75–82.
 31. Ahn J-C, Kim J-W, Lee CH, Rhee C-S. Prevalence and Risk Factors of Chronic Rhinosinusitis, Allergic Rhinitis, and Nasal Septal Deviation: Results of the Korean National Health and Nutrition Survey 2008-2012. *JAMA Otolaryngol Head Neck Surg.* 2016;142(2):162–7.
 32. Göçmez C, Göya C, Hamidi C, Teke M, Hattapoğlu S, Kamaşak K. Evaluation of the surgical anatomy of sphenoid ostium with 3D computed tomography. *Surg Radiol Anat.* 2014;36(8):783–8.
 33. Angélico Junior FV, Rapoport PB. Analysis of the Agger nasi cell and frontal

- sinus ostium sizes using computed tomography of the paranasal sinuses. *Braz J Otorhinolaryngol.* 2013;79(3):285–92.
34. Rak KM, Newell JD, Yakes WF, Damiano MA, Luethke JM. Paranasal sinuses on MR images of the brain: Significance of mucosal thickening. *Am J Roentgenol.* 1991;156(2):381–4.
 35. Ata-Ali J, Diago-Vilalta JV, Melo M, Bagán L, Soldini MC, Di-Nardo C, et al. What is the frequency of anatomical variations and pathological findings in maxillary sinuses among patients subjected to maxillofacial cone beam computed tomography? A systematic review. *Med Oral Patol Oral Cir Bucal.* 2017;22(4):e400–9.
 36. Chan H-L, Wang H-L. Sinus pathology and anatomy in relation to complications in lateral window sinus augmentation. *Implant Dent.* 2011;20(6):406–12.
 37. Rege IC, Sousa T, Leles C, Mendonça E. Occurrence of maxillary sinus abnormalities detected by cone beam CT in asymptomatic patients. *BMC Oral Health.* 2012;12(1):30.
 38. Mathew R, Omami G, Hand A, Fellows D, Lurie A. Cone beam CT analysis of Haller cells: Prevalence and clinical significance. *Dentomaxillofacial Radiol.* 2013;42(9).
 39. Khojastepour L, Haghnegahdar A, Khosravifard N. Role of Sinonasal Anatomic Variations in the Development of Maxillary Sinusitis: A Cone Beam CT Analysis. *Open Dent J.* 2017;11(Suppl-1, M5):367–74.
 40. Yasan H, Doğru H, Baykal B, Döner F, Tüz M. What is the relationship between chronic sinus disease and isolated nasal septal deviation? *Otolaryngol - Head Neck Surg.* 2005;133(2):190–3.
 41. Poorey VK, Gupta N. Endoscopic and computed tomographic evaluation of influence of nasal septal deviation on lateral wall of nose and its relation to sinus diseases. *Indian J Otolaryngol Head Neck Surg.* 2014;66(3):330–5.
 42. Mundra RK, Gupta Y, Sinha R, Gupta A. CT Scan Study of Influence of Septal Angle Deviation on Lateral Nasal Wall in Patients of Chronic Rhinosinusitis. *Indian J Otolaryngol Head Neck Surg.* 2014;66(2):187–90.
 43. Gündoğdu E, Haksever M, Akduman D, Solmaz F. A cost-effective way of maxillary sinus ostium dilatation with Foley catheter in patients with chronic rhinosinusitis: MOD-F technique. *Int Forum Allergy Rhinol.* 2014;4(5):428–32.
 44. Pilan RR, Pinna FR, Bezerra TF, Mori RL, Padua FG, Bento RF, et al.

- Prevalence of chronic rhinosinusitis in Sao Paulo. *Rhinology*. 2012 50(2):129–38.
45. Hathorn I, Habib AR, Santos RD, Javer A. The safety and performance of a maxillary sinus ostium self-dilation device: A pilot study. *Int Forum Allergy Rhinol*. 2014;4(8):625–31.
 46. Guijarro-Martínez R, Swennen GRJ. Cone-beam computerized tomography imaging and analysis of the upper airway: A systematic review of the literature. *Int J Oral Maxillofac Surg*. 2011;40(11):1227–37.
 47. Nascimento EH, Pontual ML, Pontual AA, Freitas DQ, Perez DE, Ramos-Perez FM. Association between Odontogenic Conditions and Maxillary Sinus Disease: A Study Using Cone-beam Computed Tomography. *J Endod*. 2016;42(10):1509–15.
 48. Prisman E, Daly MJ, Chan H, Siewerdsen JH, Vescan A, Irish JC. Real-time tracking and virtual endoscopy in cone-beam CT-guided surgery of the sinuses and skull base in a cadaver model. *Int Forum Allergy Rhinol*. 2011;1(1):70–7.
 49. Yushkevich P a., Piven J, Hazlett HC, Smith RG, Ho S, Gee JC, et al. User-guided 3D active contour segmentation of anatomical structures: Significantly improved efficiency and reliability. *Neuroimage*. 2006;31(3):1116–28.

TABLES AND FIGURES

Figure 1 - Measurement of the septal deviation angle

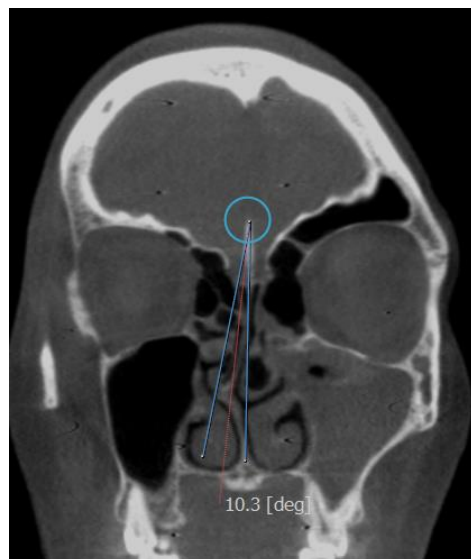


Figure 2 - Classification sinus mucosa condition: A - mucosal thickening, B - polypoidal mucosal, C - partial opacification and D - total opacification.

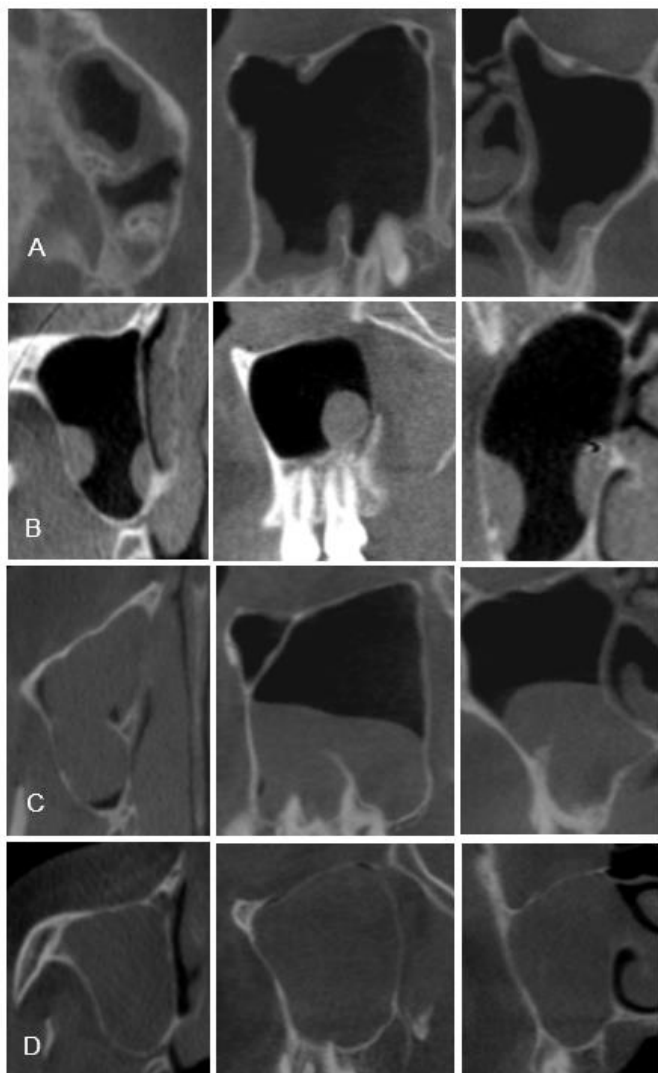

Figure 3- Manual segmentation of ethmoidal infundibulum volume

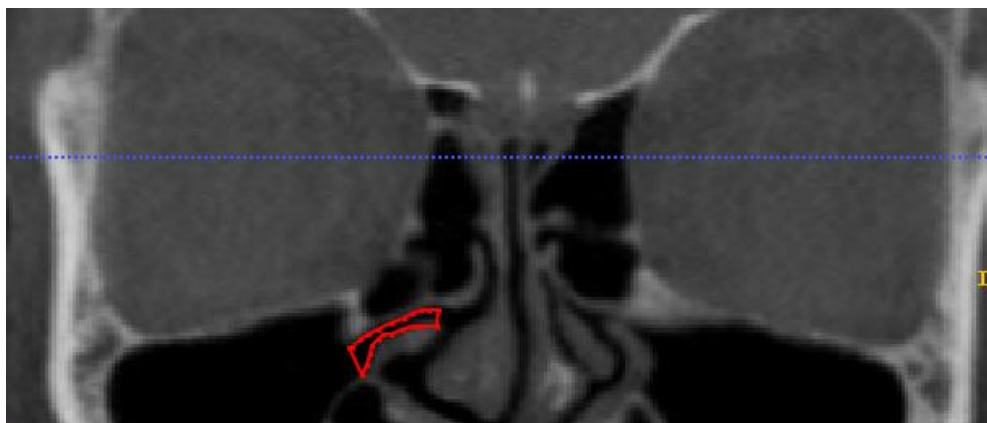


Figure 4 – 3D model of the ethmoidal infundibulum




Figure 5 - Measurements of septal deviations, ethmoidal infundibulum volume and ostium diameters as a function of sex. (Note: Median – horizontal line; 1st and 3rd quartiles – edges of the boxes; maximum and minimum values – extent of whiskers).

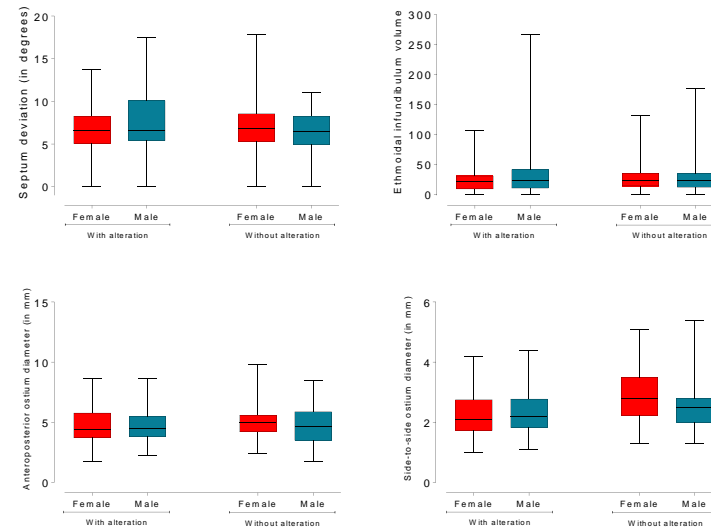


Table 1 – Measurements considering the sinus mucosa condition (Note: N = number of patients; data are presented as median (interquartile range)).

Measurements	Thickening N=69	Without sinus change N=120	Polypoidal N=12	Opacification N=12	Thickening and Polypoidal N=13	Thickening and Opacification N=11	Polypoidal and opacification N=3	p value
Septal Deviation (°)	6.6 (5.0 - 9.2)	6.7 (5.1 - 8.3)	7.15 (5.7 - 8.0)	7.95 (5.9 - 12.5)	5.5 (4.4 - 9.1)	6.4 (5.9 - 8.4)	10.8 (0 - 10.8)	0.56
Anteroposterior ostium diameter (mm)	4.4 (3.8 - 5.6)	4.8 (4.0 - 5.7)	5.05 (3.2 - 5.8)	4.4 (3.8 - 4.8)	4.6 (4.1 - 6.0)	4.4 (3.5 - 4.5)	3.1 (3.1 - 6.0)	0.36
Latero-lateral ostium diameter (mm)	2.1 ^b (1.8 - 2.8)	2.6 ^a (2.1 - 3.3)	2.1 ^b (1.8 - 2.5)	2.2 ^{ab} (2.0 - 2.9)	2.1 ^b (1.9 - 2.4)	2.3 ^{ab} (1.5 - 2.9)	2.6 ^{ab} (1.6 - 2.8)	0.0136
Ethmoidal infundibulum volume (mm ³)	22.98 (10.8 - 38.6)	23.46 (13.4 - 35.8)	23.76 (11.6 - 41.4)	11.78 (8.1 - 27.6)	19.23 (10.5 - 32.8)	14.74 (7.5 - 21.8)	14.16 (10 - 23)	0.10

Lowercase letters represent statistically significant differences between sinus mucosa condition.

3 DISCUSSÃO

A presente tese apresenta dois estudos em paralelo, em que o primeiro foi organizado na forma de um artigo de revisão de literatura e o segundo um estudo observacional. Os objetivos foram expor uma atualização, principalmente para os cirurgiões-dentistas, das vantagens, limitações e indicações sobre o uso da TCFC para avaliação dos seios paranasais e relacionar mensurações lineares, angulares e volumétricas de estruturas nasais com alterações muco sinusais dos seios maxilares. A Radiologia Odontológica passa por renovações constantes e o avanço contínuo é necessário para o conhecimento de novas modalidades de imagem, suas ferramentas e aplicações. Na odontologia, a TCFC já é comumente usada para vários propósitos, como planejamentos para levantamento de seio maxilar e implantes, cirurgias orais e avaliação da articulação têmporo-mandibular, ortodôntica e crânio-facial (Liang et al., 2010; Ritter et al., 2011; Zojaji et al., 2015). A TCFC vem ganhando popularidade também na área médica, ampliando seu uso na avaliação de regiões de ouvido, nariz e garganta, para o diagnóstico de patologias como espessamento mucoso nos seios da face, cistos de retenção e hipertrofia de conchas nasais, e de variações anatômicas como desvio de septo e conchas bulhosas (Rao e el-Noueam, 1998; Kapusuz Gencer et al., 2013; Kucybała et al., 2017).

A literatura tem demonstrado que a TCFC é uma ferramenta precisa e confiável, com potencial para se tornar o padrão ouro na rotina da exploração sinusal. Contudo, outros métodos por imagem estão disponíveis: a endoscopia sinusal, radiografias bidimensionais, TC e IRM (Eggesbø, 2006; Campbell et al., 2009; Vallo et al., 2010; Demeslay et al., 2015). A endoscopia sinusal permite a observação da anatomia e de condições patológicas, assim como a relação destas, com estruturas endonasais. Porém, é um método invasivo e dispendioso, com necessidade de anestesia local ou geral, podendo estar associada com algumas complicações cirúrgicas como sangramentos intraoperatórios, danos na lâmina papirácea e estruturas periorbitais (Hosemann e Draf, 2013; Zojaji et al., 2015). A TCFC pode ser usada para auxiliar o profissional previamente a cirurgias endoscópicas, pela possibilidade de gerar reformatações multiplanares das imagens, que possibilita a correlação da anatomia do paciente observada na etapa pré-operatória com a observada no trans-operatório. Isso reduz o risco de intercorrências, principalmente

em áreas próximas a estruturas vitais e em pacientes portadores de variações anatômicas (Rafferty et al., 2005; Daly et al., 2006; Bremke et al., 2009).

Por muitos anos, as radiografias bidimensionais de crânio como a pósterio-antérieures (Caldwel e Waters) e lateral, foram utilizadas para avaliação dos seios paranasais (Shahidi et al., 2016). Nelas, é possível avaliar a morfologia regional, caracterizar a localização e extensão de condições patológicas e de variações anatômicas. No entanto, radiografias bidimensionais são difíceis de serem interpretadas devido à sobreposição das imagens, principalmente das estruturas ósseas (Liang et al., 2010). De fato, na maioria das vezes em que se observa alguma alteração dos seios paranasais em radiografias bidimensionais, a indicação de exames mais avançados é recomendada (Fatterpekar et al., 2008).

A IRM é ideal para avaliar tecido mole, mucosa e condições patológicas malignas que se estendem para além dos seios paranasais. Além disso, o uso de radiações não ionizantes é também uma vantagem desta técnica (Fatterpekar et al., 2008). Porém, ao mesmo tempo em que oferece uma excelente definição dos tecidos moles, a IRM fornece uma pobre definição dos tecidos ósseos, além do seu uso ser limitado pelos altos custos e dificuldade de acesso pelos pacientes (Rafferty et al., 2005; Saccucci et al., 2015).

A TC é capaz de visualizar detalhes anatômicos em tecidos moles e ósseos de estruturas nasais e paranasais em relação a estruturas vitais adjacentes, além de condições inflamatórias e patológicas (Cagici et al., 2015; Shahbazian e Jacobs, 2012). Não por menos, se tornou a modalidade imagem padrão ouro para avaliação dos seios da face, principalmente em casos de sinusite crônica (Poorey e Gupta, 2014; Aramani et al., 2014). No entanto, sua alta dose de radiação a impede de ser utilizada de maneira rotineira (Liang et al., 2010; Shahbazian e Jacobs, 2012; Zojaji et al., 2015). Já a TCFC possui alta resolução de imagem e baixa dose de radiação quando comparada a TC. Esta última vantagem talvez seja a mais importante quando se compara as duas modalidades de imagem, onde a TCFC pode se tornar um método valioso para a análise dos seios paranasais tanto na odontologia como na otorrinolaringologia, já que a TC dos seios da face ainda é o tipo de técnica mais solicitada dentro desta especialidade (Al Abduwani et al., 2016). Quando pacientes com sinusite crônica se submeteram a exames de TCFC e TC e a dose absorvida foi mensurada, a média para TCFC foi de 0,27 mSv, 40% menor que a TC protocolo padrão (0,48 mSv) e 30% menor que a TC protocolo para seios da face (0,39 mSv)

(Al Abduwani et al., 2016). Pois, com um correto posicionamento do paciente no aparelho de TCFC, um FOV de 10 X 10 cm é suficiente para exibir a cavidade nasal, seios paranasais e estruturas vitais adjacentes, havendo assim a possibilidade de se empregar protocolos de baixa dose (Bremke et al., 2009). Quando se levou em conta a qualidade de imagem entre os dois tipos de tomografia (Demeslay et al., 2015; Al Abduwani et al., 2016), a concordância entre os examinadores foi similar. Quando aplicada à cirurgia endoscópica sinusal, a TCFC apresentou resolução espacial e de contraste suficientes para o auxílio na navegação cirúrgica nas cavidades sinonasais (Mathew et al., 2013). Não obstante, devido a sua baixa resolução de contraste para tecidos moles, tem uso limitado para avaliação de infiltrações tumorais, sépticas ou hematológicas (Al Abduwani et al., 2016).

A partir dos itens abordados pela revisão de literatura, o segundo estudo foi desenvolvido com foco nos seios maxilares. Entre os seios paranasais, estes são os mais afetados por sinusites (Cagici et al., 2005; Poorey e Gupta, 2014). As sinusites são inflamações na mucosa do seio que ocorrem: (1) quando há um desequilíbrio entre a produção de muco e o movimento das células mucociliares, dificultando sua condução à cavidade nasal; (2) por danos às células mucociliares e/ou bloqueio da unidade óstio - infundíbulo etmoidal (Carmeli et al., 2011; Capelli e Gatti, 2016), que fazem parte do complexo óstio-meatal, sistema responsável pela drenagem dos seios paranasais (Tomomatsu et al., 2014). Nos seios maxilares, o muco secretado pelas células mucociliares é constantemente transferido para o óstio, passando pelo infundíbulo etmoidal até chegar à cavidade nasal. Como estas duas estruturas são fundamentais para o mecanismo de drenagem dos seios maxilares, eles foram mensurados, a fim de se avaliar se suas medidas influenciariam na presença ou ausência das alterações sinusais.

A remissão dos sintomas da sinusite é feita com terapia de suporte sintomático e caso o processo da doença progrida para uma infecção bacteriana, há a necessidade de antibioticoterapia (Kretzschmar e Kretzschmar, 2003). Se ainda assim, os tratamentos convencionais falharem, a intervenção cirúrgica para a abertura dos óstios é indicada (Carmeli et al., 2011), em que o tipo mais utilizado é a cirurgia endoscópica sinusal funcional, que melhora a depuração de muco pela cavidade nasal (Hathorn et al., 2014). Em estudo prévio, este tipo de abordagem foi considerado um fator significativo em casos de sinusites odontogênicas crônicas dos seios maxilares (Tomomatsu et al., 2014) em que o tratamento inicial com medicamentos foi falho. A

partir de algumas mensurações, os autores concluem que pacientes que apresentam uma abertura de óstio menor que 11,12 mm, em imagens de TC coronal, não há como se garantir que o tratamento inicial (extração ou tratamento endodôntico e antibioticoterapia) será eficiente e que provavelmente o paciente precisará de uma intervenção cirúrgica. É importante relatar que esse estudo realizou a mensuração dos óstios dos seios maxilares em imagens de TC de pacientes com sinusites de etiologia odontogênica, apesar do sistema de drenagem de sinusites odontogênicas e não odontogênicas acontecer da mesma forma. Em adição, esse mesmo estudo informa que mensurar o diâmetro dos óstios nos seios maxilares pela imagem de TC é difícil e que a TCFC seria um método mais fácil e preciso para avaliar estruturas dentro do complexo óstio-meatal. No nosso estudo, os avaliadores não relataram dificuldades em fazer as mensurações do diâmetro dos óstios dos seios maxilares e a TCFC foi uma modalidade de imagem eficaz para este fim.

Alguns autores (Bandyopadhyay et al., 2015; Lee et al., 2016) sustentam a hipótese que variações anatômicas presentes na cavidade nasal podem constituir fatores obstrutivos ao complexo óstio-meatal, como o desvio de septo, que é a alteração mais prevalente entre os indivíduos (Pérez-Piñas et al., 2000; Aramani et al., 2014; Kucybała et al., 2017). Esta variação se apresenta como uma curva assimétrica do septo nasal que pode comprimir a concha nasal média ipsilateralmente, estreitando o meato médio e infundíbulo etmoidal. O presente estudo também avaliou se o grau do desvio de septo influenciaria na presença ou ausência das sinusopatias e concluímos que esta variação anatômica não foi determinante para a presença das alterações sinusais. Outros estudos, ao analisar essa relação, concluíram que desvios de septo classificados como moderado a severo estão relacionados com as sinusopatias (Yasan et al., 2005; Carmeli et al., 2011; Mundra et al., 2014; Poorey et al., 2014; Karatas et al., 2015), afirmação que não pôde ser confirmada no presente estudo, pois a maioria dos pacientes que compunham a amostra foram classificados com desvio de septo leve.

A TCFC tem sido utilizada com sucesso para a análise tridimensional de certas estruturas anatômicas (Bui et al., 2015; Codari et al., 2015, Saccucci et al., 2015; Agacayak et al., 2015; Choi et al., 2017; Oz et al., 2017), permitindo a segmentação semiautomática e manual, com análise de forma e tamanho. Logo, com o intuito de extrair a vantagem desta tridimensionalidade, realizamos a segmentação manual do infundíbulo etmoidal, com o software ITK -SNAP. Devido a esta estrutura

anatômica também ser responsável pela drenagem do muco, juntamente com os óstios, volumes considerados pequenos poderiam estar relacionados com a ineficiência desta drenagem, por exemplo. Este fato não foi comprovado no nosso estudo.

O presente estudo destaca os potenciais usos da TCFC para a avaliação de estruturas nasais/paranasais e confirma que é um método adequado para este fim. Provavelmente tem potencial para ser padrão ouro na rotina da avaliação dos seios maxilares, pois combina boa qualidade de imagem, com baixa dose de exposição, menor tempo de escaneamento, fácil uso e custos reduzidos quando comparada com a TC e IRM. No entanto, a interpretação das imagens de TCFC requer familiaridade com a anatomia da área investigada, relações espaciais da imagem 3D, conhecimento de possíveis patologias e variações anatômicas que afetam a área maxilofacial, assim como competência na formulação de um diagnóstico diferencial. Requisitos estes que não podem ser ignorados. Além do mais, embora as técnicas de imagem tenham um papel fundamental no diagnóstico das variações anatômicas dos seios e da patologia sinusal, o exame clínico ainda representa uma ferramenta fundamental para o processo de diagnóstico do paciente.

Na população estudada, o presente estudo mostrou que o tamanho dos óstios dos seios maxilares está relacionado com a presença de algumas alterações sinusais e que o desvio de septo não está. Mais estudos poderiam ser desenvolvidos nessa linha, como por exemplo: avaliar imagens de pacientes diagnosticados com sinusite crônica e pacientes sem a doença, em que se realizaria a média de tamanho dos diâmetros dos óstios dos dois grupos. Assim, poderíamos saber efetivamente o tamanho médio dos óstios de pacientes com a doença. Em relação ao desvio de septo, seria avaliada uma amostra por conveniência de pacientes classificados com desvio de septo moderado à severo, para confirmar se realmente esse tipo de paciente apresentaria condições de desenvolver sinusopatias.

4 CONCLUSÃO

Nas condições do presente estudo, foi possível concluir que menores diâmetros látero-laterais dos óstios dos seios maxilares podem estar associados à presença de espessamento mucoso e pólipos, que septos desviados e infundíbulos etmoidais com volumes reduzidos não estão relacionados com alterações sinusais e que o sexo não influenciou nos parâmetros estudados. A TCFC é capaz de apresentar detalhes anatômicos do complexo ostiomeatal, sendo, portanto, recomendada como uma técnica de imagem adequada para avaliação dos seios maxilares.

REFERÊNCIAS*

Ahn J-C, Kim J-W, Lee CH, Rhee C-S. Prevalence and Risk Factors of Chronic Rhinosinusitis, Allergic Rhinitis, and Nasal Septal Deviation: Results of the Korean National Health and Nutrition Survey 2008-2012. *JAMA Otolaryngol. Head Neck Surg.* 2016;142(2):162–7.

Agacayak KS, Gulsun B, Koparal M, Atalay Y, Aksoy O, Adiguzel O. Alterations in maxillary sinus volume among oral and nasal breathers. *Med Sci Monit.* 2015 Jan 2;21:18–26.

Al Abduwani J, ZilinSkienne L, Colley S, Ahmed S. Cone beam CT paranasal sinuses versus standard multidetector and low dose multidetector CT studies. *Am J Otolaryngol.* 2016;37(1):59-64.

Angélico Junior FV, Rapoport PB. Analysis of the *Agger nasi* cell and frontal sinus ostium sizes using computed tomography of the paranasal sinuses. *Braz J Otorhinolaryngol.* 2013;79(3):285–92.

Aramani A, Karadi RN, Kumar S. A study of anatomical variations of osteomeatal complex in chronic rhinosinusitis patients-CT findings. *J Clin Diagnostic Res.* 2014; 8(10):KC01-KC04.

Ata-Ali J, Diago-Vilalta JV, Melo M, Bagán L, Soldini MC, Di-Nardo C, et al. What is the frequency of anatomical variations and pathological findings in maxillary sinuses among patients subjected to maxillofacial cone beam computed tomography? A systematic review. *Med Oral Patol Oral Cir Bucal.* 2017;22(4):e400–9.

Bandyopadhyay R, Biswas R, Bhattacharjee S, Pandit N, Ghosh S. Osteomeatal Complex: A Study of Its Anatomical Variation Among Patients Attending North Bengal Medical College and Hospital. *Indian J Otolaryngol Head Neck Surg.* 2015;67(3):281–6.

Bremke M, Sesterhenn AM, Murthum T, Al Hail A, Bien S, Werner JA. Digital volume tomography (DVT) as a diagnostic modality of the anterior skull base. *Acta Otolaryngol.* 2009 Oct;129(10):1106–14.

* De acordo com as normas da UNICAMP/FOP, baseadas na padronização do International Committee of Medical Journal Editors - Vancouver Group. Abreviatura dos periódicos em conformidade com o PubMed.

- Bui NL, Ong SH, Foong KWC. Automatic segmentation of the nasal cavity and paranasal sinuses from cone-beam CT images. *Int J Comput Assist Radiol Surg*. 2014;10(8):1269–77.
- Cagici CA, Cakmak O, Hurcan C, Tercan F. Three-slice computerized tomography for the diagnosis and follow-up of rhinosinusitis. *Eur Arch Otorhinolaryngol*. 2005;262(9):744–50.
- Cakli H, Cingi C, Ay Y, Oghan F, Ozer T, Kaya E. Use of cone beam computed tomography in otolaryngologic treatments. *Eur Arch Oto-Rhino-Laryngology*. 2012; 269(3):711–20.
- Campbell PD, Zinreich SJ, Aygun N. Imaging of the paranasal sinuses and in-office CT. *Otolaryngol Clin North Am*. 2009;42(5):753–64.
- Capelli M, Gatti P. Radiological study of maxillary sinus using CBCT: Relationship between mucosal thickening and common anatomic variants in chronic rhinosinusitis. *J Clin Diagnostic Res*. 2016;10(11):MC07-MC10.
- Carmeli G, Artzi Z, Kozlovsky A, Segev Y, Landsberg R. Antral computerized tomography pre-operative evaluation: Relationship between mucosal thickening and maxillary sinus function. *Clin Oral Implants Res*. 2011;22(1):78–82.
- Chan H-L, Wang H-L. Sinus pathology and anatomy in relation to complications in lateral window sinus augmentation. *Implant Dent*. 2011;20(6):406–12.
- Choi IGG, Duailibi-Neto EF, Beaini TL, da Silva RLB, Chilvarquer I. The Frontal Sinus Cavity Exhibits Sexual Dimorphism in 3D Cone-beam CT Images and can be Used for Sex Determination. *J Forensic Sci*. 2017;(11):1–7.
- Codari M, Zago M, Guidugli GA, Pucciarelli V, Tartaglia GM, Ottaviani F, et al. The nasal septum deviation index (NSDI) based on CBCT data. *Dentomaxillofacial Radiol*. 2015;45(2): 20150327.
- Daly MJ, Siewerdsen JH, Moseley DJ, Jaffray DA, Irish JC. Intraoperative cone-beam CT for guidance of head and neck surgery: Assessment of dose and image quality using a C-arm prototype. *Med Phys*. 2006 Oct;33(10):3767–80.
- Demeslay J, Vergez S, Serrano E, Chaynes P, Cantet P, Chaput B, et al. Morphological concordance between CBCT and MDCT: a paranasal sinus-imaging anatomical study. *Surg Radiol Anat*. 2015;38(1):71-8.

Eggesbø HB. Radiological imaging of inflammatory lesions in the nasal cavity and paranasal sinuses. *Eur Radiol.* 2006;16(4):872–88.

Fatterpekar GM, Delman BN, Som PM. Imaging the paranasal sinuses: Where we are and where we are going. *Anat Rec.* 2008;291(11):1564–72.

Göçmez C, Göya C, Hamidi C, Teke M, Hattapoğlu S, Kamaşak K. Evaluation of the surgical anatomy of sphenoid ostium with 3D computed tomography. *Surg Radiol Anat.* 2014;36(8):783–8.

Güldner C, Diogo I, Windfuhr J, Bien S, Teymoortash A, Werner J a, et al. Analysis of the fossa olfactoria using cone beam tomography (CBT). *Acta Otolaryngol.* 2011;131(1):72–8.

Gündoğdu E, Haksever M, Akduman D, Solmaz F. A cost-effective way of maxillary sinus ostium dilatation with Foley catheter in patients with chronic rhinosinusitis: MOD-F technique. *Int Forum Allergy Rhinol.* 2014;4(5):428–32.

Hathorn I, Habib AR, Santos RD, Javer A. The safety and performance of a maxillary sinus ostium self-dilation device: A pilot study. *Int Forum Allergy Rhinol.* 2014;4(8):625–31.

Hosemann W, Draf C. Danger points, complications and medico-legal aspects in endoscopic sinus surgery. *GMS Curr Top Otorhinolaryngol Head Neck Surg.* 2013;12.

Kapusuz Gencer Z, Ozkırış M, Okur A, Karaçavuş S, Saydam L. The effect of nasal septal deviation on maxillary sinus volumes and development of maxillary sinusitis. *Eur Arch Otorhinolaryngol.* 2013;270(12):3069–73.

Karataş D, Koç A, Yüksel F, Doğan M, Bayram A, Cihan MC. The Effect of Nasal Septal Deviation on Frontal and Maxillary Sinus Volumes and Development of Sinusitis. *J Craniofac Surg.* 2015;26(5):1508–12.

Khojastepour L, Haghnegahdar A, Khosravifard N. Role of Sinonasal Anatomic Variations in the Development of Maxillary Sinusitis: A Cone Beam CT Analysis. *Open Dent J.* 2017 Jun 30;11:367-74.

Kretschmar DP, Kretschmar CJL. Rhinosinusitis: Review from a dental perspective. *Oral Surg Oral Med Oral Pathol Oral Radiol Endod.* 2003;96(2):128–35.

Kucybała I, Janik KA, Ciuk S, Storman D, Urbanik A. Nasal septal deviation and concha

bullosa - Do they have an impact on maxillary sinus volumes and prevalence of maxillary sinusitis? *Polish J Radiol.* 2017;82:126–33.

Lee JW, Yoo JY, Paek SJ, Park W-J, Choi EJ, Choi M-G, et al. Correlations between anatomic variations of maxillary sinus ostium and postoperative complication after sinus lifting. *J Korean Assoc Oral Maxillofac Surg.* 2016;42(5):278–83.

Liang X, Jacobs R, Hassan B, Li L, Pauwels R, Corpas L, et al. A comparative evaluation of cone beam computed tomography (CBCT) and multi-slice CT (MSCT) Part I. On subjective image quality. *Eur J Radiol.* 2010;75(2):265–9.

Linsenmaier U, Rock C, Euler E, Wirth S, Brandl R, Kotsianos D, et al. Three-dimensional CT with a modified C-arm image intensifier: feasibility. *Radiology.* 2002;224(1):286–92.

Maillet M, Bowles WR, McClanahan SL, John MT, Ahmad M. Cone-beam computed tomography evaluation of maxillary sinusitis. *J Endod.* 2011;37(6):753–7.

Masri AA, Yusof A, Hassan R. A Three Dimensional Computed Tomography (3D-CT): A Study of Maxillary Sinus in Malays. *Can J Basic Appl Sci.* 2013;1(2):125–34.

Mathew R, Omami G, Hand A, Fellows D, Lurie A. Cone beam CT analysis of Haller cells: Prevalence and clinical significance. *Dentomaxillofacial Radiol.* 2013;42(9).

Mladina R, Cujčić E, Subarić M, Vuković K. Nasal septal deformities in ear, nose, and throat patients: an international study. *Am J Otolaryngol.* 2008;29(2):75–82.

Mundra RK, Gupta Y, Sinha R, Gupta A. CT Scan Study of Influence of Septal Angle Deviation on Lateral Nasal Wall in Patients of Chronic Rhinosinusitis. *Indian J Otolaryngol Head Neck Surg.* 2014;66(2):187–90.

Nascimento EH, Pontual ML, Pontual AA, Freitas DQ, Perez DE, Ramos-Perez FM. Association between Odontogenic Conditions and Maxillary Sinus Disease: A Study Using Cone-beam Computed Tomography. *J Endod.* 2016;42(10):1509–15.

Okşayan R, Sökücü O, Yeşildal S. Evaluation of maxillary sinus volume and dimensions in different vertical face growth patterns: a study of cone-beam computed tomography. *Acta Odontol Scand.* 2017;75(5):345–9.

Oz AZ, Oz AA, El H, Palomo JM. Maxillary sinus volume in patients with impacted canines. *Angle Orthod.* 2017;87(1):25–32.

Parks ET. Cone beam computed tomography for the nasal cavity and paranasal sinuses. *Dent Clin North Am.* 2014;58(3):627–51.

Pérez-Piñas, Sabaté J, Carmona A, Catalina-Herrera CJ, Jiménez-Castellanos J. Anatomical variations in the human paranasal sinus region studied by CT. *J Anat.* 2000;197(Pt 2): 221–7.

Pilan RR, Pinna FR, Bezerra TF, Mori RL, Padua FG, Bento RF, et al. Prevalence of chronic rhinosinusitis in Sao Paulo. *Rhinology.* 2012;50(2):129–38.

Poorey VK, Gupta N. Endoscopic and computed tomographic evaluation of influence of nasal septal deviation on lateral wall of nose and its relation to sinus diseases. *Indian J Otolaryngol Head Neck Surg.* 2014;66(3):330–5.

Prisman E, Daly MJ, Chan H, Siewerdsen JH, Vescan A, Irish JC. Real-time tracking and virtual endoscopy in cone-beam CT-guided surgery of the sinuses and skull base in a cadaver model. *Int Forum Allergy Rhinol.* 2011;1(1):70–7.

Rafferty MA, Siewerdsen JH, Chan Y, Moseley DJ, Daly MJ, Jaffray DA, et al. Investigation of C-arm cone-beam CT-guided surgery of the frontal recess. *Laryngoscope.* 2005;115(12):2138–43.

Rak KM, Newell JD, Yakes WF, Damiano MA, Luethke JM. Paranasal sinuses on MR images of the brain: Significance of mucosal thickening. *Am J Roentgenol.* 1991;156(2):381–4.

Rao VM, el-Noueam KI. Sinonasal imaging: Anatomy and pathology. *Radiol Clin North Am.* 1998;36(5):921–39.

Rege IC, Sousa T, Leles C, Mendonça E. Occurrence of maxillary sinus abnormalities detected by cone beam CT in asymptomatic patients. *BMC Oral Health.* 2012;12(1):30.

Ritter L, Lutz J, Neugebauer J, Scheer M, Dreiseidler T, Zinser MJ, et al. Prevalence of pathologic findings in the maxillary sinus in cone-beam computerized tomography. *Oral Surg Oral Med Oral Pathol Oral Radiol Endod.* Elsevier. 2011;111(5):634–40.

Saccucci M, Carderi S, Carlo GDI, Polimeni A, Rodolfo D. Gender assessment through three-dimensional analysis of maxillary sinuses by means of Cone Beam Computed Tomography. *Eur Rev Med Pharmacol Sci.* 2015;185–93.

Serifoglu I, Oz İİ, Damar M, Buyukuysal MC, Tosun A, Tokgöz Ö. Relationship between

the degree and direction of nasal septum deviation and nasal bone morphology. *Head Face Med.* 2017;13(1):3.

Shahbazian M, Jacobs R. Diagnostic value of 2D and 3D imaging in odontogenic maxillary sinusitis: A review of literature. *J Oral Rehabil.* 2012;39(4):294–300.

Shahidi S, Zamiri B, Momeni Danaei S, Salehi S, Hamedani S. Evaluation of Anatomic Variations in Maxillary Sinus with the Aid of Cone Beam Computed Tomography (CBCT) in a Population in South of Iran. *J Dent.* 2016 Mar;17(1):7–15.

Shanbhag S, Karnik P, Shirke P, Shanbhag V. Cone-beam computed tomographic analysis of sinus membrane thickness, ostium patency, and residual ridge heights in the posterior maxilla: Implications for sinus floor elevation. *Clin Oral Implants Res.* 2014 Jun;25(6):755-60.

Smith KD, Edwards PC, Saini TS, Norton NS. The prevalence of concha bullosa and nasal septal deviation and their relationship to maxillary sinusitis by volumetric tomography. *Int J Dent.* 2010;2010:0–4.

Šubarić M, Mladina R. Nasal septum deformities in children and adolescents: A cross sectional study of children from Zagreb, Croatia. *Int J Pediatr Otorhinolaryngol.* 2002;63(1):41–8.

Tomomatsu N, Uzawa N, Aragaki T, Harada K. Aperture width of the osteomeatal complex as a predictor of successful treatment of odontogenic maxillary sinusitis. *Int J Oral Maxillofac Surg.* 2014;43(11):1386–90.

Toskala E, Rautiainen M. Effects of surgery on the function of maxillary sinus mucosa. *Eur Arch Oto-Rhino-Laryngology.* 2005;262(3):236–40.

Vallo J, Suominen-Taipale L, Huumonen S, Soikkonen K, Norblad A. Prevalence of mucosal abnormalities of the maxillary sinus and their relationship to dental disease in panoramic radiography: results from the Health 2000 Health Examination Survey. *Oral Surgery Oral Med Oral Pathol Oral Radiol Endodontology.* 2010;109(3):e80–7.

Yasan H, Dogru H, Baykal B, Doner F, Tuz M. What is the relationship between chronic sinus disease and isolated nasal septal deviation? *Otolaryngol Head Neck Surg.* 2005;133(2):190–3.

Yushkevich P a., Piven J, Hazlett HC, Smith RG, Ho S, Gee JC, et al. User-guided 3D active contour segmentation of anatomical structures: Significantly improved efficiency

and reliability. *Neuroimage*. 2006;31(3):1116–28.

Zojaji R, Naghibzadeh M, Mazloun Farsi Baf M, Nekooei S, Bataghva B, Noorbakhsh S. Diagnostic accuracy of cone-beam computed tomography in the evaluation of chronic rhinosinusitis. *Orl J Otorhinolaryngol Relat Spec*. 2015;77(1):55–60.

APÊNDICE 1 – Detalhamento da metodologia

O presente estudo foi aprovado pelo Comitê de Ética em Pesquisa da Faculdade de Odontologia de Piracicaba, da Universidade Estadual de Campinas – FOP/UNICAMP - protocolo nº 149/2015.

SELEÇÃO DA AMOSTRA

A partir de uma análise retrospectiva da base de dados do Departamento de Diagnóstico Oral/Área Radiologia odontológica da FOP/UNICAMP, com exames realizados entre 2009 e 2015, imagens de pacientes menores de 18 anos, com destruição do septo nasal e/ou seio maxilar devido a algum tipo de condição patológica severa (tumor) ou trauma, que não permitiam a visualização completa do seio maxilar, óstio e infundíbulo etmoidal correspondentes foram excluídas. A partir disto, o pesquisador radiologista responsável, incluiu 240 imagens de Tomografia Computadorizada de Feixe Cônico - TCFC de pacientes com indicação clínica prévia diversa a do presente estudo, em 2 grupos: grupo sem alteração sinusal (60 homens e 60 mulheres) e grupo com alteração sinusal (60 homens e 60 mulheres). As idades variaram entre 18 e 82 anos ($34,7 \pm 15,7$). Nenhuma informação a respeito da raça estava disponível. A alteração sinusal foi considerada, quando o paciente apresentava uma espessura de mucosa superior a 5 mm (Carmeli et al. 2011; Maillet et al. 2011; Shanbhag et al. 2013), medida no ponto de maior espessamento, perpendicular ao osso subjacente (Shanbhag et al. 2013) (Figura 1).

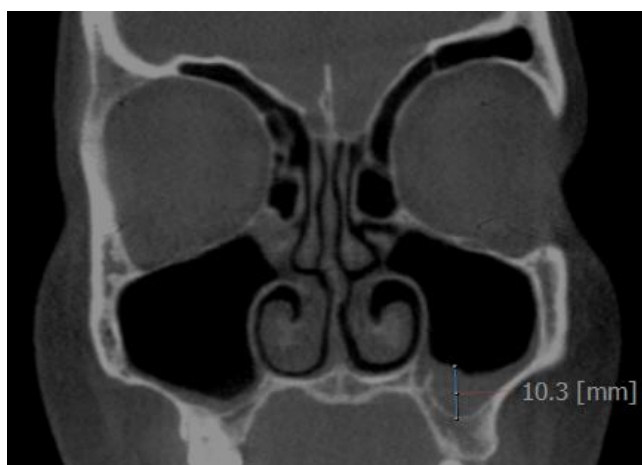


Figura 1 - Mensuração da espessura da mucosa

AQUISIÇÃO E AVALIAÇÃO DAS IMAGENS

As imagens de TCFC foram obtidas usando o aparelho i-CAT® 3D Imaging System (Imaging Sciences International, Hatfield, PA, USA), com os seguintes parâmetros: 7mA; 120 kVp; tamanho de *voxel* 200 µm; tempo de aquisição de 40s e *Field of View* (FOV) de 23 X 17cm. As imagens foram selecionadas neste FOV por permitirem a visualização desde a crista galli até a espinha nasal anterior, na reconstrução coronal, possibilitando a mensuração das angulações dos septos.

Dois examinadores especialistas em Radiologia Odontológica, previamente treinados e com experiência de pelo menos 5 anos em imagens tomográficas, analisaram a angulação do septo, o diâmetro dos óstios dos seios maxilares, a condição da mucosa sinusal e o volume do infundíbulo etmoidal. Mensurações lineares, angulares e volumétricas foram realizadas nos softwares OnDemand3D™ (Cybermed, Tustin, CA) e ITK – SNAP (Penn Image Computing and Science Laboratory, Philadelphia, PA), respectivamente, em um monitor Barco (MDRC-2124, Barco N.V., Courtray, Bélgica).

OnDemand3D™:

Para a mensuração da angulação do septo, os avaliadores utilizaram a reconstrução coronal e traçaram uma linha da crista galli até a espinha nasal anterior e outra linha da crista galli passando pelo ponto de maior curvatura do septo nasal (Figura 2). Em casos de desvio, o avaliador indicava para qual lado ocorria: direito ou esquerdo. A angulação ainda deveria ser classificada em: sem desvio (0°), leve (<9°), moderada (entre 9° e 15°) ou severa (15° ou mais) (Gencer et al., 2013; Orhan et al., 2014; Karatas et al., 2015).

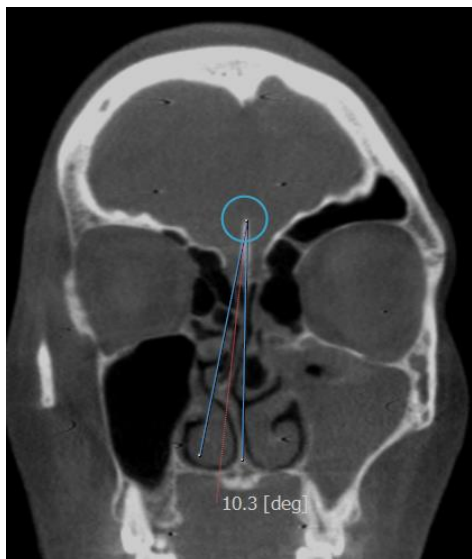


Figura 2- Mensuração do desvio de septo

Para a mensuração do diâmetro dos óstios ainda na reconstrução coronal, foram traçadas linhas de orientação: uma no longo eixo do infundíbulo etmoidal e outra perpendicular à entrada do óstio (Figura 3). Assim, foi possível localizar, delimitar e mensurar o diâmetro ântero-posterior e látero-lateral dos óstios corrigidos de acordo com o longo eixo do infundíbulo etmoidal, na reconstrução axial (Figura 4).

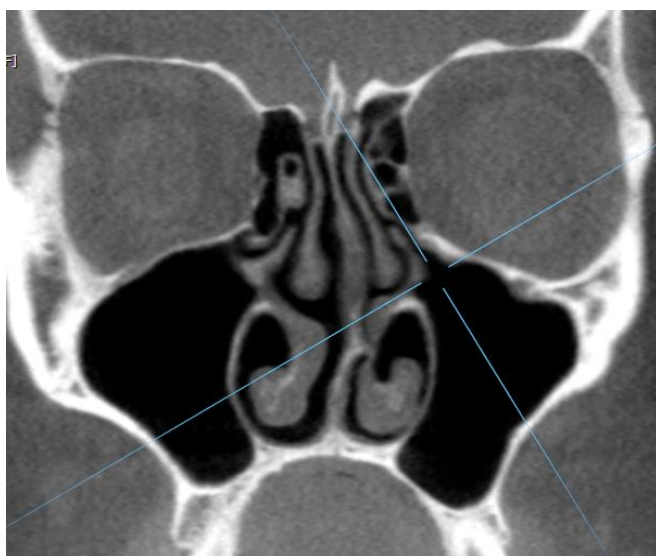


Figura 3 - Marcação das linhas de orientação

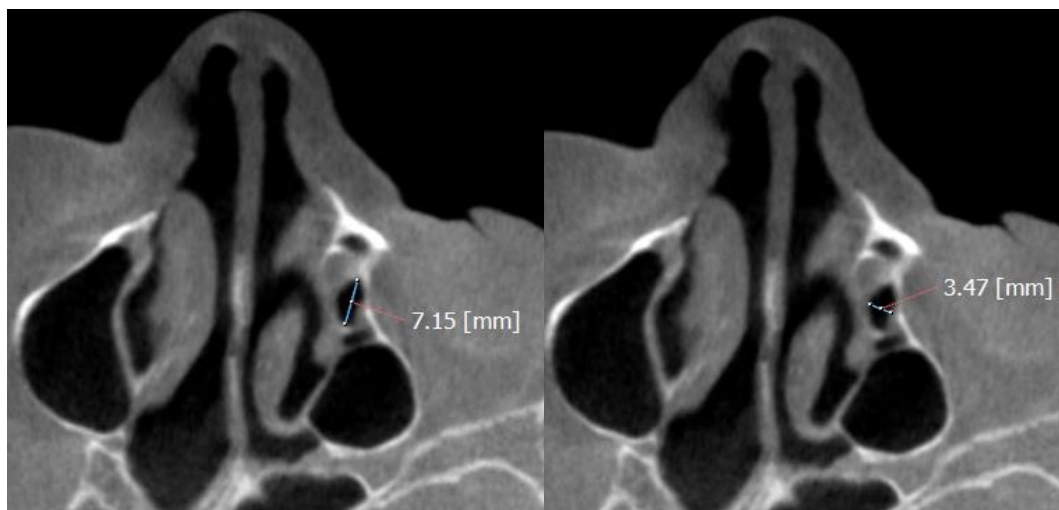


Figura 4 - Mensuração do diâmetro ântero-posterior e látero-lateral do óstio, corrigidos de acordo com o longo eixo do infundíbulo etmoidal, respectivamente.

A condição da mucosa sinusal foi classificada como normal, espessada, presença de pólipos mucosos, opacificação parcial e opacificação total (Figura 5).

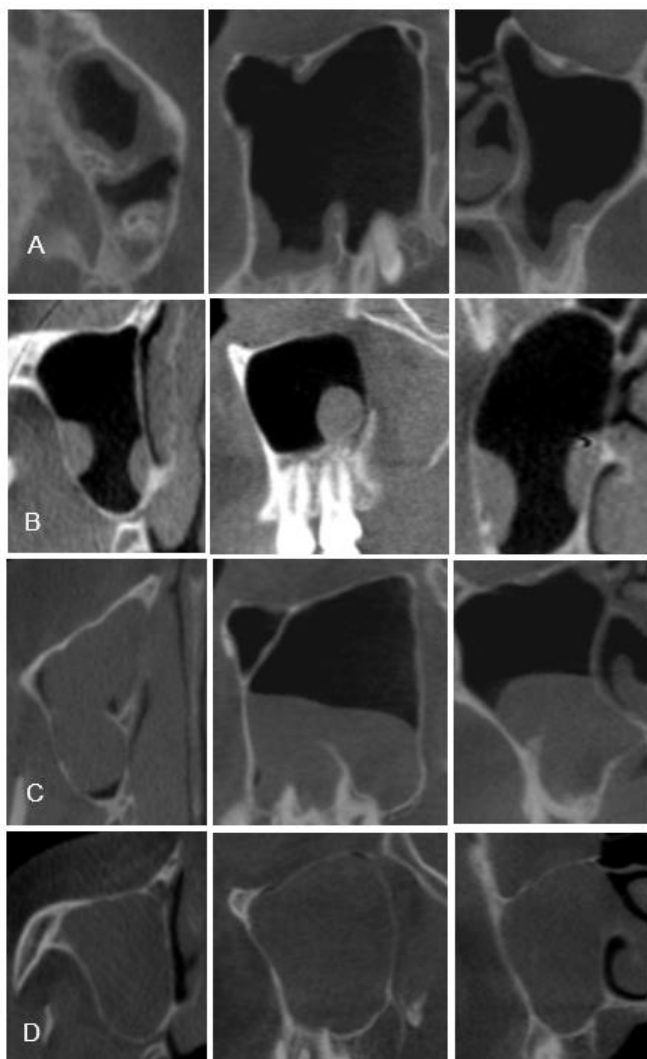


Figura 5 - Classificação da aparência da alteração sinusal: A – Espessamento mucoso; B – Pólipo mucoso; C e D– Opacificação (parcial e total).

ITK-SNAP

Para análise de volume do infundíbulo etmoidal, foram construídas imagens tridimensionais, geradas por reconstruções multiplanares, pelas ferramentas do software ITK-SNAP (Cognitica, Philadelphia, Pa, EUA). A reconstrução do modelo 3D foi realizada com o modo de segmentação manual do software, corte por corte, desde o ponto de maior constrição na entrada do infundíbulo e na saída deste, até os limites visíveis da estrutura, quando ela se comunica com o complexo ostiomeatal (Figura 6).

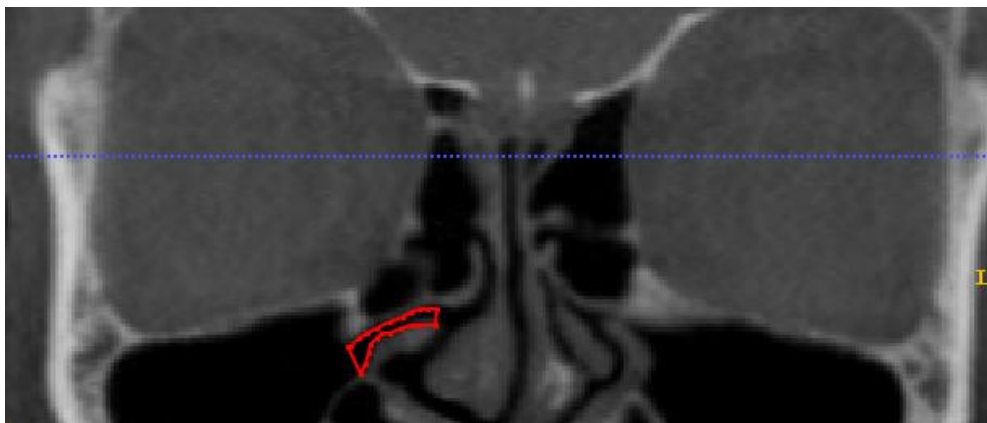

Figura 6 - Segmentação manual do infundíbulo etmoidal

Após finalizada a segmentação, a imagem do volume do infundíbulo etmoidal foi reconstruída na janela 3D do software (Figura 7). O volume da estrutura foi mensurado pelo próprio software em mm^3 .

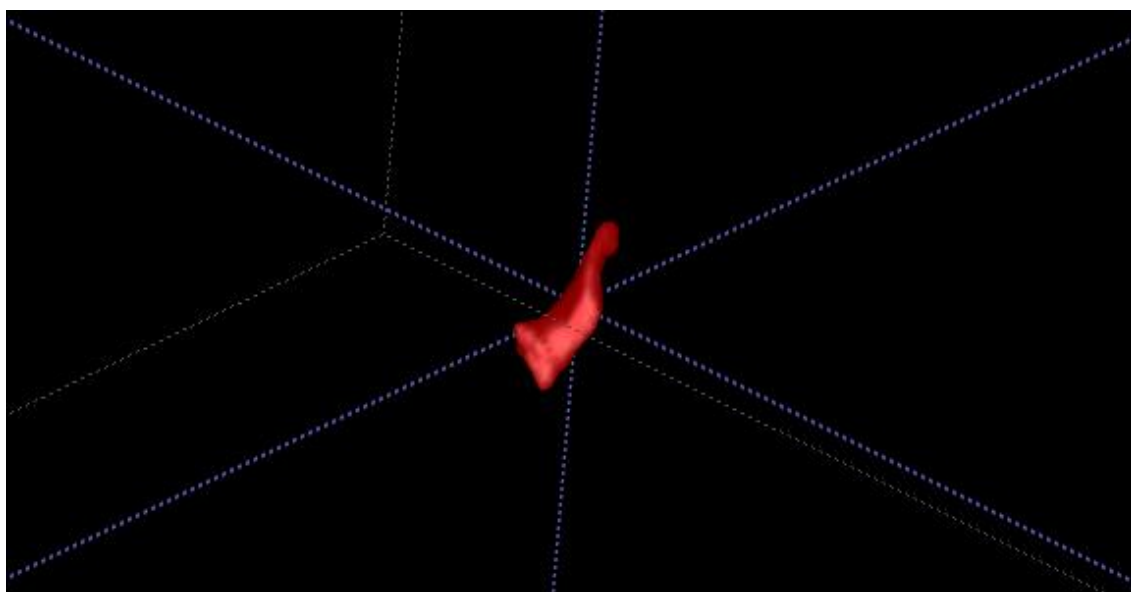


Figura 7 - Volume do infundíbulo etmoidal

Análise estatística

Os dados foram submetidos ao teste Kappa para a avaliação da concordância interavaliador em relação a: classificação da angulação do septo, e alteração sinusal. A concordância interavaliadores relativa ao diâmetro ântero-posterior e látero-lateral do óstio, angulação do desvio de septo e volume do infundíbulo etmoidal foi analisada pelo Coeficiente de Correlação Intraclassa (ICC). Os dados foram submetidos à análise estatística em que o teste Mann – Whitney foi utilizado para analisar a influência do sexo nas variáveis do estudo, o teste de Kruskal-

Wallis foi aplicado para verificar a existência de relação entre ausência/presença de alterações sinusais e as variáveis. O nível de significância considerado foi de 5% para todos os testes e os softwares utilizados foram o BioEstat 5.0 e o GraphPad Prism 7.0.

ANEXO 1 – Documentos para fins de comprovação de submissão do artigo

Liana Ferreira:

Thank you for submitting the manuscript, "THE FUNDAMENTS OF CBCT AND ITS USE FOR EVALUATION OF PARANASAL SINUSES: REVIEW OF LITERATURE" to Brazilian Journal of Oral Sciences. With the online journal management system that we are using, you will be able to track its progress through the editorial process by logging in to the journal web site:

Submission URL: <http://www.fop.unicamp.br/bjos/index.php/bjos/authorDashboard/submission/38>

Username: `

If you have any questions, please contact me. Thank you for considering this journal as a venue for your work.

Altair Antoninha Del Bel Cury

BRAZILIAN JOURNAL OF ORAL SCIENCES

A/C Altair Del Bel Cury, Editor-in-Chief

[Avenida Limeira, 901](#)

CEP: 13.414-903 – Piracicaba, SP - Brasil

Phone: [+55 \(19\) 2106-5706](tel:+55(19)2106-5706)

Fax: [+55 \(19\) 2106-5218](tel:+55(19)2106-5218)

E-mail: brjorals@fop.unicamp.br

Website: <http://www.fop.unicamp.br/bjos>

Dear Liana Ferreira,

You are receiving this e-mail as you are listed as the corresponding author or as a co-author on the submission entitled "Relation of linear and volumetric measurements of nasal structures with sinus mucosal changes", which has been received by Dentomaxillofacial Radiology.

You will be able to check on the progress of your paper by logging on to Editorial Manager as an Author at <https://dmfr.editorialmanager.com/>.

Username:

If you already know your password, please login with it. If you have just been registered, or you have forgotten your password, please activate the following link to create a password: <https://dmfr.editorialmanager.com/l.asp?i=31211&l=VHUAKSDC>. If you cannot activate the above password link please go to "<https://dmfr.editorialmanager.com/>", click "login" then click "Send login details" or please notify me by replying directly to this email.

You will be informed by email of the manuscript reference number in due course.

If you do not think you should be listed as an author of this work, please get in touch with the editor (rschulze@uni-mainz.de)

Thank you for submitting your work to DMFR.

Kind regards,
DMFR Office

ANEXO 2 – Certificado do Comitê de Ética em Pesquisa



COMITÊ DE ÉTICA EM PESQUISA
FACULDADE DE ODONTOLOGIA DE PIRACICABA
UNIVERSIDADE ESTADUAL DE CAMPINAS



CERTIFICADO

O Comitê de Ética em Pesquisa da FOP-UNICAMP certifica que o projeto de pesquisa "Avaliação dos óstios dos seios frontal, maxilar e esfenoidal utilizando Tomografia computadorizada de feixe cônico", protocolo CAAE nº 51430115.5.0000.5418, dos pesquisadores Liana Matos Ferreira, Francisco Haiter Neto, Cíntia Pereira Machado Tabchoury, Francisco Carlos Groppo, Danieli Moura Brasil e Yuri Nejaim, satisfaz as exigências do Conselho Nacional de Saúde – Ministério da Saúde para as pesquisas em seres humanos e foi aprovado por este comitê em 20 de Outubro de 2017.

The Ethics Committee in Research of the Piracicaba Dental School, University of Campinas, certify that the project "Evaluation of the ostia of the frontal, maxillary and sphenoid sinus using Cone Beam Computed Tomography", CAAE 51430115.5.0000.5418, of Liana Matos Ferreira, Francisco Haiter Neto, Cíntia Pereira Machado Tabchoury, Francisco Carlos Groppo, Danieli Moura Brasil and Yuri Nejaim, comply with the recommendations of the National Health Council – Ministry of Health of Brazil for research in human subjects and therefore was approved by this committee on October, 20 2017.

Profa. Fernanda Miori Pascon

Vice Coordenador
 CEP/FOP/UNICAMP

Prof. Jacks Jorge Junior

Coordenador
 CEP/FOP/UNICAMP

Nota: O título do protocolo e a lista de autores aparece como fornecidos pelos pesquisadores, sem qualquer edição.
 Notice: The title and the list of researchers of the project appears as provided by the authors, without editing.